

# Reconstructive Techniques in Musculoskeletal Tumor Surgery

*Management of Pelvic and Extremity Bone Tumors*



Michaël P.A. Bus



# **Reconstructive Techniques in Musculoskeletal Tumor Surgery**

–

*Management of Pelvic and Extremity Bone Tumors*

Michaël P.A. Bus

## **Reconstructive Techniques in Musculoskeletal Tumor Surgery – Management of Pelvic and Extremity Bone Tumors**

PhD thesis, Leiden University, Leiden, the Netherlands

Copyright © 2018 M.P.A. Bus, Amsterdam, the Netherlands

All rights reserved. No parts of this thesis may be reproduced, stored in a retrieval system of any nature or by any means, without prior written consent of the author. The copyright of the articles that have been published has been transferred to the respective journals.

<b>ISBN/EAN</b>	978-94-6332-316-1
<b>Cover design</b>	Jeroen Luijt Photography ( <a href="http://jeroenluijt.nl">jeroenluijt.nl</a> ), Amsterdam, the Netherlands
<b>Lay-out</b>	Ferdinand van Nispen tot Pannerden, Citroenvlinder DTP & Vormgeving, <a href="http://my-thesis.nl">my-thesis.nl</a>
<b>Printing</b>	GVO Drukkers & Vormgevers B.V., Ede, the Netherlands

**The research projects in this thesis were supported by an unconditional research grant from implantcast GmbH, Buxtehude, Germany.**

Publication of this thesis was kindly supported by: Nederlandse Orthopaedische Vereniging (NOV), Universiteit Leiden, implantcast Benelux, Bislife Foundation, ChipSoft and Anna Fonds|NOREF.

# **Reconstructive Techniques in Musculoskeletal Tumor Surgery**

*Management of Pelvic and Extremity Bone Tumors*

Proefschrift

ter verkrijging van  
de graad van Doctor aan de Universiteit Leiden  
op gezag van Rector Magnificus prof. mr. C.J.J.M. Stolker  
volgens besluit van het College voor Promoties  
te verdedigen op donderdag 12 april 2018  
klokke 16:15 uur

door

Michaël Peter Alexander Bus

geboren te Naarden  
in 1988

**Promotores**

Prof. dr. P.D.S. Dijkstra

Prof. dr. R.G.H.H. Nelissen

**Co-promotor**

Dr. J.A.M. Bramer

*Academisch Medisch Centrum, Amsterdam*

**Leden promotiecommissie**

Prof. dr. J.V.M.G. Bovee

Prof. dr. D.A. Campanacci      *Azienda Ospedaliero-Universitaria Careggi, Florence, Italië*

Dr. M.A.J. van de Sande

Prof. dr. H.W.B. Schreuder      *Radboud Universitair Medisch Centrum, Nijmegen*

Prof. dr. ir. A.A. Zadpoor      *Technische Universiteit Delft, Delft*

*"Some of my operations are great triumphs and tremendous.*

*But they're only triumphs because there are also disasters"*

Henry Marsh (Do No Harm, 2014)

# Contents

Chapter 1	<b>General introduction</b>	9
<b>Part I</b>	<b>Management of Pelvic Bone Tumors</b>	29
Chapter 2	<b>Conventional primary central chondrosarcoma of the pelvis: prognostic factors and outcome of surgical treatment in 162 patients</b> MPA Bus, DA Campanacci, JI Albergo, A Leithner, MAJ van de Sande, LC Gaston, G Caff, J Mettelsiefen, R Capanna, PU Tunn, LM Jeys, PDS Dijkstra <i>Accepted for publication (J Bone Joint Surg Am).</i>	31
Chapter 3	<b>Clinical outcome of pedestal cup endoprosthetic reconstruction after resection of a periacetabular tumor</b> MPA Bus, EJ Boerhout, JAM Bramer, PDS Dijkstra <i>Bone Joint J 2014;96-B:1706-12.</i>	53
Chapter 4	<b>LUMiC® endoprosthetic reconstruction after periacetabular tumor resection: short-term results</b> MPA Bus, A Szafranski, S Sellevold, T Goryn, PC Jutte, JAM Bramer, M Fiocco, A Streitbürger, D Kotrych, MAJ van de Sande, PDS Dijkstra <i>Clin Orthop Relat Res 2017 Mar; 475(3): 686–695.</i>	69
<b>Part II</b>	<b>Management of Extremity Bone Tumors</b>	91
Chapter 5	<b>Intercalary allograft reconstructions following resection of primary bone tumors: a nationwide multicenter study</b> MPA Bus, PDS Dijkstra, MAJ van de Sande, AHM Taminiau, HWB Schreuder, PC Jutte, ICM van der Geest, GR Schaap, JAM Bramer <i>J Bone Joint Surg Am 2014;96:e26(1-11).</i>	<u>93</u>



Chapter 6	<b>Hemicortical resection and inlay allograft reconstruction for primary bone tumors: a retrospective evaluation in the Netherlands and review of the literature</b> MPA Bus, JAM Bramer, GR Schaap, HWB Schreuder, PC Jutte, ICM van der Geest, MAJ van de Sande, PDS Dijkstra <i>J Bone Joint Surg Am</i> 2015;97:738-50.	115
Chapter 7	<b>Is there still a role for osteoarticular allograft reconstruction in musculoskeletal tumor surgery? A long-term follow-up study of 38 patients and systematic review of the literature</b> MPA Bus, MAJ van de Sande, AHM Taminiau, PDS Dijkstra <i>Bone Joint J</i> 2017;99-B:522–30.	137
Chapter 8	<b>Factors affecting nonunion of allograft-host junctions in intercalary reconstructions of the femur and tibia</b> MPA Bus, JI Albergo, MAJ van de Sande, GL Farfalli, LE Ritacco, LA Aponte-Tinao, PDS Dijkstra <i>Accepted for publication (Int Orthop)</i> .	163
Chapter 9	<b>What are the long-term results of MUTARS® modular endoprostheses for reconstruction of tumor resection of the distal femur and proximal tibia?</b> MPA Bus, MAJ van de Sande, M Fiocco, GR Schaap, JAM Bramer, PDS Dijkstra <i>Clin Orthop Relat Res.</i> 2017 Mar; 475(3): 708–718.	179
Chapter 10	<b>General summary</b>	201
Chapter 11	<b>General discussion</b>	209
Chapter 12	<b>Summary in Dutch (Nederlandstalige samenvatting)</b>	237
Appendices		245
	List of publications	246
	Acknowledgements	248
	Curriculum vitae	250



# Chapter 1

## **General Introduction**

## General Introduction

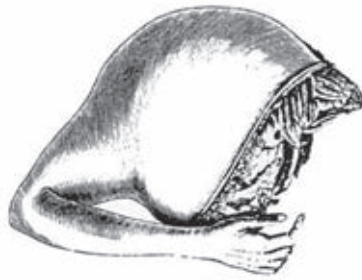### Historical Background & Aim of the Thesis

Primary bone tumors are rare, accounting for only 0.2% of the total human tumor burden<sup>1</sup>. In 1879, Samuel Weissel Gross published what was later referred to as the “first comprehensive work on bone sarcoma”<sup>2, 3</sup>. In this landmark paper, he advocated early amputation for high-grade sarcoma of bone and soft tissues, despite an overall operative mortality of 30%. Amputations at that time were also frequently performed to control local tumor growth, for palliation, because sarcomas often grew to enormous sizes before diagnosis<sup>4</sup> (figures 1 and 2).



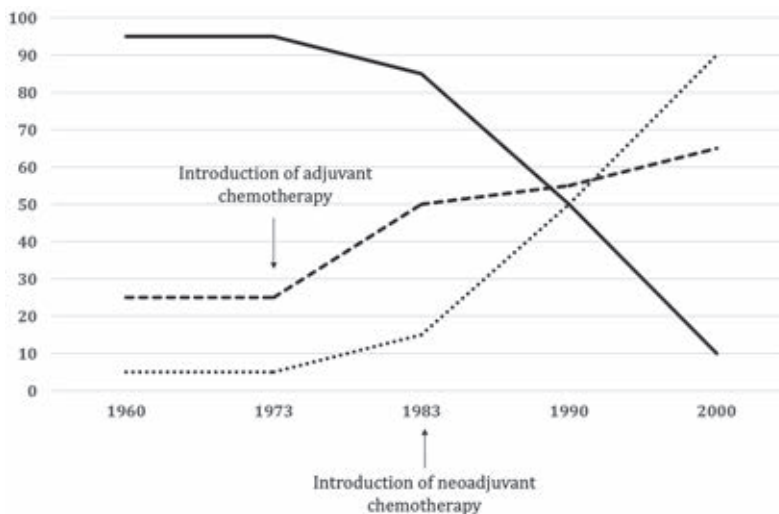
**Figure 1:** A tumor of the humerus in a 16-year-old woman, four years after onset (from William Gibson, *The Institutes and Practice of Surgery* [Philadelphia: Carey & Lea, 1832], volume 1, facing page 248.)

Amputation long remained the principal treatment for bone sarcoma<sup>5</sup>. In 1940, Dallas Burton Phemister noted that “the proper treatment of bone sarcomas of the limbs without demonstrable metastases in the great majority of cases is amputation”<sup>6</sup>. Despite the aggressive and mutilating surgical approach at that time, the 1938 statistics of the Registry of Bone Sarcoma of the American College of Surgeons showed a mere 13% recurrence-free survival at a minimum follow-up of five years in patients with osteosarcoma<sup>6</sup>.



**Figure 2:** Specimen of a forequarter amputation carried out by George McClellan in 1838 (from George McClellan, *Principles and Practice of Surgery* [Philadelphia: Grigg & Elliot, 1848], page 412, figure 15).

During the late 19<sup>th</sup> and early 20<sup>th</sup> centuries, the first incidental reports on limb-salvaging procedures were published<sup>7-10</sup>. The advent of effective chemotherapeutic agents in the early 1970s caused an increase of five-year survival rates to approximately 55% to 70% for many types of primary sarcoma<sup>11-19</sup>. Concomitant sophistication of imaging and surgical techniques reduced the need for ablative procedures. Limb-salvage surgery was soon popularized and is now the treatment of choice for over 90% of patients with a primary malignant bone tumor<sup>5, 20-25</sup> (figure 3).



**Figure 3:** Graph illustrating the trends in the percentages of amputations, limb-salvage procedures, and survival for patients with primary bone sarcomas (solid line, amputations; round dot line, limb salvage procedures; square dot line, survival).

If applicable for the type of tumor, patients are first treated with neoadjuvant chemotherapy and/or radiotherapy. The subsequent limb-salvaging surgical procedure consists of three phases: (1) tumor resection, usually with the aim to obtain clear surgical margins, (2) skeletal reconstruction, and (3) soft tissue reconstruction<sup>25, 26</sup>. The techniques of reconstruction vary and are dictated by surgeon preferences, tumor localization, extent of the defect, and the availability of implants. A large variety of techniques are employed at present, each having its specific advantages and disadvantages; unfortunately, these large reconstructions do not come without complications. Many techniques have not been reviewed properly and therefore, it is difficult to make an evidence-based decision when having to choose the optimal reconstructive technique for the individual patient. Reasons for the paucity of solid evidence include the low incidence of primary musculoskeletal tumors, the heterogeneity in presentation, and significant loss to follow-up due to mortality, as a result of metastases.

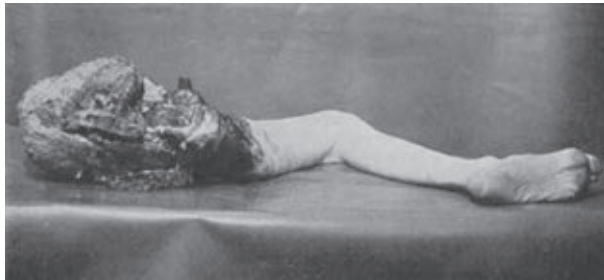The aim of this thesis is to evaluate the outcomes of different reconstructive techniques in treatment of pelvic and extremity bone tumors, to identify risk factors for impaired clinical outcome, and ultimately to improve outcomes for patients with musculoskeletal tumors.

## **Part I: Management of Pelvic Bone Tumors**

Pelvic bone tumors include primary malignancies and metastatic tumors<sup>27</sup>. The most common primary tumors of pelvic bone are central and peripheral chondrosarcomas, myeloma, Ewing's sarcoma and, to a lesser extent, osteosarcoma<sup>1, 14, 15, 28-30</sup>. The traditional treatment for malignant tumors of pelvic bone is hindquarter amputation<sup>21, 31-33</sup>. The term hindquarter amputation (or external hemipelvectomy) is used to designate the complete removal of the lower extremity, the corresponding buttock, and the entire innominate bone in one stage<sup>34, 35</sup> (figure 4). In 1959, Gordon-Taylor reported on his experiences with hindquarter amputations in a series of 41 patients<sup>36</sup>. He noted perioperative mortality in 25 patients (61%), and described the procedure as "one of the most colossal mutilations practiced on the human frame".

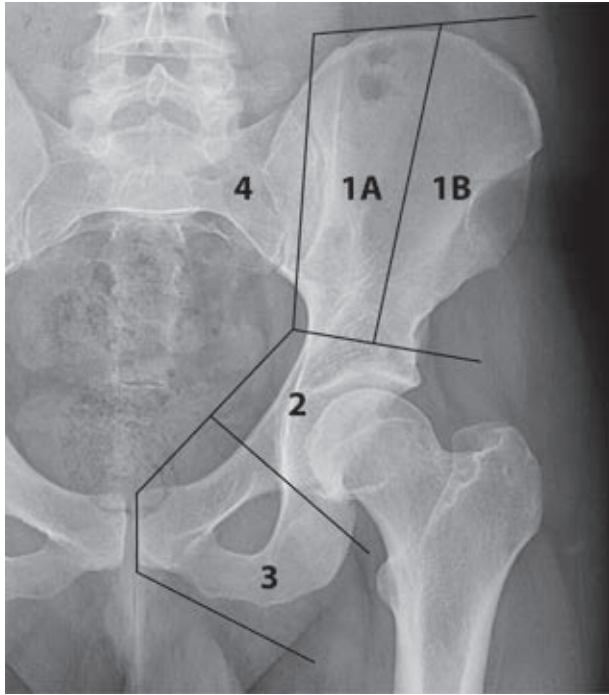
Internal hemipelvectomy, on the other hand, does not sacrifice the unaffected lower extremity (i.e. the leg on the affected side remains intact, although functionality may be impaired significantly). Internal hemipelvectomies were first performed for treatment of tumors of the ilium and pubis, and were later presented as an alternative treatment for tumors of the (peri-)acetabulum<sup>37, 38</sup>. In

1978, Enneking and Dunham proposed a classification system for pelvic tumor resections: type 1, involving the iliac wing; type 2, the periacetabular region; type 3, the pubic rami; and type 4, the sacrum (figure 5)<sup>39, 40</sup>. Isolated type 1 or type 3 resections are relatively easy and reconstruction is generally not needed because the acetabulum and weight-bearing axis are preserved<sup>38</sup>. Type 2 resections however require reconstruction in order to restore force transmission along anatomic axes, and therefore pose unique surgical challenges<sup>27, 41</sup>.

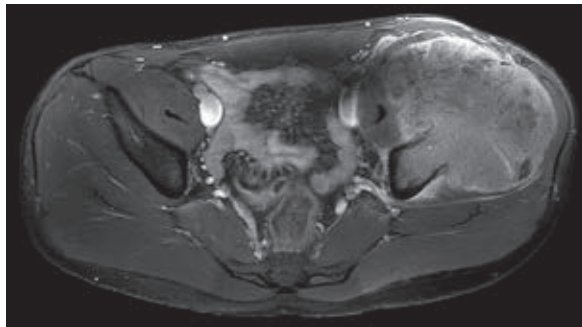


**Figure 4:** Photograph of specimen immediately after removal by hindquarter amputation (from Gordon Gordon-Taylor and Philip Wiles, Interinnomino-abdominal [hind-quarter] amputation [The British Journal of Surgery: volume XXII – No. 88, 1935]).

Although most patients with a periacetabular bone tumor can at present be treated by internal hemipelvectomy, these procedures are considered some of the most challenging operations in musculoskeletal oncology<sup>21, 41</sup>. First, pelvic neoplasms often grow to immense proportions before diagnosis (figure 6). Second, the pelvic anatomy is complex, and tumors frequently grow close to vital neurovascular structures. As a result, it is often difficult to obtain clear resection margins<sup>41, 42</sup>. Treatment of pelvic metastases is generally less complicated because the procedure is usually intralesional and therefore requires less bone and soft tissue resection<sup>38</sup>. Third, reconstruction is difficult because of high loading forces, limited bone stock, and large soft-tissue defects<sup>43-46</sup>. This reflects an important dilemma in treatment of these tumors: the decision to obtain adequate surgical margins, while salvaging enough bone to preserve longevity and function of the affected limb<sup>47</sup>.



**Figure 5:** Conventional radiograph of the pelvis showing a modified version of Enneking's classification of pelvic resections. Resections of the ilium are further subdivided into types 1A (those involving the medial part of the ilium) and type 1B (those confined to the lateral portion of the iliac wing). The innermost line depicts the resection plane of a 'conventional' hindquarter amputation.



**Figure 6:** Transverse T1-weighted MR image with SPIR selective fat suppression, demonstrating a large telangiectatic osteosarcoma originating from the left iliac wing.



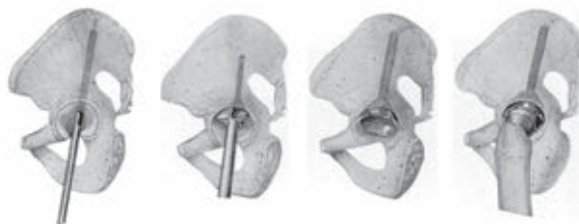

The most common primary tumor of the pelvic bones in adults is chondrosarcoma<sup>38</sup>. Pelvic chondrosarcomas are notorious for the high risk of (late) recurrence<sup>48</sup>. However, specific studies on this tumor type are lacking. Most previous studies focused on outcomes of resection and reconstructive techniques rather than on oncological outcome. However, to choose the optimal treatment and reconstructive technique, and to reduce the rate of unnecessary reoperations, it is important to identify patients with a poor prognosis in an early stage<sup>49</sup>. In chapter 2, we present a multicenter study on primary central chondrosarcoma of the pelvis. With this study, we aimed to gain insight in the outcome of treatment of this specific type of tumor, and to identify risk factors for impaired oncological outcome.

Following a type 2 internal hemipelvectomy, reconstruction can be achieved with metallic implants, biological transplants, or with techniques that utilize a combination of the two. Reconstructions with metallic implants include transposition of the center of the hip joint<sup>50</sup> and various types of endoprosthetic reconstructions<sup>41, 51, 52</sup>. Biological techniques include iliofemoral arthrodesis or pseudarthrosis<sup>53</sup>, pelvic allografts<sup>54</sup>, irradiated autografts (i.e., the resection specimen is irradiated and re-implanted)<sup>55</sup> and allograft-prosthetic composites<sup>56</sup>. Disadvantages of biological techniques include limited functional outcomes and a considerable risk of infection, nonunion, fracture, and graft resorption<sup>50, 54-58</sup>.

The majority of surgeons focused on the use of endoprosthetic (metallic) implants during the last decades. Most of the implants that have been used had originally been developed for reconstruction of large acetabular defects in extended revision hip arthroplasty<sup>41, 51</sup>. The saddle prosthesis (Link, Hamburg, Germany), which was introduced in 1979, was the first implant to be used for pelvic reconstruction in musculoskeletal oncology on a regular basis<sup>38, 51, 59, 60</sup>. Although favorable short-term results have been published<sup>38, 61</sup>, long-term clinical outcome and functional results were disappointing<sup>51</sup>. Apart from high rates of infection and implant breakage, saddle prostheses were associated with a substantial risk of cranial migration<sup>51, 62</sup>.

In the quest for a successful implant for pelvic reconstruction, many designers have come up with a stemmed acetabular device. These often show similarities to the Ring prosthesis, which was introduced in 1968. He presented a device that consisted of a cup with a long, threaded stem, designed for reconstruction of acetabular defects<sup>63</sup> (figure 7). Ring described that “weight is transferred from the sacrum to the articular facet of the ilium, and thence through a thick bar of bone which extends down to the upper part of the acetabulum”.



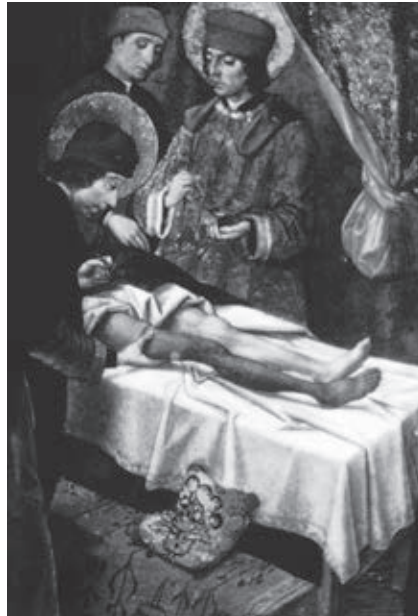**Figure 7:** Drawings of the surgical procedure of reconstructing an acetabular defect with the “Ring prosthesis”. First, a cannulated drill prepares the track for the prosthesis. Next, the cup is countersunk by using a conical reamer, and the implant is inserted (from P.A. Ring, Complete replacement arthroplasty of the hip by the ring prosthesis [Journal of Bone & Joint Surgery, British Volume: volume 50 – Issue 4, 720-731]).

The pedestal cup endoprosthesis (Schoellner cup; Zimmer, Freiburg, Germany) is one of the implant designs that follow this principle. In chapter 3, we evaluate clinical outcome of periacetabular reconstruction with the pedestal cup endoprosthesis in treatment of periacetabular tumors. Experiences with this implant in both revision hip arthroplasty and orthopaedic oncology had previously been described<sup>64-66</sup>. We were the first to report on its use in a consecutive series of patients with a pelvic malignancy<sup>41</sup>.

Based on experiences with the pedestal cup endoprosthesis, the LUMiC prosthesis (implantcast GmbH, Buxtehude, Germany) was designed. Chapter 4 evaluates the short-term clinical results of periacetabular reconstruction with this novel device, and describes results from a retrospective multicenter study<sup>52</sup>.

## Part II: Management of Extremity Bone Tumors

In the history of orthopaedic surgery, there has always been a strong desire for successful reconstruction of diseased, deformed, or disabled limbs. This dream was presumably first described in the “Miracle of the Black Leg”, in the third century AD<sup>67</sup>. In this folktale, the Saints Cosmas and Damian successfully amputated a cancerous lower limb of a church retainer, and replaced it with the leg of a Moor who had died that morning (figure 8). Over the centuries that followed, many authors reported on their attempts to successfully reconstruct a diseased (segment of) bone with an allograft – a transplant from a genetically non-identical donor of the same species. The first successful bone allograft transplantation is generally ascribed to Macewen, who reconstructed part of the humerus in a 3-year-old boy who had osteomyelitis with bone segments obtained from a rachitic patient<sup>68</sup>.

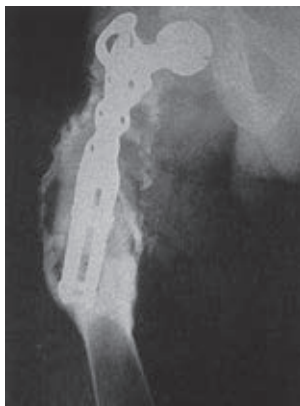

**Figure 8:** Painting of the “Miracle of the Black Leg” by Pedro de Berregete in the 15th century AD. The Saints removed the right leg of a church retainer, which was affected by a tumor, and replaced it with the leg of a Moor who had died that morning<sup>67</sup>.

Various case reports were published in the years that followed. However, it was not before the early 1970s that the first series on patients with allograft reconstructions for bone tumors were published by groups led by Volkov (Moscow, Russia), Parrish (Houston, United States) and Ottolenghi (Buenos Aires, Argentina)<sup>69-72</sup>. Many advances in the field of allotransplantation had been made in the years before. These included techniques to freeze allografts following procurement and to thaw them during tumor resection, and resulted in an enormous decrease in the risk of allograft rejection<sup>67</sup>. The progress in the use of bone allograft can in part be attributed to efforts of the United States Navy, which became interested in preservation of human bone following the Second World War. Also, it has been claimed that the US navy founded the first ‘bone bank’<sup>67</sup>.

Around the same time, other groups experimented with major prosthetic reconstruction for large osseous defects, including those caused by tumor resections<sup>22, 73</sup>. The first known report on metallic hip replacement was published in 1942 by Austin T. Moore and Harold R. Bohlmann who replaced the proximal half of the femur in a patient with a recurrent giant cell tumor of bone with a vitallium endoprosthesis (figure 9)<sup>74</sup>. In 1949, in the United Kingdom, the first large

endoprosthetic reconstruction was performed for a tumor of the distal femur, using an implant designed by professor Scales and manufactured by Stanmore (Stanmore Implants Worldwide, Elstree, United Kingdom)<sup>75</sup>. Endoprostheses at that time were custom-made, based on calculations made from radiographs of the affected bone(s), and it generally took six to eight weeks before the final endoprosthesis was ready for implantation (figure 10)<sup>22, 74, 75</sup>.



**Figure 9:** Reconstruction of the proximal femur with a “metal hip joint”, performed in 1942 by Moore and Bohlmann<sup>74</sup>.

To ensure ready availability of endoprostheses and to allow for intraoperative flexibility, Kotz from Vienna (Austria) introduced the concept of a modular implant for reconstruction of large osseous defects in 1975. Professor Kotz later developed an entire modular implant system for reconstruction of various tumor sites, the Kotz Modular Femur and Tibia Reconstruction (KMFTR) system, which relied on uncemented stem fixation with two additional plates, and had a fixed hinge for reconstructions around the knee<sup>76</sup>. Despite several changes in endoprosthetic design over the years that followed, the basic idea behind the modern modular endoprosthetic systems is still comparable with the KMFTR system<sup>73</sup>.

A few years later, Kotz and Salzer published on their early experiences with rotationplasty as an alternative method of reconstruction for patients with a tumor of the distal femur<sup>77</sup>. With this technique, that had earlier been described by Borggreve<sup>78</sup> and Van Nes<sup>79</sup> for treatment of femoral deformities, the ankle acts as a knee following resection of the knee and 180° rotation of the remaining lower limb<sup>80</sup>. Although patients have to use an external prosthesis and the cosmetic

consequences are considerable, this technique allows patients to participate in unrestricted physical activity and may yield functional results that are comparable to endoprosthetic reconstructions. Moreover, these procedures are often definitive; the need for further surgical intervention is rare<sup>80-83</sup>. As opposed to limb-salvaging techniques, it may also be used in case the vessels are involved in the tumor.



**Figure 10:** Unassembled parts of the Kotz Modular Femur and Tibia Reconstruction System<sup>76</sup>.

To understand and compare the various techniques used for reconstruction of osseous defects in the extremities, it is important to distinguish between joint replacements and intercalary (joint-preserving) reconstructions. Primary extremity bone tumors preferentially affect the meta-epiphyseal regions of the distal femur, proximal tibia, proximal humerus and proximal femur. Due to aggressive biological behavior, periarticular structures are frequently involved in the tumorous process, and partial or complete removal of the adjacent joint is commonly indicated<sup>1,14,28,84</sup>. Reconstruction can then be performed using an endoprosthesis<sup>85</sup>, an osteoarticular allograft<sup>86</sup>, or a combination of an allograft and a metallic implant – an allograft-prosthetic composite (APC)<sup>87</sup>. In other cases, however, it may be possible to salvage the joint and to perform an intercalary (segmental) resection. Several techniques have been described for reconstruction of segmental intercalary osseous defects, including allografts<sup>88</sup>, vascularized fibular autografts<sup>89</sup>, a combination of the two – the “Capanna technique”<sup>90</sup>, extracorporeally irradiated autografts<sup>91</sup>, segmental (metallic) prostheses<sup>92</sup>, or bone transport with the Ilizarov technique<sup>93</sup>.

Traditionally, massive allograft implantation was the most common technique for reconstruction of intercalary defects<sup>94</sup>. Ready availability of well-procured and

well-preserved human grafts in the Netherlands was ensured by The Leiden Bone Bank Foundation, which was founded in 1988<sup>95</sup>. In chapter 5, we evaluate the results of intercalary allograft reconstructions in treatment of primary bone tumors from the four appointed centers for orthopaedic oncology in the Netherlands<sup>84</sup>.

Orthopaedic surgeons later postulated that bone tumors with limited osseous and intramedullary involvement may be adequately treated by hemicortical (hemicylindrical) resection, leaving part of the cortical bone intact<sup>96,97</sup>. Hemicortical defects may be reconstructed using allografts<sup>96</sup>, autografts<sup>98</sup>, or autologous iliac crest grafts<sup>99</sup>. Although autografts have favorable biological properties, allografts were the preferred technique in the Netherlands, because they allow for reconstruction of larger defects. Moreover, they avoid donor site morbidity, which occurs in approximately 10% of patients and includes prolonged pain complaints, large hematomas, unsightly scars, and sensory loss<sup>100</sup>. In 2002, investigators from our center reported on the results of 22 hemicortical allograft reconstructions in treatment of low-grade malignant bone tumors<sup>96</sup>. The authors reported excellent results, with none of their patients experiencing local tumor relapse, fracture, or infection. Later, others reported comparable results, but all described small case series and most lacked long-term follow-up<sup>97-99, 101-103</sup>. In chapter 6, we present the results of a nationwide retrospective study on complications and oncological outcome after hemicortical resection of primary tumors of the musculoskeletal system<sup>104</sup>.

In the early 1990s, allografts were also commonly used for (partial) joint replacement following tumor resection<sup>105-107</sup>. It soon appeared that specific problems of joint reconstruction with allografts were the high risks of joint instability, cartilage degeneration, and subchondral collapse<sup>108-110</sup>. However, large studies focusing on the long-term outcomes of these osteoarticular allografts were lacking. In chapter 7, we evaluate our own experiences with osteoarticular allograft reconstructions, and present a systematic review of the literature, in an attempt to quantify the risk of complications after osteoarticular allograft reconstruction.

One of the major complications of allograft reconstructions is nonunion of allograft-host junctions<sup>111,112</sup>. Treatment of nonunion is often problematic because one side of the junction is comprised of nonvascular bone<sup>111</sup>. Nonunion is assumed to result from a complex interplay between biological and mechanical factors<sup>111</sup>. The influence of many factors, including the use of adjuvant chemotherapy, osteosynthesis type and location of the junction, has been thoroughly evaluated<sup>84, 88, 111, 113</sup>. On the other hand, it has been stated that construct stability and contact



between host bone and the graft – presumably in combination with compression at the junction – are the principal determinants of union<sup>114</sup>. However, the influence of contact at the allograft-host junction had never been evaluated properly. In chapter 8, we present a study on the influence of contact between the allograft and host bone in intercalary reconstructions of the femur and tibia.

During the early 1990s, endoprosthetic implants rapidly refined with respect to modularity and thus possibilities to reconstruct resected bone, consequently these implants popularised<sup>84, 112, 115-117</sup>. Endoprostheses have the advantage of providing a relatively easy and quick reconstructive technique which allows for early postoperative mobilisation and weight bearing<sup>22</sup>. Pioneering centers mainly used custom-made endoprosthetic devices during the 1970s and 1980s. An inherent but important disadvantage of custom-made implants is the lack of intraoperative flexibility (i.e. modularity)<sup>118</sup>. MUTARS® (implantcast, Buxtehude, Germany) was one of the first modular implant systems that were specifically designed for reconstruction after tumor resection or extended revision arthroplasty. As opposed to custom-made implants, modular endoprostheses allow for intraoperative adjustment, for example when greater resection is needed than was anticipated<sup>118</sup>. Moreover, modular implants are available off-the-shelf and are generally less expensive than custom-made implants<sup>118, 119</sup>. Key features of the MUTARS® system include its uncemented, hexagonal-shaped stem, saw teeth at the junctions of stems and extension pieces to allow rotational adjustment, and the attachment tube for soft-tissue reconstruction<sup>120, 121</sup>. Encouraging results of its use in orthopaedic oncology and revision arthroplasty surgery were documented<sup>120, 122, 123</sup>. However, studies focusing on the long-term results of MUTARS® reconstructions around the knee were lacking, while studies on other endoprosthetic systems demonstrated that late complications are of frequent occurrence<sup>115, 116</sup>. In chapter 9, we present a study on distal femoral and proximal tibial replacements from two Dutch tertiary referral centers<sup>121</sup>.

Finally, in chapters 10, 11, and 12, we present a general summary, general discussion, and summary in Dutch.

## References

1. Fletcher CDM, Unni KK, Mertens F, Organization WH, Cancer IAFRo. WHO classification of tumours of soft tissue and bone: IARC press; 2013.
2. Gross SW. Sarcoma of the Long Bones; Based upon a Study of One Hundred and Sixty-five Cases. *The American Journal of the Medical Sciences*. 1879;78(156):338-77.
3. Gross SW. The classic. Sarcoma of the long bones: based upon a study of one hundred and sixty-five cases. 1879. *Clinical orthopaedics and related research*. 2005 Sep;438:9-14. Epub 2005/09/01.
4. Peltier LF. *Orthopedics: a history and iconography*: Norman Publishing; 1993.
5. Enneking WF. An abbreviated history of orthopaedic oncology in North America. *Clinical orthopaedics and related research*. 2000 May(374):115-24. Epub 2000/05/20.
6. Phemister DB. The classic. Conservative bone surgery in the treatment of bone tumors. 1940. *Clinical orthopaedics and related research*. 1986 Mar(204):4-8. Epub 1986/03/01.
7. Morris H. Conservative surgery. *Lancet*. 1876;1:440.
8. Mikulicz J. Ueber Ausgedehnte Resectionen der langen Röhrenknochen Weten Maligner Geschwulste. *Arch Klin Chir*. 1895;50:60-75.
9. Lexer E. Die Verwendung der freien Knochenplastik nebst Versuchen über Gelenkversteifung und Gelenktransplantation. *Langenbecks Arch Klin Chir Ver Dtsch Z Chir*. 1908;86:939-54.
10. Linberg BE. Interscapulo-thoracic resection for malignant tumors of the shoulder joint region. *The Journal of Bone & Joint Surgery*. 1928;10(2):344-9.
11. Friedman MA, Carter SK. The therapy of osteogenic sarcoma: current status and thoughts for the future. *Journal of surgical oncology*. 1972;4(5):482-510. Epub 1972/01/01.
12. Link MP, Goorin AM, Miser AW, Green AA, Pratt CB, Belasco JB, et al. The effect of adjuvant chemotherapy on relapse-free survival in patients with osteosarcoma of the extremity. *The New England journal of medicine*. 1986 Jun 19;314(25):1600-6. Epub 1986/06/19.
13. Eilber F, Giuliano A, Eckardt J, Patterson K, Moseley S, Goodnight J. Adjuvant chemotherapy for osteosarcoma: a randomized prospective trial. *Journal of clinical oncology : official journal of the American Society of Clinical Oncology*. 1987 Jan;5(1):21-6. Epub 1987/01/01.
14. Bielack SS, Kempf-Bielack B, Delling G, Exner GU, Flege S, Helmke K, et al. Prognostic factors in high-grade osteosarcoma of the extremities or trunk: an analysis of 1,702 patients treated on neoadjuvant cooperative osteosarcoma study group protocols. *Journal of clinical oncology : official journal of the American Society of Clinical Oncology*. 2002 Feb 1;20(3):776-90. Epub 2002/02/01.
15. Bernstein M, Kovar H, Paulussen M, Randall RL, Schuck A, Teot LA, et al. Ewing's sarcoma family of tumors: current management. *The oncologist*. 2006 May;11(5):503-19. Epub 2006/05/25.
16. Rosen G. Preoperative (neoadjuvant) chemotherapy for osteogenic sarcoma: a ten year experience. *Orthopedics*. 1985 May;8(5):659-64. Epub 1985/05/01.
17. Bacci G, Longhi A, Ferrari S, Mercuri M, Versari M, Bertoni F. Prognostic factors in non-metastatic Ewing's sarcoma tumor of bone: an analysis of 579 patients treated at a single institution with adjuvant or neoadjuvant chemotherapy between 1972 and 1998. *Acta oncologica (Stockholm, Sweden)*. 2006;45(4):469-75. Epub 2006/06/09.
18. Nesbit ME, Jr., Gehan EA, Burgert EO, Jr., Vietti TJ, Cangir A, Tefft M, et al. Multimodal therapy for the management of primary, nonmetastatic Ewing's sarcoma of bone: a long-term follow-up of the First Intergroup study. *Journal of clinical oncology : official journal of the American Society of Clinical Oncology*. 1990 Oct;8(10):1664-74. Epub 1990/10/01.
19. Bone sarcomas: ESMO Clinical Practice Guidelines for diagnosis, treatment and follow-up. *Annals of oncology : official journal of the European Society for Medical Oncology / ESMO*. 2014 Sep;25 Suppl 3:iii113-23. Epub 2014/09/12.
20. Simon MA, Aschliman MA, Thomas N, Mankin HJ. Limb-salvage treatment versus amputation for osteosarcoma of the distal end of the femur. *The Journal of bone and joint surgery American volume*. 1986 Dec;68(9):1331-7. Epub 1986/12/01.
21. Grimer RJ, Chandrasekar CR, Carter SR, Abudu A, Tillman RM, Jeys L. Hindquarter amputation: is it still needed and what are the outcomes? *The bone & joint journal*. 2013 Jan;95-b(1):127-31. Epub 2013/01/12.



22. Grimer RJ, Aydin BK, Wafa H, Carter SR, Jeys L, Abudu A, et al. Very long-term outcomes after endoprosthetic replacement for malignant tumours of bone. *The bone & joint journal*. 2016 Jun;98-B(6):857-64.
23. Grimer RJ, Taminiau AM, Cannon SR. Surgical outcomes in osteosarcoma. *The Journal of bone and joint surgery British volume*. 2002 Apr;84(3):395-400. Epub 2002/05/11.
24. Tunn PU. *Treatment of bone and soft tissue sarcomas*: Springer Science & Business Media; 2008.
25. Malawer MM, Wittig JC, Bickels J. *Operative techniques in orthopaedic surgical oncology*: Lippincott Williams & Wilkins; 2012.
26. Aboulafia AJ, Malawer MM. Surgical management of pelvic and extremity osteosarcoma. *Cancer*. 1993 May 15;71(10 Suppl):3358-66. Epub 1993/05/15.
27. Satcher Jr RL, O'Donnell RJ, Johnston JO. Reconstruction of the pelvis after resection of tumors about the acetabulum. *Clinical orthopaedics and related research*. 2003 Apr(409):209-17. Epub 2003/04/03.
28. Unni KK, Inwards CY. *Dahlin's bone tumors: general aspects and data on 10,165 cases*: Lippincott Williams & Wilkins; 2010.
29. Gelderblom H, Hogendoorn PC, Dijkstra SD, van Rijswijk CS, Krol AD, Taminiau AH, et al. The clinical approach towards chondrosarcoma. *The oncologist*. 2008 Mar;13(3):320-9. Epub 2008/04/02.
30. Bloem JL, Reidsma II. Bone and soft tissue tumors of hip and pelvis. *Eur J Radiol*. 2012 Dec;81(12):3793-801.
31. Carter SR, Eastwood DM, Grimer RJ, Sneath RS. Hindquarter amputation for tumours of the musculoskeletal system. *The Journal of bone and joint surgery British volume*. 1990 May;72(3):490-3. Epub 1990/05/01.
32. Masterson EL, Davis AM, Wunder JS, Bell RS. Hindquarter amputation for pelvic tumors. The importance of patient selection. *Clinical orthopaedics and related research*. 1998 May(350):187-94. Epub 1998/05/29.
33. Apffelstaedt JP, Driscoll DL, Spellman JE, Velez AF, Gibbs JF, Karakousis CP. Complications and outcome of external hemipelvectomy in the management of pelvic tumors. *Annals of surgical oncology*. 1996 May;3(3):304-9. Epub 1996/05/01.
34. Pack GT, Miller TR. Exarticulation of the innominate bone and corresponding lower extremity (hemipelvectomy) for primary and metastatic cancer. A report of one hundred and one cases with analysis of the end results. *The Journal of bone and joint surgery American volume*. 1964 Jan;46:91-5. Epub 1964/01/01.
35. Gordon-Taylor G, Wiles P. Interinnomino-abdominal (hind-quarter) amputation. *British Journal of Surgery*. 1935;22(88):671-95.
36. Gordon-Taylor G. On malignant disease in the region of the hip-joint. *Journal of the Royal College of Surgeons of Edinburgh*. 1959 Oct;5:1-21. Epub 1959/10/01.
37. Steel HH. Partial or complete resection of the hemipelvis. An alternative to hindquarter amputation for periacetabular chondrosarcoma of the pelvis. *The Journal of bone and joint surgery American volume*. 1978 Sep;60(6):719-30. Epub 1978/09/01.
38. Aboulafia AJ, Buch R, Mathews J, Li W, Malawer MM. Reconstruction using the saddle prosthesis following excision of primary and metastatic periacetabular tumors. *Clinical orthopaedics and related research*. 1995 May(314):203-13. Epub 1995/05/01.
39. Enneking WF, Dunham WK. Resection and reconstruction for primary neoplasms involving the innominate bone. *The Journal of bone and joint surgery American volume*. 1978 Sep;60(6):731-46. Epub 1978/09/01.
40. Aponte-Tiniao L. CORR Insights: Reconstruction After Hemipelvectomy With the Ice-Cream Cone Prosthesis: What Are the Short-term Clinical Results? *Clinical orthopaedics and related research*. 2016 Mar 28. Epub 2016/03/30.
41. Bus MP, Boerhout EJ, Bramer JA, Dijkstra PD. Clinical outcome of pedestal cup endoprosthetic reconstruction after resection of a peri-acetabular tumour. *The bone & joint journal*. 2014 Dec;96-b(12):1706-12. Epub 2014/12/03.
42. Fisher NE, Patton JT, Grimer RJ, Porter D, Jeys L, Tillman RM, et al. Ice-cream cone reconstruction of the pelvis: a new type of pelvic replacement: early results. *The Journal of bone and joint surgery British volume*. 2011 May;93(5):684-8. Epub 2011/04/23.

43. Angelini A, Calabro T, Pala E, Trovarelli G, Maraldi M, Ruggieri P. Resection and reconstruction of pelvic bone tumors. *Orthopedics*. 2015 Feb 1;38(2):87-93. Epub 2015/02/11.
44. Campanacci M, Capanna R. Pelvic resections: the Rizzoli Institute experience. *The Orthopedic clinics of North America*. 1991 Jan;22(1):65-86. Epub 1991/01/01.
45. Capanna R, van Horn JR, Guernelli N, Briccoli A, Ruggieri P, Biagini R, et al. Complications of pelvic resections. *Archives of orthopaedic and trauma surgery*. 1987;106(2):71-7. Epub 1987/01/01.
46. Mavrogenis AF, Soultanis K, Patapis P, Guerra G, Fabbri N, Ruggieri P, et al. Pelvic resections. *Orthopedics*. 2012 Feb;35(2):e232-43. Epub 2012/02/09.
47. Zimel MN, Cizik AM, Rapp TB, Weisstein JS, Conrad EU, 3rd. Megaprosthesis versus Condyle-sparing intercalary allograft: distal femoral sarcoma. *Clinical orthopaedics and related research*. 2009 Nov;467(11):2813-24. Epub 2009/08/08.
48. Sherman CE, O'Connor MI, Sim FH. Survival, local recurrence, and function after pelvic limb salvage at 23 to 38 years of followup. *Clinical orthopaedics and related research*. 2012 Mar;470(3):712-27. Epub 2011/07/13.
49. Wedin R. Surgical treatment for pathologic fracture. *Acta Orthop Scand Suppl*. 2001 Jun;72(302):2p , 1-29.
50. Hoffmann C, Gosheger G, Gebert C, Jurgens H, Winkelmann W. Functional results and quality of life after treatment of pelvic sarcomas involving the acetabulum. *The Journal of bone and joint surgery American volume*. 2006 Mar;88(3):575-82. Epub 2006/03/03.
51. Jansen JA, van de Sande MA, Dijkstra PD. Poor long-term clinical results of saddle prosthesis after resection of periacetabular tumors. *Clinical orthopaedics and related research*. 2013 Jan;471(1):324-31. Epub 2012/10/12.
52. Bus MP, Szafranski A, Sellevold S, Goryn T, Jutte PC, Bramer JA, et al. LUMiC® Endoprosthetic Reconstruction After Periacetabular Tumor Resection: Short-term Results. *Clinical orthopaedics and related research*. 2016 Mar 28.
53. Fuchs B, O'Connor MI, Kaufman KR, Padgett DJ, Sim FH. Iliofemoral arthrodesis and pseudarthrosis: a long-term functional outcome evaluation. *Clinical orthopaedics and related research*. 2002 Apr(397):29-35. Epub 2002/04/16.
54. Delloye C, Banse X, Brichard B, Docquier PL, Cornu O. Pelvic reconstruction with a structural pelvic allograft after resection of a malignant bone tumor. *The Journal of bone and joint surgery American volume*. 2007 Mar;89(3):579-87. Epub 2007/03/03.
55. Sys G, Uyttendaele D, Poffyn B, Verdonk R, Verstraete L. Extracorporeally irradiated autografts in pelvic reconstruction after malignant tumour resection. *International orthopaedics*. 2002;26(3):174-8. Epub 2002/06/20.
56. Beadel GP, McLaughlin CE, Wunder JS, Griffin AM, Ferguson PC, Bell RS. Outcome in two groups of patients with allograft-prosthetic reconstruction of pelvic tumor defects. *Clinical orthopaedics and related research*. 2005 Sep;438:30-5. Epub 2005/09/01.
57. Ozaki T, Hillmann A, Bettin D, Wuisman P, Winkelmann W. High complication rates with pelvic allografts. Experience of 22 sarcoma resections. *Acta orthopaedica Scandinavica*. 1996 Aug;67(4):333-8. Epub 1996/08/01.
58. Bell RS, Davis AM, Wunder JS, Buconjic T, McGoveran B, Gross AE. Allograft reconstruction of the acetabulum after resection of stage-IIb sarcoma. Intermediate-term results. *The Journal of bone and joint surgery American volume*. 1997 Nov;79(11):1663-74. Epub 1997/12/31.
59. Aljassir F, Beadel GP, Turcotte RE, Griffin AM, Bell RS, Wunder JS, et al. Outcome after pelvic sarcoma resection reconstructed with saddle prosthesis. *Clinical orthopaedics and related research*. 2005 Sep;438:36-41. Epub 2005/09/01.
60. Cottias P, Jeanrot C, Vinh TS, Tomeno B, Anract P. Complications and functional evaluation of 17 saddle prostheses for resection of periacetabular tumors. *Journal of surgical oncology*. 2001 Oct;78(2):90-100. Epub 2001/10/02.
61. Renard AJ, Veth RP, Schreuder HW, Pruszczynski M, Keller A, van Hoesel Q, et al. The saddle prosthesis in pelvic primary and secondary musculoskeletal tumors: functional results at several postoperative intervals. *Archives of orthopaedic and trauma surgery*. 2000;120(3-4):188-94. Epub 2000/03/30.
62. Antoniadis J, Pellegrini VD, Jr. Cross-sectional anatomy of the ilium: implications for acetabular component placement in total hip arthroplasty. *Clinical orthopaedics and related research*. 2012 Dec;470(12):3537-41.


63. Ring PA. Complete replacement arthroplasty of the hip by the ring prosthesis. *The Journal of bone and joint surgery British volume*. 1968 Nov;50(4):720-31. Epub 1968/11/01.
64. Schoellner C, Schoellner D. [Pedestal cup operation in acetabular defects after hip cup loosening. A progress report]. *Zeitschrift fur Orthopadie und ihre Grenzgebiete*. 2000 May-Jun;138(3):215-21. Epub 2000/08/10.
65. Perka C, Schneider F, Labs K. Revision acetabular arthroplasty using a pedestal cup in patients with previous congenital dislocation of the hip - four case reports and review of treatment. *Archives of orthopaedic and trauma surgery*. 2002 May;122(4):237-40. Epub 2002/05/25.
66. Dominkus M, Darwish E, Funovics P. Reconstruction of the pelvis after resection of malignant bone tumours in children and adolescents. Recent results in cancer research *Fortschritte der Krebsforschung Progres dans les recherches sur le cancer*. 2009;179:85-111. Epub 2009/02/24.
67. Mankin HJ, Hornicek FJ, Gebhardt MC, Tomford WW. Bone Allograft Transplantation. *Bone Regeneration and Repair: Biology and Clinical Applications*: Springer; 2005. p. 241-61.
68. Macewen W. Observations concerning transplantation of bone. Illustrated by a case of inter-human osseous transplantation, whereby over two-thirds of the shaft of a humerus was restored. *Proceedings of the Royal Society of London*. 1881;32(212-215):232-47.
69. Volkov M. Allotransplantation of joints. *Bone & Joint Journal*. 1970;52(1):49-53.
70. Parrish FF. Allograft replacement of all or part of the end of a long bone following excision of a tumor. *The Journal of bone and joint surgery American volume*. 1973 Jan;55(1):1-22. Epub 1973/01/01.
71. Ottolenghi C, Muscolo D, Maenza R. Bone defect reconstruction by massive allograft: technique and results of 51 cases followed for 5 to 32 years. *Clinical trends in orthopedics New York: Thieme-Stratton*. 1982;1982:171-83.
72. Ottolenghi CE. Massive osteoarticular bone grafts. Transplant of the whole femur. *The Journal of bone and joint surgery British volume*. 1966 Nov;48(4):646-59. Epub 1966/11/01.
73. Pala E, Trovarelli G, Angelini A, Maraldi M, Berizzi A, Ruggieri P. Megaprosthesis of the knee in tumor and revision surgery. *Acta Bio Medica Atenei Parmensis*. 2017;88(2-5):129-38.
74. Moore AT, Bohlman HR. Metal hip joint: a case report. 1942. *Clinical orthopaedics and related research*. 2006 Dec;453:22-4.
75. Unwin PS, Cobb JP, Walker PS. Distal femoral arthroplasty using custom-made prostheses. The first 218 cases. *The Journal of arthroplasty*. 1993 Jun;8(3):259-68.
76. Kotz RI. Progress in musculoskeletal oncology from 1922 - 2012. *International orthopaedics*. 2014 May;38(5):1113-22.
77. Kotz R, Salzer M. Rotation-plasty for childhood osteosarcoma of the distal part of the femur. *The Journal of bone and joint surgery American volume*. 1982 Sep;64(7):959-69.
78. Borggreve J. [Replacement of the knee joint by the rotated ankle] [in German]. *Arch Orthop Unfall-Chir*. 1930;28:175-8.
79. van Nes CP. Transplantation of the tibia and fibula to replace the femur following resection: turn-up-plasty of the leg. *The Journal of bone and joint surgery American volume*. 1948;30:854-8.
80. Agarwal M, Puri A, Anchan C, Shah M, Jambhekar N. Rotationplasty for bone tumors: is there still a role? *Clinical orthopaedics and related research*. 2007 Jun;459:76-81. Epub 2007/04/07.
81. Forni C, Gaudenzi N, Zoli M, Manfrini M, Benedetti MG, Pignotti E, et al. Living with rotationplasty--quality of life in rotationplasty patients from childhood to adulthood. *Journal of surgical oncology*. 2012 Mar 15;105(4):331-6. Epub 2012/02/09.
82. Merkel KD, Gebhardt M, Springfield DS. Rotationplasty as a reconstructive operation after tumor resection. *Clinical orthopaedics and related research*. 1991 Sep(270):231-6. Epub 1991/09/01.
83. Rodl RW, Pohlmann U, Gosheger G, Lindner NJ, Winkelmann W. Rotationplasty--quality of life after 10 years in 22 patients. *Acta orthopaedica Scandinavica*. 2002 Jan;73(1):85-8.
84. Bus MP, Dijkstra PD, van de Sande MA, Taminiau AH, Schreuder HW, Jutte PC, et al. Intercalary allograft reconstructions following resection of primary bone tumors: a nationwide multicenter study. *The Journal of bone and joint surgery American volume*. 2014 Feb 19;96(4):e26. Epub 2014/02/21.
85. Jeys LM, Kulkarni A, Grimer RJ, Carter SR, Tillman RM, Abudu A. Endoprosthetic reconstruction for the treatment of musculoskeletal tumors of the appendicular skeleton and pelvis. *The Journal of bone and joint surgery American volume*. 2008 Jun;90(6):1265-71. Epub 2008/06/04.

86. Muscolo DL, Ayerza MA, Aponte-Tinao LA, Ranalletta M. Use of distal femoral osteoarticular allografts in limb salvage surgery. *The Journal of bone and joint surgery American volume*. 2005 Nov;87(11):2449-55. Epub 2005/11/03.
87. Donati D, Colangeli M, Colangeli S, Di Bella C, Mercuri M. Allograft-prosthetic composite in the proximal tibia after bone tumor resection. *Clinical orthopaedics and related research*. 2008 Feb;466(2):459-65. Epub 2008/01/16.
88. Ortiz-Cruz E, Gebhardt MC, Jennings LC, Springfield DS, Mankin HJ. The results of transplantation of intercalary allografts after resection of tumors. A long-term follow-up study. *The Journal of bone and joint surgery American volume*. 1997 Jan;79(1):97-106. Epub 1997/01/01.
89. Hilven PH, Bayliss L, Cosker T, Dijkstra PD, Jutte PC, Lahoda LU, et al. The vascularised fibular graft for limb salvage after bone tumour surgery: a multicentre study. *The bone & joint journal*. 2015 Jun;97-b(6):853-61. Epub 2015/06/03.
90. Capanna R, Campanacci DA, Belot N, Beltrami G, Manfrini M, Innocenti M, et al. A new reconstructive technique for intercalary defects of long bones: the association of massive allograft with vascularized fibular autograft. Long-term results and comparison with alternative techniques. *The Orthopedic clinics of North America*. 2007 Jan;38(1):51-60, vi. Epub 2006/12/06.
91. Fuchs B, Ossendorf C, Leerapun T, Sim FH. Intercalary segmental reconstruction after bone tumor resection. *European journal of surgical oncology : the journal of the European Society of Surgical Oncology and the British Association of Surgical Oncology*. 2008 Dec;34(12):1271-6. Epub 2008/01/15.
92. Chao EY, Fuchs B, Rowland CM, Ilstrup DM, Pritchard DJ, Sim FH. Long-term results of segmental prosthesis fixation by extracortical bone-bridging and ingrowth. *The Journal of bone and joint surgery American volume*. 2004 May;86-a(5):948-55. Epub 2004/05/01.
93. McCoy TH, Jr., Kim HJ, Cross MB, Fragomen AT, Healey JH, Athanasian EA, et al. Bone tumor reconstruction with the Ilizarov method. *Journal of surgical oncology*. 2013 Mar;107(4):343-52. Epub 2012/07/19.
94. Deijkers RL. Massive deep-frozen bone allografts : contamination, immunogenicity and clinical use. Dissertation, Leiden University, Leiden University Medical Center, Department of Orthopaedic Surgery. 2005.
95. Deijkers RL, Vehmeyer SB, Veen MR, Persijn GG, Bloem RM. [5-year experience with a central bone bank]. *Nederlands tijdschrift voor geneeskunde*. 1995 Mar 25;139(12):622-6. Epub 1995/03/25.
96. Deijkers RL, Bloem RM, Hogendoorn PC, Verlaan JJ, Kroon HM, Taminiau AH. Hemicortical allograft reconstruction after resection of low-grade malignant bone tumours. *The Journal of bone and joint surgery British volume*. 2002 Sep;84(7):1009-14. Epub 2002/10/03.
97. Agarwal M, Puri A, Anchan C, Shah M, Jambhekar N. Hemicortical excision for low-grade selected surface sarcomas of bone. *Clinical orthopaedics and related research*. 2007 Jun;459:161-6. Epub 2007/04/07.
98. Liu T, Liu ZY, Zhang Q, Zhang XS. Hemicortical resection and reconstruction using pasteurised autograft for parosteal osteosarcoma of the distal femur. *The bone & joint journal*. 2013 Sep;95-b(9):1275-9. Epub 2013/09/03.
99. Funovics PT, Bucher F, Toma CD, Kotz RI, Dominkus M. Treatment and outcome of parosteal osteosarcoma: biological versus endoprosthetic reconstruction. *Journal of surgical oncology*. 2011 Jun;103(8):782-9. Epub 2011/01/18.
100. Younger EM, Chapman MW. Morbidity at bone graft donor sites. *Journal of orthopaedic trauma*. 1989;3(3):192-5.
101. Lewis VO, Gebhardt MC, Springfield DS. Parosteal osteosarcoma of the posterior aspect of the distal part of the femur. Oncological and functional results following a new resection technique. *The Journal of bone and joint surgery American volume*. 2000 Aug;82-a(8):1083-8. Epub 2000/08/23.
102. Chen WM, Wu PK, Chen CF, Chung LH, Liu CL, Chen TH. High-grade osteosarcoma treated with hemicortical resection and biological reconstruction. *Journal of surgical oncology*. 2012 Jun 15;105(8):825-9. Epub 2012/01/04.
103. Lindner N, Ozaki T, Hillmann A, Blasius S, Winkelmann W. Adjuvant local treatment of parosteal osteosarcoma. *International orthopaedics*. 1996;20(4):233-6. Epub 1996/01/01.
104. Bus MP, Bramer JA, Schaap GR, Schreuder HW, Jutte PC, van der Geest IC, et al. Hemicortical resection and inlay allograft reconstruction for primary bone tumors: a retrospective evaluation in the Netherlands and review of the literature. *The Journal of bone and joint surgery American volume*. 2015 May 6;97(9):738-50.

105. Mankin HJ, Springfield DS, Gebhardt MC, Tomford WW. Current status of allografting for bone tumors. *Orthopedics*. 1992 Oct;15(10):1147-54. Epub 1992/10/01.
106. Gebhardt MC, Flugstad DI, Springfield DS, Mankin HJ. The use of bone allografts for limb salvage in high-grade extremity osteosarcoma. *Clinical orthopaedics and related research*. 1991 Sep(270):181-96. Epub 1991/09/01.
107. Muscolo DL, Ayerza MA, Aponte-Tinao LA. Survivorship and radiographic analysis of knee osteoarticular allografts. *Clinical orthopaedics and related research*. 2000 Apr(373):73-9. Epub 2000/05/16.
108. Hornicek FJ, Jr., Mnaymneh W, Lackman RD, Exner GU, Malinin TI. Limb salvage with osteoarticular allografts after resection of proximal tibia bone tumors. *Clinical orthopaedics and related research*. 1998 Jul(352):179-86. Epub 1998/07/25.
109. Rodl RW, Ozaki T, Hoffmann C, Bottner F, Lindner N, Winkelmann W. Osteoarticular allograft in surgery for high-grade malignant tumours of bone. *The Journal of bone and joint surgery British volume*. 2000 Sep;82(7):1006-10. Epub 2000/10/21.
110. Getty PJ, Peabody TD. Complications and functional outcomes of reconstruction with an osteoarticular allograft after intra-articular resection of the proximal aspect of the humerus. *The Journal of bone and joint surgery American volume*. 1999 Aug;81(8):1138-46. Epub 1999/08/31.
111. Hornicek FJ, Gebhardt MC, Tomford WW, Sorger JI, Zavatta M, Menzner JP, et al. Factors affecting nonunion of the allograft-host junction. *Clinical orthopaedics and related research*. 2001 Jan(382):87-98. Epub 2001/01/12.
112. Mankin HJ, Gebhardt MC, Jennings LC, Springfield DS, Tomford WW. Long-term results of allograft replacement in the management of bone tumors. *Clinical orthopaedics and related research*. 1996 Mar(324):86-97. Epub 1996/03/01.
113. Frisoni T, Cevolani L, Giorgini A, Dozza B, Donati DM. Factors affecting outcome of massive intercalary bone allografts in the treatment of tumours of the femur. *The Journal of bone and joint surgery British volume*. 2012 Jun;94(6):836-41. Epub 2012/05/26.
114. Stevenson S, Emery SE, Goldberg VM. Factors affecting bone graft incorporation. *Clinical orthopaedics and related research*. 1996 Mar(324):66-74.
115. Myers GJ, Abudu AT, Carter SR, Tillman RM, Grimer RJ. The long-term results of endoprosthetic replacement of the proximal tibia for bone tumours. *The Journal of bone and joint surgery British volume*. 2007 Dec;89(12):1632-7. Epub 2007/12/07.
116. Myers GJ, Abudu AT, Carter SR, Tillman RM, Grimer RJ. Endoprosthetic replacement of the distal femur for bone tumours: long-term results. *The Journal of bone and joint surgery British volume*. 2007 Apr;89(4):521-6. Epub 2007/04/28.
117. Aponte-Tinao LA, Ayerza MA, Muscolo DL, Farfalli GL. What Are the Risk Factors and Management Options for Infection After Reconstruction With Massive Bone Allografts? *Clinical orthopaedics and related research*. 2015 May 20. Epub 2015/05/21.
118. Menendez LR, Ahlmann ER, Kermani C, Gotha H. Endoprosthetic reconstruction for neoplasms of the proximal femur. *Clinical orthopaedics and related research*. 2006 Sep;450:46-51. Epub 2006/08/15.
119. Chandrasekar CR, Grimer RJ, Carter SR, Tillman RM, Abudu A, Buckley L. Modular endoprosthetic replacement for tumours of the proximal femur. *The Journal of bone and joint surgery British volume*. 2009 Jan;91(1):108-12. Epub 2008/12/19.
120. Gosheger G, Gebert C, Ahrens H, Streitbueger A, Winkelmann W, Harges J. Endoprosthetic reconstruction in 250 patients with sarcoma. *Clinical orthopaedics and related research*. 2006 Sep;450:164-71. Epub 2006/05/13.
121. Bus MP, van de Sande MA, Fiocco M, Schaap GR, Bramer JA, Dijkstra PD. What Are the Long-term Results of MUTARS Modular Endoprostheses for Reconstruction of Tumor Resection of the Distal Femur and Proximal Tibia? *Clinical orthopaedics and related research*. 2015 Dec 9. Epub 2015/12/10.
122. Gebert C, Wessling M, Gotze C, Gosheger G, Harges J. The Modular Universal Tumour And Revision System (MUTARS®) in endoprosthetic revision surgery. *International orthopaedics*. 2010 Dec;34(8):1261-5. Epub 2010/04/10.
123. Harges J, Henrichs MP, Gosheger G, Gebert C, Holl S, Dieckmann R, et al. Endoprosthetic replacement after extra-articular resection of bone and soft-tissue tumours around the knee. *The bone & joint journal*. 2013 Oct;95-b(10):1425-31. Epub 2013/10/01.

# Part I

# Management of Pelvic Bone Tumors







# Chapter 2

## Conventional Primary Central Chondrosarcoma of the Pelvis:

*Prognostic factors and outcome of surgical  
treatment in 162 patients*

M.P.A. Bus<sup>1</sup>

D.A. Campannaci<sup>2</sup>

J.I. Albergo<sup>3</sup>

A. Leithner<sup>4</sup>

M.A.J. van de Sande<sup>1</sup>

C.L. Gaston<sup>3</sup>

G. Caff<sup>2</sup>

J. Mettelsiefen<sup>5</sup>

R. Capanna<sup>2</sup>

P.U. Tunn<sup>5</sup>

L.M. Jeys<sup>3</sup>

P.D.S. Dijkstra<sup>1</sup>

<sup>1</sup> Leiden University Medical Center, Leiden, the Netherlands;

<sup>2</sup> Azienda Ospedaliera Universitaria Careggi, Florence, Italy;

<sup>3</sup> Royal Orthopaedic Hospital, Birmingham, United Kingdom;

<sup>4</sup> Medizinische Universität Graz, Graz, Austria;

<sup>5</sup> Helios Klinikum Berlin-Buch, Berlin, Germany

## Abstract

**Background:** Studies focusing on the oncological outcome after treatment of conventional primary central chondrosarcoma of pelvic bone are lacking. We conducted this retrospective study at five referral centers to gain insight in the outcome of treatment for this tumor type and to identify risk factors for impaired oncological outcome.

**Patients and Methods:** 162 consecutive patients (118 males, 73%) who underwent resection of a conventional primary central chondrosarcoma of pelvic bone from 1985-2013 were evaluated. The median age was 51 years (15-78). The median follow-up was 12.6 years (95% confidence interval [CI], 8.4 - 16.9). There were 30 grade 1 lesions (19%), 93 grade 2 lesions (57%), and 39 grade 3 lesions (24%).

**Results:** Sixty-two patients (38%) experienced local recurrence: nine grade 1 lesions (30%), 31 grade 2 lesions (33%) and 22 grade 3 lesions (56%). Forty-eight patients (30%) developed metastases. The risk of disease-related death was 3% for grade 1 tumors (1 of 30; this patient had a grade 2 recurrence and died of metastases), 33% (31 of 93) for grade 2 tumors, and 54% (21 of 39) for grade 3 tumors. Identified risk factors for impaired disease-specific survival were tumor grade (grade 2, hazard ratio [HR] 20.18,  $p=0.003$ ; grade 3, HR 58.93,  $p<0.001$ ), resection margins (marginal, HR 3.21,  $p=0.001$ ; intralesional, HR 3.56,  $p<0.001$ ) and maximal tumor size (HR 1.08 per cm,  $p=0.026$ ). Deep infection ( $n=31$ , 19%) was the predominant complication.

**Conclusions:** This study offers a standard for survival rates for conventional primary central chondrosarcoma of the pelvis. The survival for grade 1 tumors was excellent. Wide resection margins were associated with a significant survival advantage for higher-grade tumors. Because of the inability to reliably distinguish low- and high-grade tumors preoperatively, we conclude that any central pelvic chondrosarcoma should be treated with aggressive primary resection with the aim of obtaining wide resection margins. There may be aggressive biologic features in some tumors for which a surgical procedure alone may not be adequate to improve outcomes.

## Introduction

Chondrosarcomas are among the most frequent primary tumors of bone. They represent a heterogeneous group of lesions, of which the conventional primary central subtype is the most common (~75-80%)<sup>1-3</sup>. Conventional chondrosarcomas are histologically classified into grades 1 to 3. Chondrosarcoma is relatively resistant to radiation and chemotherapy, and a surgical procedure therefore remains the mainstay of treatment<sup>1-3</sup>. Although curettage with local adjuvants is generally considered a good treatment option for low-grade chondrosarcoma of long bones, most authors recommend resection with clear margins for pelvic chondrosarcoma of any grade<sup>1,4-8</sup>.

Traditionally, pelvic bone tumors were treated with hindquarter amputation (also known as external hemipelvectomy), a procedure associated with unfavorable functional and cosmetic outcomes<sup>9-12</sup>. Nowadays, most pelvic neoplasms are treated with a limb-salvaging *en bloc* resection<sup>13, 14</sup>. These internal hemipelvectomies are some of the most challenging procedures in orthopaedic oncology because of the complex pelvic anatomy, the proximity of major neurovascular structures, the fact that pelvic tumors are often large by the time of diagnosis, and challenges associated with reconstruction<sup>13-17</sup>. As a result, pelvic tumors resections are associated with a substantial risk of contaminated margins<sup>18</sup>.

Previous studies on pelvic chondrosarcoma combined different subtypes, although central chondrosarcomas are more often high-grade and appear to have a worse prognosis than secondary peripheral lesions<sup>4, 16, 19-22</sup>. The aim of this multicenter study was to assess disease-specific and progression-free survival, risk factors for impaired survival, and complications after a surgical procedure in patients treated for a conventional primary central chondrosarcoma of pelvic bone.

## Patients and Methods

A total of 170 patients who underwent surgery for a conventional (grades 1 to 3) primary central chondrosarcoma of the pelvis from 1985 to 2013 were identified through our institutional tumor databases. Eight patients (5%) underwent curettage: four grade 1 intracompartmental tumors (all continuously no evidence of disease at the time of follow-up), one grade 1 tumor with a higher-grade

recurrence that was resected (no evidence of disease at follow-up), one grade 3 tumor for which secondary resection was performed (no evidence of disease at the time of latest follow-up), and two grade 1 tumors that recurred and eventually resulted in disease-related death. To minimize bias, patients who underwent curettage were excluded from further analysis. This left 162 patients (118 male patients, 73%) with a median age of 51 years (range, 15 to 78 years) (table 1). All were followed for a minimum of two years or until death. The median follow-up was 12.6 years (95% CI, 8.4 to 16.9). Seventeen of our patients (10%) were included in previous publications: nine (6%) in a study by Fiorenza *et al*<sup>23</sup>, and eight (5%) in a study by Andreou *et al*<sup>24</sup>. Institutional review board approval was not required for this study.

Tumor grade and size, as well as infiltration of surrounding soft tissues and the hip joint, were assessed on pathology reports of the resected specimen. General criteria used to grade the lesions were cellularity, nuclear size, and the presence of abundant hyaline cartilage matrix (indicating low grade) or mucomyxoid matrix and mitoses (higher grade)<sup>1, 25</sup>. The tumor was classified as grade 1 in 30 patients (19%), grade 2 in 93 (57%) and grade 3 in 39 (24%). The median maximal tumor size was 11 cm (range, 2.5 to 25.0 cm) (data available for 151 patients [93%]). Five patients (3%) had presented with a pathological fracture. Hip (n=57, 35%) and sacroiliac joint (n=14, 9%) infiltration was defined as any form of joint involvement, either gross or focal. Soft-tissue infiltration was present in 119 patients (73%).

Tumor resections were planned on an array of conventional radiographs, computed tomography (CT) and magnetic resonance imaging (MRI). All patients received prophylactic antibiotics preoperatively, and these were continued for at least one day. The surgical approach, technique, and type of reconstruction depended on tumor location and surgeon preferences (figures 1 to 3). Primary treatment consisted of internal hemipelvectomy in 135 patients (83%) and of hindquarter amputation in 27 patients (17%). Hindquarter amputation was only performed if it was deemed impossible to obtain clear margins with a limb-salvaging resection, or if two or three of the following structures had to be sacrificed: hip joint, sciatic nerve, and femoral nerve. The most common types of internal hemipelvectomy were P2-3 (n=46, 34%), P1 (n=24, 18%), P3 (n=17, 13%) and P2 (n=14, 10%); 89 (66%) comprised the periacetabulum, 40 of which (45%) were extra-articular resections of the hip. Of 135 hemipelvectomies, 104 (77%) were reconstructed, including 60 with metallic implants (58%), 14 with allograft-

prosthetic composites (13%), and 10 with allograft reconstructions (10%). The median duration of the surgical procedures was 4.8 hours (range, 1.5 to 10.5) (data were available for 101 patients [62%]).

Surgical margins were classified as wide (resection outside the reactive zone) in 83 patients (51%), marginal (resection through the reactive zone, no tumor cells at the margins) in 42 patients (26%) and intralesional (tumor cells present at the margins) in 37 patients (23%) (table 2)<sup>26</sup>. Contaminated resections (i.e. those resections in which tumor spill occurred) were considered to be intralesional, regardless of the margins eventually achieved. Eight patients (5%) received chemotherapy, and seven patients (4%) had adjuvant radiotherapy for inadequate margins or local recurrence. The occurrence of local recurrence was assessed on imaging (usually MRI) and on histopathology in case a further surgical procedure was performed.

Kaplan-Meier curves were used to estimate disease-specific survival and progression-free survival. Disease-specific survival was defined as the time from the surgical procedure to disease-related death and was censored at the date of latest follow-up or death due to other causes. Progression-free survival was defined as the time from the surgical procedure to local recurrence or metastasis and was censored at the date of latest follow-up or death due to other causes. Prognostic factors were assessed using multivariable Cox proportional hazards models. Categorical variables were compared between groups using chi-square tests; numerical variables were compared using Mann-Whitney U tests. Outcomes are expressed in odds ratios (ORs), hazard ratios (HRs), 95% confidence intervals (CIs) and p-values. Statistical analysis was performed using SPSS version 21 (IBM), with the level of significance at  $p < 0.05$ .

**Table 1.** Study data.

	n	% of relevant group
<b>Sex</b>		
Male	118	73
Female	44	27
<b>Tumor grade and type of treatment</b>		
<i>Grade 1</i>	30	19
Internal hemipelvectomy	28	93
Hindquarter amputation	2	7
<i>Grade 2</i>	93	57
Internal hemipelvectomy	79	85
Hindquarter amputation	14	15
<i>Grade 3</i>	39	24
Internal hemipelvectomy	28	72
Hindquarter amputation	11	28
<b>Details at presentation</b>		
<i>Pathological fracture</i>	5	3
<i>Infiltration of the hip joint</i>	57	35
Grade 1	3	10
Grade 2	36	39
Grade 3	18	47
<i>Infiltration of the sacroiliac joint</i>	14	9
Grade 1	5	17
Grade 2	4	4
Grade 3	5	13
<i>Infiltration of surrounding soft-tissues</i>	119	75
Grade 1	24	83
Grade 2	62	67
Grade 3	33	87
<b>Internal hemipelvectomy types and reconstructions</b>		
<i>Type 1</i>	24	
None	17	71
Allograft	4	17
Other (minor) reconstruction	2	8
Extra-corporally irradiated autograft	1	4
<i>Type 1-2</i>	12	
Endoprosthesis	6	50
Allograft-prosthetic composite	3	25
None	1	8
Extra-corporally irradiated autograft	1	8
Transposition of the hip / iliofemoral arthrodesis	1	8
<i>Type 1-2-3</i>	8	
Endoprosthesis	5	63
None	1	13
Other (minor) reconstruction	2	25

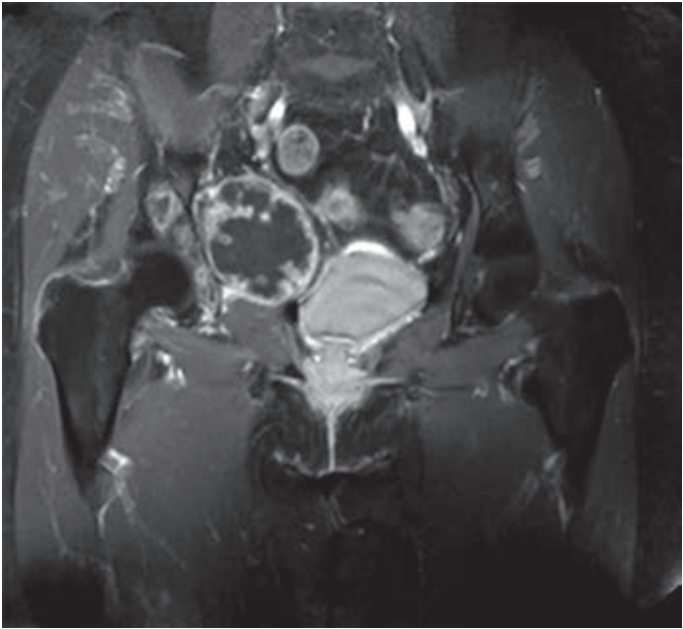
Table 1. continued

	n	% of relevant group
<b>Type 1-2-3-4</b>	4	
Endoprosthesis	2	50
Transposition of the hip / iliofemoral arthrodesis	2	50
<b>Type 1-2-4</b>	5	
Transposition of the hip / iliofemoral arthrodesis	2	40
Allograft-prosthetic composite	2	40
Endoprosthesis	1	20
<b>Type 1-4</b>	5	
None	3	60
Allograft	2	40
<b>Type 2</b>	14	
Endoprosthesis	11	79
Allograft-prosthetic composite	3	21
<b>Type 2-3</b>	46	
Endoprosthesis	35	76
Allograft-prosthetic composite	5	11
Other (minor) reconstruction	3	7
Transposition of the hip / iliofemoral arthrodesis	2	4
Extra-corporally irradiated autograft	1	2
<b>Type 3</b>	17	
None	9	53
Allograft	4	24
Other (minor) reconstruction	4	24
<b>Resection margins*</b>		
Wide	83	51
Marginal	42	26
Intralesional	37	23
<b>Progression of disease</b>		
Locally residual or recurrent tumors	62	38
Metastases	48	30
<b>Status at final follow-up*</b>		
<b>cNED</b>	71	44
Grade 1	19	63
Grade 2	43	46
Grade 3	9	23
<b>NED</b>	20	12
Grade 1	5	17
Grade 2	10	11
Grade 3	4	20
<b>AWD</b>	5	3
Grade 1	2	7
Grade 2	3	3
Grade 3	1	3

**Table 1.** continued

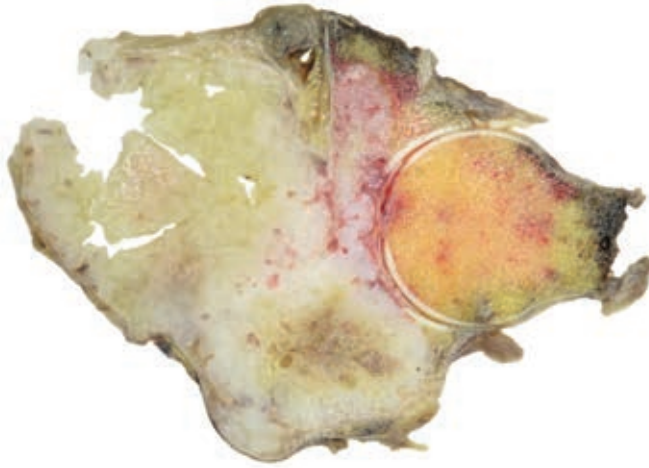
	n	% of relevant group
<i>DOD</i>	55	34
Grade 1	1	3
Grade 2	31	33
Grade 3	23	59
<i>DOC</i>	11	7
Grade 1	3	10
Grade 2	6	7
Grade 3	2	5

\*cNED, continuously no evidence of disease; NED, no evidence of disease following treatment of local or distant relapse; AWD, alive with disease; DOD, dead of disease; DOC, dead of other cause.

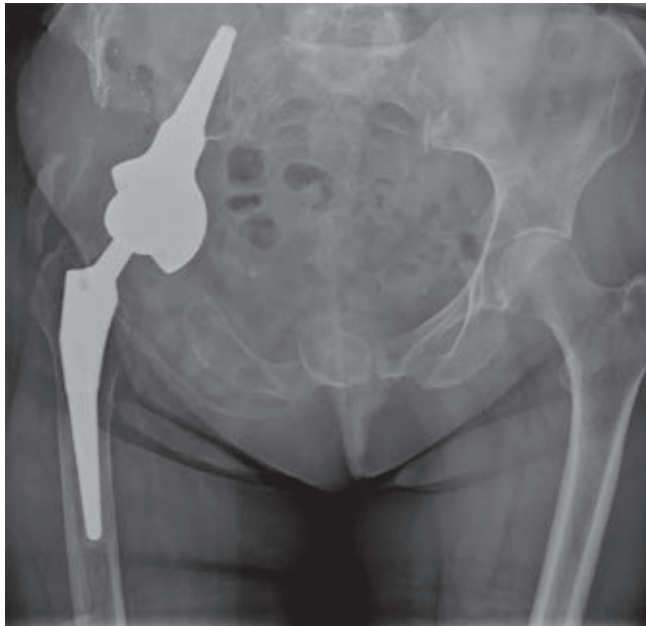


**Figure 1.** Preoperative T1 weighted MR imaging (with fat suppression) of a 67-year-old female patient, showing a chondroid tumor of the right acetabulum.





**Figure 2.** Photograph of the resected specimen after type 2-3 internal hemipelvectomy. In the periacetabulum, a grade 3 chondrosarcoma can be identified. The tumor invades the hip joint and has a maximum diameter of 11 cm. All margins were free of tumor.



**Figure 3.** Anteroposterior radiograph, taken 52 months after tumor resection and reconstruction with an uncemented LUMIC® acetabular prosthesis (implantcast, Buxtehude, Germany) and an uncemented Taperloc femoral stem (Biomet, Warsaw, IN, USA). Tantalum markers, intended for follow-up of implant fixation, can be identified in the right iliac wing. The patient continuously had no evidence of disease at final follow-up.

**Table 2.** Surgical margins in relation to tumor grade. There was no significant association between tumor grade and resection margins (chi squared test,  $p=0.110$ ).

	Wide	Marginal	Intralesional	Total
Grade 1	9 (30)	12 (40)	9 (30)	30
Grade 2	51 (55)	23 (25)	19 (20)	93
Grade 3	23 (59)	7 (18)	9 (23)	39

## Results

### Oncological outcome and risk factors for impaired outcome

At the time of latest follow-up, 96 patients (59%) were alive: 71 (44%) continuously had no evidence of disease, 19 (12%) had no evidence of disease following treatment of local relapse or metastasis and six (4%) were alive with disease. Sixty-six patients (41%) died during follow-up: 55 patients (34%) died from disease and 11 patients (7%) died from other causes.

The median disease-specific survival could not be determined because the survival curve did not cross 0.5; estimated mean disease-specific survival was 17.6 years (95% CI, 15.5 to 19.6 years) (figure 4). The estimated median progression-free survival was 9.3 years (95% CI, 3.3 to 15.3 years). Sixty-two patients (38%) experienced local recurrence: nine grade 1 lesions (30%), 31 grade 2 lesions (33%) and 22 grade 3 lesions (56%) ( $p=0.027$ ) (table 3). Four recurrent tumors (6% of 62) were of higher grade than the original tumor. Recurrent lesions were diagnosed after a median of 1.7 years (range, 0.1 to 27.3); 36 (58%) within two and 59 (95%) within five years.

The risk of disease-related death was 3% (1 of 30) for grade 1, 33% (31 of 93) for grade 2, and 54% (21 of 39) for grade 3 tumors. The patient with a grade 1 lesion who died of disease had a grade 2 recurrence that metastasized. Overall, metastases were diagnosed in 48 patients (30%), after a median of 1.9 years (range, 0.1 to 10.6). Of these, 42 (88%) died of disease, four (8%) were alive with disease at the time of latest follow-up, and two (4%) had no evidence of disease following pulmonary metastasectomy. The risk of metastasis was 32% (30 of 93) for grade 2 and 44% (17 of 39) for grade 3 tumors.

Patients with a local recurrence had a higher risk of metastases (32 of 62 [52%] versus 18 of 100 [18%]; OR 4.3, 95% CI 2.1 to 8.7,  $p < 0.001$ ) and disease-related death (39 of 62 [63%] versus 16 of 100 [16%]; OR 8.9, 95% CI 4.2 to 18.7,  $p < 0.001$ ).

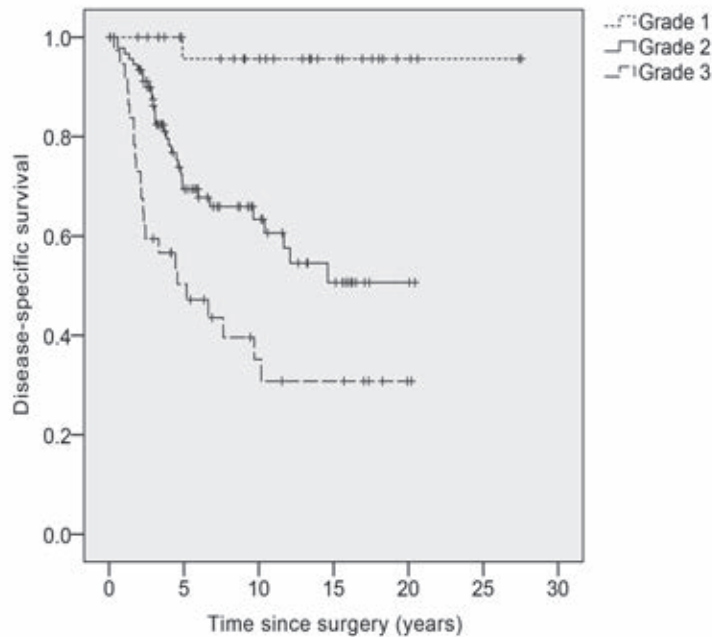
Measured from the diagnosis of local recurrence, median disease-specific survival was 2.4 years (95% CI, 1.4 to 3.4 years) for patients with a grade 2 tumor, and 1.3 years (95% CI, 0.9 to 1.7 years) for patients with a grade 3 lesion (figure 5). Of 62 patients with local recurrence, 30 (48%) developed metastases, compared with 18 of 100 (18%) patients without local recurrence (OR 4.27, 95% CI 2.09 to 8.71,  $p < 0.001$ ).

In our multivariable Cox proportional hazards model, we found that higher tumor grade, poorer resection margins, larger tumor size, and soft-tissue infiltration significantly impaired disease-specific and progression-free survival (table 4). Patient sex did not significantly influence survival. The risk of intralesional margins was lower for patients with a maximal tumor diameter of less than 10 cm (6 of 58 [10%]) than for those with a maximal tumor diameter of 10 cm or more (28 of 93 [30%]) ( $p = 0.005$ ). Although the risk of contaminated margins was higher after internal hemipelvectomy (35 of 135 [26%]) than after hindquarter amputation (2 of 27 [7%]), hemipelvectomy type did not significantly influence outcome.

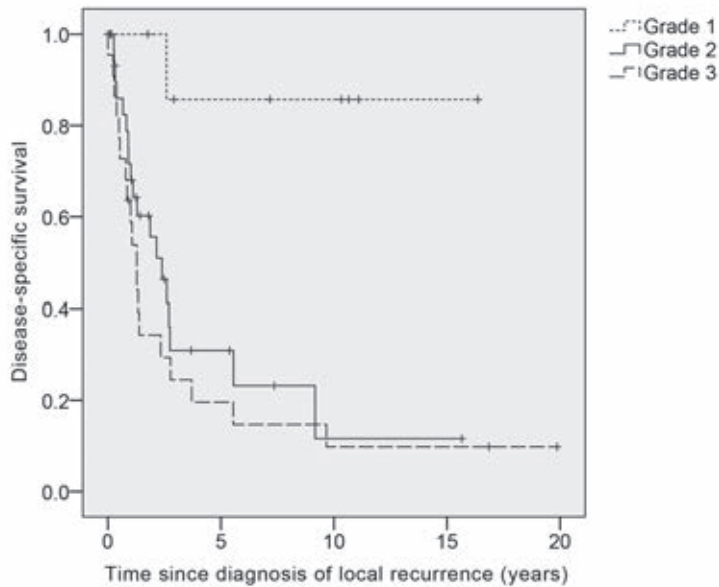
### Complications after surgery

Ninety-five patients (59%) required further operations. The main indications for reoperations were deep infection ( $n=31$  [19%]), wound problems ( $n=20$  [12%]), reconstruction-related complications ( $n=29$  [17%]) and reoperations for local recurrences ( $n=40$ , 25%). There was no significant difference in infection rates between internal hemipelvectomies (27 of 135 [20%]) and hindquarter amputations (4 of 27 [15%]) ( $p = 0.532$ ). Infection was more common in patients with an endoprosthetic reconstruction (18 of 60 [30%]), compared with patients with other types of reconstruction (8 of 45 [18%]) or no reconstruction at all (5 of 57 [9%]) ( $p = 0.014$ ).

Thirteen patients (8%) underwent secondary hindquarter amputation: 10 (6%) for locally residual or recurrent tumors, and three (2%) for infection. One patient (1%) underwent a type BII rotationplasty<sup>27</sup> because of infection. Limb-salvage was achieved in 121 patients (75%).



**Figure 4.** Kaplan-Meier curve demonstrating disease-specific survival stratified according to tumor grade (grade 1, dotted line; grade 2, solid line; grade 3, dashed line).



**Figure 5.** Kaplan-Meier curve demonstrating disease-specific survival measured for patients with a recurrence, measured from the diagnosis of recurrence (grade 1, dotted line; grade 2, solid line; grade 3, dashed line).

**Table 3.** The risk of local recurrence and metastasis in relation to tumor grade and resection margins.

	Total	Recurrence		Metastases	
	N	N	%	N	%
Grade 1					
Wide	9	2	22	0	-
Marginal	12	3	25	0	-
Intralesional	9	4	44	1	11
Grade 2					
Wide	51	9	18	12	24
Marginal	23	10	44	7	30
Intralesional	19	12	63	11	58
Grade 3					
Wide	23	11	48	4	17
Marginal	7	6	86	6	86
Intralesional	9	5	56	7	78

## Discussion

In this multicenter study, we evaluated oncological outcome, risk factors for impaired survival, and postoperative complications in 162 patients who underwent resection of a pelvic conventional primary central chondrosarcoma. Pelvic chondrosarcomas are notoriously difficult to treat and are more often of high grade, and treatment has been associated with worse outcomes than those of extremity chondrosarcoma<sup>16,24,28</sup>. Thirty-four percent of our patients died of disease. Others series on pelvic chondrosarcoma have shown that 20% to 36% of patients died of disease<sup>4,16,20,21</sup>, but these included different subtypes and primary central lesions appear to have a worse prognosis than secondary peripheral tumors<sup>4,19,21,22</sup>.

In concordance with previous studies, tumor grade was the most important prognostic factor for patient survival<sup>4, 16, 19, 21, 22, 29</sup> (table 5). Of the patients with a grade 1 lesion on the resection specimen, only one (3%) died of disease. Limited surgery may seem attractive for these low-grade pelvic chondrosarcomas, given the excellent survival rates and the favorable clinical outcome reported for curettage of low-grade extremity chondrosarcoma<sup>7</sup>. However, several problems remain to be solved. First, recurrent tumors can be of higher grade than the initial lesion, and recurrence may be regarded as a declaration of a more aggressive subtype<sup>4, 5, 30, 31</sup>. In the current series, four recurrences (6% of 62) were of higher grade than the initial tumor. Second, some lesions appear to be grade I on the biopsy specimen, but they sometimes have a higher grade when later examined on the resected specimen<sup>32, 33</sup>. Third,

curettage has been associated with unacceptably high recurrence rates in previous series on pelvic chondrosarcoma<sup>5, 31</sup>. Many authors therefore have recommended resection with clear margins for pelvic chondrosarcoma of any grade<sup>1, 4-6</sup>. As long as it is not possible to reliably distinguish between grade 1 and higher-grade lesions preoperatively, we concur with previous authors stating that *en bloc* resection is the preferable treatment option for pelvic chondrosarcoma<sup>5, 31</sup>.

Tumor grade was also found to be associated with the risk of tumor recurrence. Previous studies showed conflicting results with regard to chondrosarcoma grade and recurrence rates<sup>19, 23</sup>. Ninety-five percent of the recurrences occurred within in the first five years after the surgical procedure. Therefore, we recommend close follow-up with an annual MRI scan during the first postoperative years (figure 6), although the utility and accuracy of MRI scans may be hampered by the presence of metallic implants. Alternatively, a CT-scan or fluorine-18 fluorodeoxyglucose positron emission tomography (FDG PET) imaging can be obtained, although less aggressive lesions may not be avid on PET<sup>34</sup>.

Although survival rates after marginal and intralesional resection were nearly identical, wide resection margins were associated with a significant survival advantage. Although wide margins do not eliminate the possibility of recurrent disease<sup>19, 25, 28</sup>, margins were the only treatment-related prognostic factor. After diagnosis of local relapse, the median survival was 2.4 years for grade 2 tumors, and 1.3 years for grade 3 tumors. These poor survival rates, combined with the association between margins and the risk of recurrence and disease-related death, underline the importance of obtaining wide margins during primary resection.

Tumor size was the third most important prognostic factor in our multivariable model; for each centimeter of increase in maximal tumor size, the risk of disease-related death increased by 8%. Others also found an influence of chondrosarcoma size or volume on oncological outcome, but only performed univariable analyses<sup>24, 35, 36</sup>. One study identified a weak influence only on the risk of local recurrence, not survival or metastasis, in multivariable analyses<sup>23</sup>. The presence of soft-tissue infiltration significantly influenced progression-free survival, but failed to reach significance in our analyses on disease-related death. In contrast to our results, Fiorenza *et al* previously reported an influence of soft-tissue infiltration on survival, but not local recurrence, for chondrosarcomas of the axial and appendicular skeleton<sup>23</sup>. In contrast with an earlier study<sup>24</sup>, the prognostic significance of soft tissue infiltration and tumor size in our study suggest that both the Enneking system and the AJCC classification appear to be reasonable

classification systems for pelvic chondrosarcoma<sup>26, 37</sup>. However, neither contain all significant variables that were identified in our study, suggesting a need for a new staging system, although such a system would need to be validated.

**Table 4.** Results of Cox proportional hazards models for disease-specific and progression-free survival

	Univariable analysis	Multivariable analysis		
	p-value	HR	95% CI	p-value
<b>Disease-specific survival (DSS), variables:</b>				
<i>Tumor grade</i>				
Grade 1	-	Ref	-	-
Grade 2	0.009	20.18	2.71 – 150.17	0.003
Grade 3	0.001	58.94	7.67 – 452.89	<0.001
<i>Resection margins</i>				
Wide	-	Ref	-	-
Marginal	0.029	3.21	1.57 – 6.53	0.001
Intralesional	0.008	3.56	1.80 – 7.02	<0.001
<i>Maximal tumor size</i>	0.072	1.08	1.01 – 1.16	0.026
<i>Soft-tissue infiltration (yes vs. no)</i>	0.088	2.37	0.99 – 5.68	0.052
<i>Hemipelvectomy type (internal vs. external)</i>	0.608	1.38	0.64 – 2.97	0.409
<b>Progression-free survival (PFS), variables:</b>				
<i>Tumor grade</i>				
Grade 1	-	Ref	-	-
Grade 2	0.035	2.73	1.26 – 5.90	0.011
Grade 3	<0.001	8.50	3.58 – 20.14	<0.001
<i>Resection margins</i>				
Wide	-	Ref	-	-
Marginal	0.061	2.32	1.29 – 4.16	0.005
Intralesional	0.005	2.36	1.31 – 4.26	0.004
<i>Maximal tumor size</i>	0.062	1.08	1.02 – 1.15	0.013
<i>Soft-tissue infiltration (yes vs. no)</i>	0.005	2.41	1.12 – 5.20	0.024
<i>Hemipelvectomy type (internal vs. external)</i>	0.957	1.88	0.91 – 3.90	0.091

Pelvic resections and reconstructions are notorious for the high risk of postoperative complications, of which infection is the most common. Infected pelvic reconstructions may require aggressive surgical treatment, including removal of reconstruction materials or even, although rarely, hindquarter amputation<sup>38</sup>. Our infection rate (19%) is comparable to previously reported incidences (18% to 32%)<sup>18, 38-42</sup>. The risk of infection was higher for patients after endoprosthetic reconstruction, although this increased risk may have been caused by the fact that these surgical procedures were the most extensive and complicated ones.

Our study had a number of limitations. We included patients who were treated in five different centers between 1985 and 2013. Over the years, available imaging techniques and treatment modalities have changed and have likely influenced our results. Moreover, different pathologists have assessed tumor grades and margins and these were not re-evaluated, although the grading system for chondrosarcoma is inherently subjective and it has been shown that the interobserver reliability of this classification is poor<sup>32,33</sup>. However, we only included patients from referral centers with specialized pathologists and, because of the rarity of this disease, multicenter cooperation is necessary to gain sufficient power. Further research is needed to develop techniques to reliably determine tumor grade and clinical behavior preoperatively, potentially using molecular markers<sup>1</sup>. Also, further study should be directed at the role of limited surgical procedures for low-grade chondrosarcoma of the pelvis. Moreover, the exact margin needed to adequately treat pelvic chondrosarcoma, especially grade 1 lesions, will have to be determined in a prospective study.

In conclusion, this study offers a standard for survival rates for conventional primary central chondrosarcoma of the pelvis. Survival is excellent for patients with a grade 1 tumor and a limited surgical procedure may therefore seem attractive, although we cannot draw conclusions in that regard. However, higher-grade tumors have a substantial risk of disease-related death. We demonstrated that wide resection margins offer a significant survival advantage over marginal and intralesional margins for grade 2 and 3 tumors. Because of the inability to reliably distinguish low-grade and high-grade tumors preoperatively, we conclude that any central pelvic chondrosarcoma should be treated with aggressive primary resection with the aim of obtaining wide resection margins, understanding that there may be aggressive biologic features in some tumors for which a surgical procedure alone may not be adequate to improve outcomes.



**Table 5.** Overview of literature on pelvic chondrosarcoma.

Reference	Years of surgery	Patients	Chondrosarcoma subtypes	Follow-up	Primary hindquarter amputation	Clear margins	Recurrence	Metastasis	Infection	Limb salvage at time of follow-up	Risk factors for impaired survival	Notes
Donati	1971 - 1999	124	Conventional central (51%) and peripheral (49%)	N/R	24%	Wide margins: 73% of central and 57% of peripheral tumors	18%	8%	N/R	N/R	Tumor grade, internal hemipelvectomy	Curettage in 1%. No relationship between grade and LR rate (but higher rate of ablative surgery for grade 3 lesions). Central lesions had worse long-term survival (73% at follow-up).
Guo	1997 - 2006	45	Conventional (71%), dedifferentiated (20%), mesenchymal (9%); all involving the periacetabulum	Survivors: mean 3.1 (1.5-9.9) Deceased: mean 3.6 (0.6-5.9)	13%	84%	22%	22%	11%	N/R	-	29% of the patients were initially treated elsewhere. No association between obtained margins and the occurrence of metastases.
Mavrogenis	1975 - 2008	215	Primary or secondary conventional central (55%), peripheral (40%), not specified (4%), periosteal (1%)	Mean 8.6 (2-31)	19%	84%	30%	14% (of the patients without metastases at diagnosis)	N/R	N/R	Tumor grade	Curettage in 3%. Tumor grade was the most important prognostic factor. Patients with a periacetabular lesion had worse survival.
Mochizuki	1989 - 1998	135	N/R	Mean 3.9 (0.3-10.0)	10%	79%	24%	19%	19%	N/R	Tumor stage, site, size and achieved margins	Patients included from 58 institutions.
Sheth	1970 - 1992	67	Primary or secondary conventional (81%) and dedifferentiated (19%)	Survivors: median 9.6 (2.0-24.0) Deceased: median 0.9 (0.0-10.3)	52%	57%	28%	36%	N/R	N/R	Tumor grade	Inadequate margins, tumor epicenter in the pubis, and tumor grade were associated with an increased risk of local recurrence.



Table 5. continued

Reference	Years of surgery	Patients	Chondrosarcoma subtypes	Follow-up	Primary hindquarter amputation	Clear margins	Recurrence	Metastasis	Infection	Limb salvage at time of follow-up	Risk factors for impaired survival	Notes
Deloin	1968 - 2003	59	Primary (n=47), secondary (n=9) and multiple (n=3)	Survivors: mean 10.3 (4.0-22.7) Deceased: mean 5.6 (0.3-26.0)	19%	81%	31%	20%	10%	75%	Resection margins, tumor grade, acetabular involvement	-
Ozaki	1970 - 1993	31	Primary (n=23) and secondary (n=8)	Median 5.0 years (0.3-22.3)	26%	Wide margins: 26%	45%	6%	16%	61%	Tumor grade	Resection margin correlated with local recurrence rate.
Pring	1975 - 1996	64	Primary (n=49) or secondary (n=15); conventional (n=57) and dedifferentiated (n=7)	Survivors: median 11.7 (3.3-24.6)	20%	83%	19%	17%	13%	80%	Tumor grade, tumor stage and having a primary lesion.	Curettage in 5%. Resection margin correlated with local recurrence rate.
Wirbel	1978 - 1998	51	N/R	Mean 6.1 (0.3-19.1)	25%	84%	20%	35%	20%	69%	Tumor stage, resection margin	Two perioperative deaths.
Current study	1985 - 2013	162	Conventional primary central	Survivors: median 9.2 (2.0-27.5) Deceased: median 3.0 (0.1-15.1)	17%	77%	38%	30%	19%	75%	Tumor grade, resection margins, tumor size, soft-tissue infiltration	-

## References

1. Gelderblom H, Hogendoorn PC, Dijkstra SD, van Rijswijk CS, Krol AD, Taminiau AH, et al. The clinical approach towards chondrosarcoma. *The oncologist*. 2008 Mar;13(3):320-9. Epub 2008/04/02.
2. Bovee JV, Hogendoorn PC, Wunder JS, Alman BA. Cartilage tumours and bone development: molecular pathology and possible therapeutic targets. *Nature reviews Cancer*. 2010 Jul;10(7):481-8. Epub 2010/06/11.
3. Giuffrida AY, Burgueno JE, Koniaris LG, Gutierrez JC, Duncan R, Scully SP. Chondrosarcoma in the United States (1973 to 2003): an analysis of 2890 cases from the SEER database. *The Journal of bone and joint surgery American volume*. 2009 May;91(5):1063-72. Epub 2009/05/05.
4. Mavrogenis AF, Angelini A, Drago G, Merlino B, Ruggieri P. Survival analysis of patients with chondrosarcomas of the pelvis. *Journal of surgical oncology*. 2013 Jul;108(1):19-27. Epub 2013/05/18.
5. Streiburger A, Ahrens H, Balke M, Buerger H, Winkelmann W, Gosheger G, et al. Grade I chondrosarcoma of bone: the Munster experience. *Journal of cancer research and clinical oncology*. 2009 Apr;135(4):543-50. Epub 2008/10/16.
6. Angelini A, Guerra G, Mavrogenis AF, Pala E, Picci P, Ruggieri P. Clinical outcome of central conventional chondrosarcoma. *Journal of surgical oncology*. 2012 Dec;106(8):929-37. Epub 2012/06/01.
7. Verdegaal SH, Brouwers HF, van Zwet EW, Hogendoorn PC, Taminiau AH. Low-grade chondrosarcoma of long bones treated with intralesional curettage followed by application of phenol, ethanol, and bone-grafting. *The Journal of bone and joint surgery American volume*. 2012 Jul 3;94(13):1201-7. Epub 2012/07/05.
8. Meftah M, Schult P, Henshaw RM. Long-term results of intralesional curettage and cryosurgery for treatment of low-grade chondrosarcoma. *The Journal of bone and joint surgery American volume*. 2013 Aug 7;95(15):1358-64. Epub 2013/08/09.
9. Grimer RJ, Chandrasekar CR, Carter SR, Abudu A, Tillman RM, Jeys L. Hindquarter amputation: is it still needed and what are the outcomes? *The bone & joint journal*. 2013 Jan;95-b(1):127-31. Epub 2013/01/12.
10. Carter SR, Eastwood DM, Grimer RJ, Sneath RS. Hindquarter amputation for tumours of the musculoskeletal system. *The Journal of bone and joint surgery British volume*. 1990 May;72(3):490-3. Epub 1990/05/01.
11. Griesser MJ, Gillette B, Crist M, Pan X, Muscarella P, Scharschmidt T, et al. Internal and external hemipelvectomy or flail hip in patients with sarcomas: quality-of-life and functional outcomes. *American journal of physical medicine & rehabilitation / Association of Academic Physiatrists*. 2012 Jan;91(1):24-32. Epub 2011/11/02.
12. Masterson EL, Davis AM, Wunder JS, Bell RS. Hindquarter amputation for pelvic tumors. The importance of patient selection. *Clinical orthopaedics and related research*. 1998 May(350):187-94. Epub 1998/05/29.
13. Bus MP, Boerhout EJ, Bramer JA, Dijkstra PD. Clinical outcome of pedestal cup endoprosthetic reconstruction after resection of a peri-acetabular tumour. *The bone & joint journal*. 2014 Dec;96-b(12):1706-12. Epub 2014/12/03.
14. Bus MP, Szafranski A, Sellevold S, Goryn T, Jutte PC, Bramer JA, et al. LUMiC® Endoprosthetic Reconstruction After Periacetabular Tumor Resection: Short-term Results. *Clinical orthopaedics and related research*. 2016 Mar 28.
15. Weber KL, Pring ME, Sim FH. Treatment and outcome of recurrent pelvic chondrosarcoma. *Clinical orthopaedics and related research*. 2002 Apr(397):19-28. Epub 2002/04/16.
16. Pring ME, Weber KL, Unni KK, Sim FH. Chondrosarcoma of the pelvis. A review of sixty-four cases. *The Journal of bone and joint surgery American volume*. 2001 Nov;83-a(11):1630-42. Epub 2001/11/10.
17. Kawai A, Healey JH, Boland PJ, Lin PP, Huvos AG, Meyers PA. Prognostic factors for patients with sarcomas of the pelvic bones. *Cancer*. 1998 Mar 1;82(5):851-9. Epub 1998/03/05.
18. Angelini A, Calabro T, Pala E, Trovarelli G, Maraldi M, Ruggieri P. Resection and reconstruction of pelvic bone tumors. *Orthopedics*. 2015 Feb 1;38(2):87-93. Epub 2015/02/11.
19. Donati D, El Ghoneimy A, Bertoni F, Di Bella C, Mercuri M. Surgical treatment and outcome of conventional pelvic chondrosarcoma. *The Journal of bone and joint surgery British volume*. 2005 Nov;87(11):1527-30. Epub 2005/11/02.

20. Guo W, Li D, Tang X, Ji T. Surgical treatment of pelvic chondrosarcoma involving periacetabulum. *Journal of surgical oncology*. 2010 Feb 1;101(2):160-5. Epub 2009/12/05.
21. Sheth DS, Yasko AW, Johnson ME, Ayala AG, Murray JA, Romsdahl MM. Chondrosarcoma of the pelvis. Prognostic factors for 67 patients treated with definitive surgery. *Cancer*. 1996 Aug 15;78(4):745-50. Epub 1996/08/15.
22. Ozaki T, Hillmann A, Lindner N, Blasius S, Winkelmann W. Chondrosarcoma of the pelvis. *Clinical orthopaedics and related research*. 1997 Apr(337):226-39. Epub 1997/04/01.
23. Fiorenza F, Abudu A, Grimer RJ, Carter SR, Tillman RM, Ayoub K, et al. Risk factors for survival and local control in chondrosarcoma of bone. *The Journal of bone and joint surgery British volume*. 2002 Jan;84(1):93-9. Epub 2002/02/12.
24. Andreou D, Ruppin S, Fehlberg S, Pink D, Werner M, Tunn PU. Survival and prognostic factors in chondrosarcoma: results in 115 patients with long-term follow-up. *Acta orthopaedica*. 2011 Dec;82(6):749-55. Epub 2011/11/10.
25. Evans HL, Ayala AG, Romsdahl MM. Prognostic factors in chondrosarcoma of bone: a clinicopathologic analysis with emphasis on histologic grading. *Cancer*. 1977 Aug;40(2):818-31. Epub 1977/08/01.
26. Enneking WF, Spanier SS, Goodman MA. A system for the surgical staging of musculoskeletal sarcoma. *Clinical orthopaedics and related research*. 1980 Nov-Dec(153):106-20. Epub 1980/11/01.
27. Winkelmann WW. Rotationplasty. *The Orthopedic clinics of North America*. 1996 Jul;27(3):503-23. Epub 1996/07/01.
28. Bjornsson J, McLeod RA, Unni KK, Ilstrup DM, Pritchard DJ. Primary chondrosarcoma of long bones and limb girdles. *Cancer*. 1998 Nov 15;83(10):2105-19. Epub 1998/11/25.
29. Wirbel RJ, Schulte M, Maier B, Koschnik M, Mutschler WE. Chondrosarcoma of the pelvis: oncologic and functional outcome. *Sarcoma*. 2000;4(4):161-8. Epub 2008/06/04.
30. Schwab JH, Wenger D, Unni K, Sim FH. Does local recurrence impact survival in low-grade chondrosarcoma of the long bones? *Clinical orthopaedics and related research*. 2007 Sep;462:175-80. Epub 2007/05/22.
31. Normand AN, Cannon CP, Lewis VO, Lin PP, Yasko AW. Curettage of biopsy-diagnosed grade 1 periacetabular chondrosarcoma. *Clinical orthopaedics and related research*. 2007 Jun;459:146-9. Epub 2007/04/25.
32. SLICED Study Group. Reliability of histopathologic and radiologic grading of cartilaginous neoplasms in long bones. *The Journal of bone and joint surgery American volume*. 2007 Oct;89(10):2113-23. Epub 2007/10/03.
33. Eefting D, Schrage YM, Geirnaerdt MJ, Le Cessie S, Taminiau AH, Bovee JV, et al. Assessment of interobserver variability and histologic parameters to improve reliability in classification and grading of central cartilaginous tumors. *The American journal of surgical pathology*. 2009 Jan;33(1):50-7. Epub 2008/10/15.
34. Brenner W, Conrad EU, Eary JF. FDG PET imaging for grading and prediction of outcome in chondrosarcoma patients. *Eur J Nucl Med Mol Imaging*. 2004 Feb;31(2):189-95.
35. Lee FY, Mankin HJ, Fondren G, Gebhardt MC, Springfield DS, Rosenberg AE, et al. Chondrosarcoma of bone: an assessment of outcome. *The Journal of bone and joint surgery American volume*. 1999 Mar;81(3):326-38. Epub 1999/04/13.
36. Mochizuki K, Yamaguchi H, Umeda T. The management of pelvic chondrosarcoma in Japan. *Japanese Musculo-Skeletal Oncology Group. International orthopaedics*. 2000;24(2):65-70. Epub 2000/07/14.
37. Greene F, Page D, Fleming I. *AJCC manual of staging of cancer*. New York, NY: SpringerVerlag. 2002.
38. Angelini A, Drago G, Trovarelli G, Calabro T, Ruggieri P. Infection after surgical resection for pelvic bone tumors: an analysis of 270 patients from one institution. *Clinical orthopaedics and related research*. 2014 Jan;472(1):349-59. Epub 2013/08/27.
39. Mavrogenis AF, Soultanis K, Patapis P, Guerra G, Fabbri N, Ruggieri P, et al. Pelvic resections. *Orthopedics*. 2012 Feb;35(2):e232-43. Epub 2012/02/09.
40. Gebert C, Wessling M, Hoffmann C, Roedl R, Winkelmann W, Gosheger G, et al. Hip transposition as a limb salvage procedure following the resection of periacetabular tumors. *Journal of surgical oncology*. 2011 Mar 1;103(3):269-75. Epub 2011/02/22.

41. Jaiswal PK, Aston WJ, Grimer RJ, Abudu A, Carter S, Blunn G, et al. Peri-acetabular resection and endoprosthetic reconstruction for tumours of the acetabulum. *The Journal of bone and joint surgery British volume*. 2008 Sep;90(9):1222-7. Epub 2008/09/02.
42. Hillmann A, Hoffmann C, Gosheger G, Rodl R, Winkelmann W, Ozaki T. Tumors of the pelvis: complications after reconstruction. *Archives of orthopaedic and trauma surgery*. 2003 Sep;123(7):340-4. Epub 2003/07/03.



# Chapter 3

## **Clinical Outcome of Pedestal Cup Endoprosthetic Reconstruction After Resection of a Periacetabular Tumor**

M.P.A. Bus<sup>1</sup>

E.J. Boerhout<sup>1</sup>

J.A.M. Bramer<sup>2</sup>

P.D.S. Dijkstra<sup>1</sup>

<sup>1</sup>Orthopaedic Surgery, Leiden University Medical Center, Leiden, the Netherlands

<sup>2</sup>Orthopaedic Surgery, Academic Medical Center, Amsterdam, the Netherlands

*Bone Joint J* 2014;96-B:1706-12.

## Abstract

Periacetabular tumor resections and their subsequent reconstruction are among the most challenging procedures in orthopaedic oncology. Despite the fact that a number of different pelvic endoprostheses have been introduced, rates of complication remain high and long-term results are mostly lacking.

In this retrospective study, we aimed to evaluate the outcome of reconstructing a periacetabular defect with a pedestal cup endoprosthesis after a type 2 or type 2/3 internal hemipelvectomy.

A total of 19 patients (11 male, 8 female) with a mean age of 48 years (14 to 72) were included, most of whom had been treated for a primary bone tumor ( $n = 16$ ) between 2003 and 2009. After a mean follow-up of 39 months (28 days to 8.7 years), seven patients had died. After a mean follow-up of 7.9 years (4.3 to 10.5), 12 patients were alive, of whom 11 were disease-free. Complications occurred in 15 patients. Three had recurrent dislocations and three experienced aseptic loosening. There were no mechanical failures. Infection occurred in nine patients, six of whom required removal of the prosthesis. Two patients underwent hindquarter amputation for local recurrence.

The implant survival rate at five years was 50% for all reasons, and 61% for non-oncological reasons. The mean Musculoskeletal Tumor Society score at final follow-up was 49% (13% to 87%).

Based on these poor results, we advise caution if using the pedestal cup for reconstruction of a periacetabular tumor resection.



## Introduction


Primary sarcomas of the pelvis commonly involve periacetabular bone. Traditionally these were treated by hindquarter amputation with a poor functional outcome and quality of life<sup>1</sup>. Because of the advances in chemotherapy, preoperative imaging and surgical techniques, limb-salvage surgery has become increasingly popular. At present, most patients are treated with a type 2 or type 2/3<sup>2</sup> internal hemipelvectomy, followed by reconstruction of the defect<sup>3</sup>. These are some of the most challenging procedures in orthopaedic oncology. First, it is often difficult to achieve adequate margins due to the complex anatomy, size of the tumor and proximity of major neurovascular structures<sup>4</sup>. Second, reconstruction of a functional and painless limb is demanding, because of the complex biomechanics and extent of the resection. Third, infection is of major concern, with reported rates of up to 40% whichever method of reconstruction is used.<sup>5-8</sup>

A number of techniques have been described for the reconstruction of a periacetabular defect. Although associated with a significant reduction in range of movement, some authors prefer to perform an iliofemoral arthrodesis or pseudarthrosis. However, failure to obtain a solid fusion is a frequent occurrence and results in a painful reconstruction with poor function<sup>9</sup>. Others have attempted to reconstruct the defect using allografts, irradiated autografts or an allograft-prosthetic composite<sup>6,7,10</sup>. However, allografts are associated with a high rate of failure because of nonunion, fracture and graft resorption<sup>6,7,10,11</sup>. If an allograft becomes infected it is difficult to treat and often has to be removed<sup>12</sup>. An alternative technique, hip transposition, causes significant shortening of the limb but may result in reasonable function. It tends to be used as a salvage procedure after failure of other forms of reconstruction<sup>13</sup>.

Much thought has also been given to endoprosthetic reconstruction of pelvic defects and a number of different types of endoprostheses have been employed. Although encouraging results have been reported, mechanical complications are frequent<sup>5,8,14,15</sup>. Dislocation is reported to occur in 12% to 22%, while 3% to 12% experience aseptic loosening. Reoperations are often needed: secondary rotationplasty, hip transposition or hindquarter amputation may be needed<sup>3,4,8,16-18</sup>.

Musculoskeletal oncologists generally agree that reconstructing a pelvic defect with an endoprosthesis has the greatest potential to achieve a well-functioning limb<sup>3,4,19</sup>. Nevertheless, long-term results are limited and little is known about the durability of these reconstructions. Meanwhile, the search continues for new, more successful prostheses.

We have used the titanium pedestal cup prosthesis (Zimmer, Freiburg, Germany) to reconstruct type 2 and type 2/3 defects of the pelvis. The prosthesis was originally designed for use after the extensive revision of a total hip replacement (figure 1). To the best of our knowledge, we are the first to describe its use in a consecutive series of patients with a pelvic malignancy. In this two-center retrospective study, our aims were to evaluate the mid- to long-term survival of the implant, its complications and the patient's resulting functional outcome and quality of life.



**Figure 1:** Photograph showing the pedestal cup prosthesis.

## Patients and Methods

After obtaining institutional ethics board approval, we assessed all consecutive patients in whom a pedestal cup had been used to reconstruct the defect created by a type 2 or type 2/3<sup>2</sup> internal hemipelvectomy for pelvic malignancy between 2003 and 2009.

There were 19 patients (11 male, 8 female) with a mean age of 48 years (14 to 72) at the time of surgery. The principal diagnosis was chondrosarcoma in 13, Ewing's sarcoma in three and metastatic carcinoma in three. All lesions involved the acetabulum and were Enneking stage 2B<sup>20</sup>. A total of four patients had undergone previous surgery, including three total hip replacements and one allograft-prosthetic reconstruction which failed due to resorption of the allograft.

The implant consists of a hemispherical acetabular component and a porous-coated, one-size titanium 70 mm stem, with an 11-mm maximum core diameter. The stem is ribbed and carries two 5 mm wings to secure rotational stability. A cylindrical segment (available in 0 mm, 10 mm and 20 mm lengths) connects the acetabular component with the stem. A standard polyethylene liner was used. Triplanar CT images were obtained for pre-operative templating (figure 2). Computer-navigated techniques were not routinely used.

Cephalosporins were given intravenously prior to surgery and were usually continued for five days postoperatively. Patients were placed in the lateral decubitus position which allowed them to be rotated almost prone or supine. The incision started posteriorly and was extended superiorly across the iliac crest to the anterior superior iliac spine and then angled distally along the line of the femoral artery, to a point approximately 10 cm distal to the greater trochanter. After *en bloc* tumor resection, a Kirschner (K-) wire was inserted in the medial part of the remaining ilium, adjacent to the sacroiliac joint, to guide implantation of the stem. This part of the ilium (part 1A according to a modified version of Enneking's classification)<sup>8</sup>, (figure 3) allows a prosthesis to be seated well between the anterior and posterior cortices because of its shape.

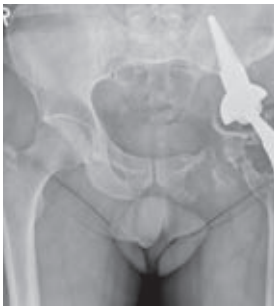

Figure 2A.

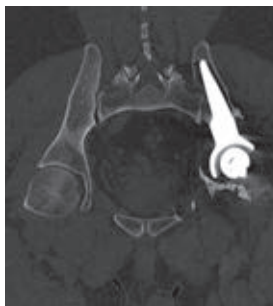

Figure 2B.

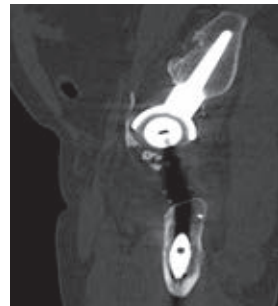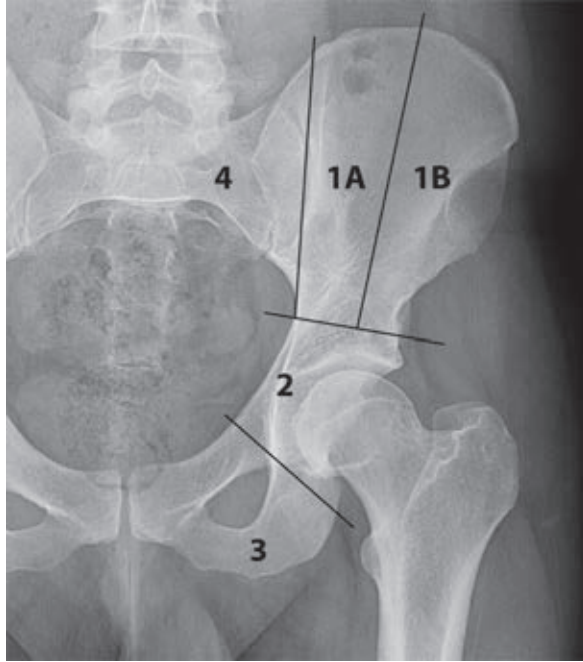


Figure 2C.

**Figures 2A-C.** Clinical images taken 3.5 years post-operatively of patient 3. Figure 2a – anteroposterior radiograph showing the position of the pedestal cup in the ilium. Figure 2b and 2c – CT images in the frontal plane, (b) through the pedestal cup and (c) in the sagittal plane, through the pedestal cup.

The ilium was prepared by drilling over the K-wire and this was followed by gradual reaming. Two grooves were created for the anti-rotation wings and a trial stem was introduced. After checking anteversion and inclination, the definitive stem was implanted with its tip close to the sacroiliac joint. When necessary, a

MUTARS attachment tube (implantcast, Buxtehude, Germany) was used to prevent dislocation (figure 4)<sup>21</sup>.



**Figure 3.** Modified version of Enneking's classification<sup>2</sup> of pelvic resections. Resections of the ilium (type 1) are further subdivided into type 1A (those involving the medial part of the ilium) and type 1B (those confined to the lateral portion of the iliac wing). The pedestal cup is inserted in the medial part of the ilium, where the cortices have a straight shape and hence provide a good fit for the implant.

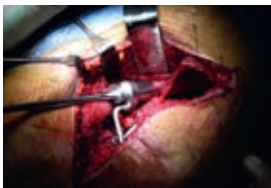

Figure 4A.

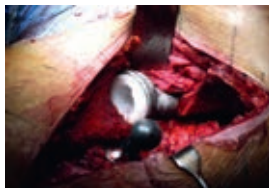

Figure 4B.

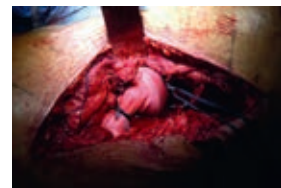

Figure 4C.

**Figures 4A-C.** Photographs of the surgical procedure of reconstructing the pelvic defect with the pedestal cup showing a) after drilling over the Kirschner wire, the ilium is reamed, b) situation after implantation of the pedestal cup and placement of the polyethylene insert and c) soft-tissue reconstruction with the MUTARS attachment tube.

The medical records of each patient were used to obtain demographic details, the indication for surgery, adjuvant therapies, details of the reconstruction, surgical margins, complications and reoperations. Radiological images were used to assess for signs of loosening, dislocation and fracture. Failure was defined as (partial) removal of the construct, with the exception of revision of the acetabular component. Complications were classified according to Henderson *et al*<sup>22</sup>. The Musculoskeletal Tumor Society (MSTS) score<sup>23</sup> and the Dutch language version of the Short Form (SF)-36<sup>24</sup> questionnaires were used to evaluate functional outcome and quality of life. For quality of life, norm-based outcome scores are presented on the physical and mental component scales<sup>25</sup>.

Survival is presented as Kaplan–Meier curves and compared between groups with log-rank tests. Factors of influence on functional outcome were compared with Mann–Whitney U tests. SPSS v20.0 software (IBM Corp., Armonk, New York) was used for statistical analysis, with the level of significance at a p-value < 0.05.

## Results

At final review, seven patients had died (one due to an acute cardiovascular event), after a mean of 39 months (28 days to 8.7 years). The 12 surviving patients (11 free of disease) had a mean follow-up of 7.9 years (4.3 to 10.5). Most patients had undergone type 2/3 resections (n = 14): the medial part of the ilium was preserved in every patient. In one patient, a two-stage procedure had been performed. Adequate surgical margins were obtained in 14 patients (ten wide, four marginal). Two patients, both with a chondrosarcoma, had focally contaminated margins (one of whom was continuously disease-free at 10.5 years follow-up). Three patients, all with metastatic carcinoma, had intended intralesional excisions.

A variety of femoral components were used. Most had standard total hip prostheses, either cemented (n = 6) or uncemented (n = 6). Five patients (four of whom had undergone previous surgery) had a MUTARS proximal femoral replacement (implantcast) and two patients had a CUT femoral neck prosthesis (Orthodynamics, Lübeck, Germany). MUTARS attachment tubes were used in 15 patients. The iliac stem was cemented in two patients because of extensive cortical destruction. Partial resection of the iliopsoas muscle was required in three patients. One patient had permanent loss of function of the lateral femoral cutaneous nerve, in three patients the obturator nerve was sacrificed.

One or more complications occurred in 15 patients. There were seven mechanical and 11 non-mechanical complications. We were unable to identify any risk factor which was significantly associated with the occurrence of complications.

Type I complications<sup>22</sup> (dislocation) occurred in five patients, after a mean of 18.5 months (17 days to 8.5 years). Three patients experienced recurrent dislocations. Of these, two had type 2/3 resections and two had MUTARS attachment tubes in place. Two patients required open reduction, one of whom subsequently underwent revision of the acetabular component.

Type II complications<sup>22</sup> (aseptic loosening) were diagnosed in three patients, after a mean of 19 months (16 to 24). The construct was reinforced by percutaneous bone cement injection in one patient. No attempt was made to reinforce or revise the other constructs, either because of a poor prognosis or because of a lack of remaining bone stock.

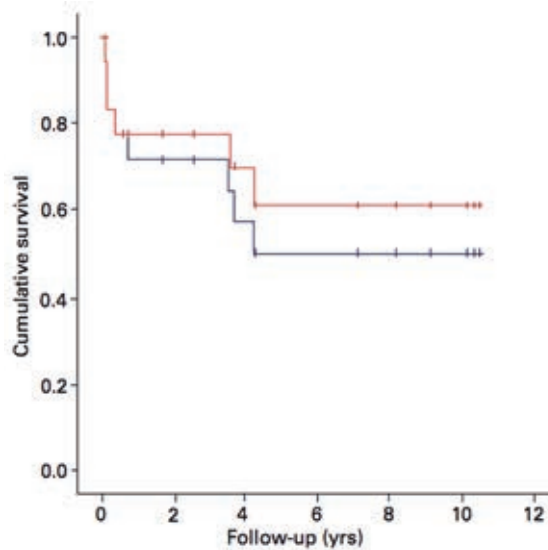
Type III complications<sup>22</sup> (structural) occurred in four patients; they had undisplaced crack fractures of the remaining ilium during implantation of the stem. All healed uneventfully.

Type IV complications<sup>22</sup> (infection) occurred in nine patients, six of whom required removal of the pedestal cup. The final outcomes of these patients included revision to a LUMiC prosthesis (implantcast) in two, a type BII rotationplasty<sup>26</sup> in one and a hindquarter amputation in one. In the remaining patients, no attempts were made to reconstruct the defect, either because of a lack of remaining bone stock or poor prognosis.

Type V complications<sup>22</sup> (tumor progression) occurred in four patients: local recurrence and lung metastases were each diagnosed three times. Two local recurrences resulted in hindquarter amputation.

The prosthesis was removed in eight patients after a mean of 19 months (29 days to 4.2 years). None failed for mechanical (type I/II/III) reasons. For all reasons, the estimated two- and five-year survival rates were 72% and 50%. For non-oncological reasons, these were 78% and 61%, respectively (figure 5). Survival of the prosthesis was significantly worse for patients with an infection (log rank,  $p = 0.008$ ).

The median postoperative hospital stay was 13 days (IQR 11 days to 6.6 weeks); all patients were able to walk postoperatively. A total of 13 patients had one or more further operations: the total number of secondary procedures was 85. In all, 59 reoperations (69%) were performed in the first postoperative year, 69 (82%) for infection or wound problems. Four patients, all with a deep infection, underwent ten or more reoperations and accounted for 59 (69%) of all reoperations.



**Figure 5.** Kaplan–Meier curve for survival of the implant, displaying survival of the construct for all reasons (blue line) and survival for non-oncological reasons (red line).

We obtained MSTS and SF-36 scores for the ten patients who were alive at final follow-up. Their mean MSTS score was 49% (13 to 87) and was significantly worse for patients in whom complications occurred (Mann–Whitney,  $p = 0.02$ ). The mean physical and mental component scale scores of the SF-36 were 56 (39 to 68) and 47 (23 to 62), respectively. One patient used codeine as an analgesic on a daily basis, nine years after the index procedure.

## Discussion

Reconstructing a functional, pain-free limb after periacetabular resection is demanding. Although experiences with the pedestal cup in both revision hip arthroplasty and orthopaedic oncology have previously been described<sup>27–29</sup>, this is the first study which reports its use in a consecutive series of patients with a pelvic malignancy.

The complication rate was high with 15 patients (79%) affected. Seven had mechanical complications, none of which required removal of the prosthesis. Failure of the reconstruction occurred in eight patients, six owing to infection and two to recurrent disease. With failure for non-oncological reasons as the end-point,

implant survival at two and five years was 78% and 61%. At final follow-up, limb salvage had been achieved in 15 patients, of whom 13 had a functional limb.

Adequate margins were obtained in most of the patients treated for a primary tumour. Three patients (16%) had a local recurrence and 12 (75%) were alive at final review. This is in accordance with other reports<sup>16</sup>.

Recurrent dislocations occurred in three patients (16%). This is in line with previous studies which report dislocations in 12% to 22%. Aseptic loosening also occurred in three patients (16%). This compares unfavorably with other reports, in which loosening of the pelvic component occurred in 3% to 15%<sup>3,4,8,16,17,19</sup>. None of our reconstructions failed for mechanical reasons. However, for two patients with loosening of the stem we elected to undertake no further treatment.

Our overall complication rate (79%, including type V<sup>22</sup>) compares unfavorably with previous reports on endoprosthetic reconstruction of periacetabular defects which describe complications in 37% to 75% of patients (table 1). Unfortunately, there are difficulties when comparing studies of periacetabular endoprotheses, one of which is the limited number of patients. More important is the lack of sufficient (long-term) follow-up in nearly all series (table 1). Major complications of pelvic resection and subsequent reconstruction (including aseptic loosening, dislocation and local recurrences), can occur years after surgery. As these complications may need extensive treatment, the published short-term measurements may not only misjudge the long-term rates of complication, but also the functional outcome. Hence, caution is urged when comparing different devices based on short-term results.

We suggest that modification of the implant could help to improve clinical results. Rates of mechanical complication may be reduced in various ways. First, the acetabular shell-stem angle is fixed in the pedestal cup prosthesis, and the implant lacks the option to adjust the orientation of the acetabular component after the stem has been inserted. We believe that the position of the acetabular component is an important determinant for the risk of dislocation and for functional outcome. Second, because of its size, the pedestal cup is unsuitable for reconstruction of the pelvis when only a small portion of the ilium remains. Therefore, a modular device with different sizes and the ability to adjust the orientation of the component seems desirable. Thirdly, hydroxyapatite coating of the stem may enhance bone ingrowth and reduce the risk of loosening.<sup>30</sup>

Infection remains of major concern in orthopaedic oncology, despite taking numerous precautions including the routine administration of systemic antibiotics. Possible reasons for the high rate of infection include the duration of surgery, the



presence of malignant disease, the anatomical region involved and, in some cases, age and pre-existing implants<sup>31</sup>. It seems that most risk factors are unalterable and it is therefore conceivable that the rate of infection will remain high.

Modifications of the device, and changes in reconstructive technique, may help reduce the rate of infection. Favorable reports on the silver coating of endoprotheses have been presented by Gosheger *et al*<sup>32</sup>, who described a lower rate of infection for silver-coated prostheses in a rabbit study. In another study, they reported that no toxicological side-effects occurred in 20 patients, but long-term results are still lacking<sup>33</sup>. Fisher *et al*<sup>4</sup> reported on 27 patients with cemented 'ice-cream cone' endoprosthetic reconstructions after resection of a periacetabular tumor. Although follow-up was limited, only three infections were seen, and all were successfully treated by surgical debridement and the administration of systemic antibiotics. The authors stated that one of the key features was the large volume of antibiotic-laden (gentamicin, vancomycin) bone cement applied around the prosthesis. This was believed to result in a high concentration of antibiotics around the prosthesis, thus not only minimising the risk of infection, but also allowing effective control if it occurs.

The functional outcome scores for reconstruction of a periacetabular defect show considerable variation. Our functional outcome scores are comparable with some previous reports<sup>8,19,34</sup>, but compare unfavorably with those of more recently published studies<sup>34</sup>. However, in the latter studies, follow-up was rather short. Only one of our patients used analgesics on a daily basis. Most authors have not reported analgesic usage, but Aljassir *et al*<sup>8</sup> noted that 27 of their patients with a saddle prosthesis (Waldemar-Link, Hamburg, Germany) used narcotics on a daily basis.

Despite the rather poor functional results, the SF-36 physical component scores were higher than those of age- and gender-matched controls. This might be explained by the fact that it reflects patients' perception of function, rather than their real function. It suggests that patients with an orthopaedic pelvic malignancy cope relatively well with impaired function after this type of extensive surgery. The mental component scores seem to confirm this.

Our study has a number of limitations including the limited number of patients. There was a wide range in follow-up, mainly due to rapid progression of disease which could mean that presented rates of complication underestimate the genuine long-term rates. This is however inherent to retrospective studies on patients with aggressive malignancies.



In conclusion, we report high rates of complication in the mid- to long-term for pelvic reconstructions using the pedestal cup. Based on these results, we advise caution in the use of this implant for reconstruction of a periacetabular defect after resection of a pelvic tumor. Most published data on endoprosthetic reconstruction of periacetabular defects are derived from small studies with limited follow-up. This makes it difficult to compare different techniques. Nevertheless, promising results have been presented in more recent literature, suggesting that other prostheses may be more successful but these too require long-term surveillance to be confident of the outcome.

Table I. Details of previous reports on endoprosthetic reconstruction of peri-acetabular defects.

Author (year)	No. of patients	Follow-up*	Prosthesis used	Indications	Overall complications	Infection	Dislocation	Aseptic loosening	Local recurrence	Functional outcome
Jaiswal et al (2008) <sup>16</sup>	98	survivors 91 months (3 months to 33.5 years); deceased 33 months (2 months to 11.6 years)	Custom made (Stanmore Implants Worldwide Ltd, Stanmore, United Kingdom)	93% primary 7% metastatic	58% (including type V)	18%	20% recurrent	3% (as a reason for revision)	31%	59% (17 to 100) <sup>†</sup>
Witte et al (2009) <sup>19</sup>	40	24 months (1 to 61)	MUTARS hemipelvic endoprosthesis (implantcast, Buxtehude, Germany)	73% primary 28% metastatic	75% (including type V)	30%	3%	15%	18%	50% (SD 19) <sup>†</sup>
Guo et al (2007) <sup>34</sup>	28	30 months (10 to 59)	Modular hemipelvic endoprosthesis	86% primary 14% metastatic	39%	32%	4%	-	25%	62% (30 to 83) <sup>†</sup>
Fisher et al (2011) <sup>4</sup>	27	survivors 39 months (18 to 80) deceased mean 12 months (4 to 27)	*Ice-cream cone coned hemi-pelvis (Stanmore Implants Worldwide Ltd, Stanmore, United Kingdom)	70% primary 7% metastatic 22% failure of previous reconstruction	37% (including type V)	11%	15%	-	7%	69% (52 to 90) <sup>†</sup>
Aljassir et al (2005) <sup>8</sup>	27	45 months (3 weeks to 10 years)	Saddle prosthesis (Link, Hamburg, Germany)	100% primary	-	37%	22%	-	22%	51% (SD 22) <sup>‡</sup> 64% (SD 17) <sup>‡</sup>
Menendez et al (2009) <sup>3</sup>	25	29 months (13 to 108)	Periacetabular Reconstruction (PAR prosthesis (Stryker Howmedica, New Jersey, United States)	32% primary 68% metastatic	56% (including type V)	24%	12%	-	20%	70% (37 to 90) <sup>‡</sup>
Abouafia et al (1995) <sup>17</sup>	17	33 months (15 to 62)	Saddle prosthesis (Link, Hamburg, Germany)	47% primary 53% metastatic or systemic	53%	18%	12%	12%	-	59% 'excellent' 12% 'good' 6% 'fair' 24% 'poor'
Jansen (van de Sande and Dijkstra, 2013) <sup>5</sup>	17	survivors median 94 months (2 to 204) deceased median 36 months (2 to 58)	Saddle prosthesis (Link, Hamburg, Germany)	94% primary 6% metastatic	82% (not including type V)	53% (as a reason for failure: 18%)	18% recurrent; 24% single	-	71%	47% (20 to 77) <sup>‡</sup> 53% (4 to 67) <sup>†</sup>
Current study	19	survivors 95 months (51 months to 105 years) deceased 39 months (28 days to 8.7 years)	Pedestal Cup (Zimmer, Freiburg, Germany)	84% primary 16% metastatic	79% (including type V)	47% (as a reason for failure: 32%)	16% recurrent; 11% single	16%	16%	49% (13 to 87) <sup>†</sup>

\* Mean values, unless stated otherwise, with minimum and maximum or standard deviation (SD) in parentheses

<sup>†</sup> TESS, Toronto extremity salvage score<sup>‡</sup> MSTS, Musculoskeletal Tumor Society Score

## References

1. Grimer RJ, Chandrasekar CR, Carter SR, Abudu A, Tillman RM, Jeys L. Hindquarter amputation: is it still needed and what are the outcomes? *The bone & joint journal*. 2013 Jan;95-b(1):127-31. Epub 2013/01/12.
2. Enneking WF, Dunham WK. Resection and reconstruction for primary neoplasms involving the innominate bone. *The Journal of bone and joint surgery American volume*. 1978 Sep;60(6):731-46. Epub 1978/09/01.
3. Menendez LR, Ahlmann ER, Falkinstein Y, Allison DC. Periacetabular reconstruction with a new endoprosthesis. *Clinical orthopaedics and related research*. 2009 Nov;467(11):2831-7. Epub 2009/08/21.
4. Fisher NE, Patton JT, Grimer RJ, Porter D, Jeys L, Tillman RM, et al. Ice-cream cone reconstruction of the pelvis: a new type of pelvic replacement: early results. *The Journal of bone and joint surgery British volume*. 2011 May;93(5):684-8. Epub 2011/04/23.
5. Jansen JA, van de Sande MA, Dijkstra PD. Poor long-term clinical results of saddle prosthesis after resection of periacetabular tumors. *Clinical orthopaedics and related research*. 2013 Jan;471(1):324-31. Epub 2012/10/12.
6. Delloye C, Banse X, Brichard B, Docquier PL, Cornu O. Pelvic reconstruction with a structural pelvic allograft after resection of a malignant bone tumor. *The Journal of bone and joint surgery American volume*. 2007 Mar;89(3):579-87. Epub 2007/03/03.
7. Sys G, Uyttendaele D, Poffyn B, Verdonk R, Verstraete L. Extracorporeally irradiated autografts in pelvic reconstruction after malignant tumour resection. *International orthopaedics*. 2002;26(3):174-8. Epub 2002/06/20.
8. Aljassir F, Beadel GP, Turcotte RE, Griffin AM, Bell RS, Wunder JS, et al. Outcome after pelvic sarcoma resection reconstructed with saddle prosthesis. *Clinical orthopaedics and related research*. 2005 Sep;438:36-41. Epub 2005/09/01.
9. Fuchs B, O'Connor MI, Kaufman KR, Padgett DJ, Sim FH. Iliofemoral arthrodesis and pseudarthrosis: a long-term functional outcome evaluation. *Clinical orthopaedics and related research*. 2002 Apr(397):29-35. Epub 2002/04/16.
10. Beadel GP, McLaughlin CE, Wunder JS, Griffin AM, Ferguson PC, Bell RS. Outcome in two groups of patients with allograft-prosthetic reconstruction of pelvic tumor defects. *Clinical orthopaedics and related research*. 2005 Sep;438:30-5. Epub 2005/09/01.
11. Ozaki T, Hillmann A, Bettin D, Wuisman P, Winkelmann W. High complication rates with pelvic allografts. Experience of 22 sarcoma resections. *Acta orthopaedica Scandinavica*. 1996 Aug;67(4):333-8. Epub 1996/08/01.
12. Bell RS, Davis AM, Wunder JS, Buconjic T, McGoveran B, Gross AE. Allograft reconstruction of the acetabulum after resection of stage-IIIb sarcoma. Intermediate-term results. *The Journal of bone and joint surgery American volume*. 1997 Nov;79(11):1663-74. Epub 1997/12/31.
13. Hoffmann C, Gosheger G, Gebert C, Jurgens H, Winkelmann W. Functional results and quality of life after treatment of pelvic sarcomas involving the acetabulum. *The Journal of bone and joint surgery American volume*. 2006 Mar;88(3):575-82. Epub 2006/03/03.
14. Ozaki T, Hoffmann C, Hillmann A, Gosheger G, Lindner N, Winkelmann W. Implantation of hemipelvic prosthesis after resection of sarcoma. *Clinical orthopaedics and related research*. 2002 Mar(396):197-205. Epub 2002/02/23.
15. Bruns J, Luessenhop SL, Dahmen G, Sr. Internal hemipelvectomy and endoprosthetic pelvic replacement: long-term follow-up results. *Archives of orthopaedic and trauma surgery*. 1997;116(1-2):27-31. Epub 1997/01/01.
16. Jaiswal PK, Aston WJ, Grimer RJ, Abudu A, Carter S, Blunn G, et al. Peri-acetabular resection and endoprosthetic reconstruction for tumours of the acetabulum. *The Journal of bone and joint surgery British volume*. 2008 Sep;90(9):1222-7. Epub 2008/09/02.
17. Aboulafia AJ, Buch R, Mathews J, Li W, Malawer MM. Reconstruction using the saddle prosthesis following excision of primary and metastatic periacetabular tumors. *Clinical orthopaedics and related research*. 1995 May(314):203-13. Epub 1995/05/01.

18. Angelini A, Drago G, Trovarelli G, Calabro T, Ruggieri P. Infection after surgical resection for pelvic bone tumors: an analysis of 270 patients from one institution. *Clinical orthopaedics and related research*. 2014 Jan;472(1):349-59. Epub 2013/08/27.
19. Witte D, Bernd L, Bruns J, Gosheger G, Harges J, Hartwig E, et al. Limb-salvage reconstruction with MUTARS hemipelvic endoprosthesis: a prospective multicenter study. *European journal of surgical oncology : the journal of the European Society of Surgical Oncology and the British Association of Surgical Oncology*. 2009 Dec;35(12):1318-25. Epub 2009/05/30.
20. Enneking WF, Spanier SS, Goodman MA. A system for the surgical staging of musculoskeletal sarcoma. *Clinical orthopaedics and related research*. 1980 Nov-Dec(153):106-20. Epub 1980/11/01.
21. Gosheger G, Hillmann A, Lindner N, Rodl R, Hoffmann C, Burger H, et al. Soft tissue reconstruction of megaprotheses using a trevira tube. *Clinical orthopaedics and related research*. 2001 Dec(393):264-71. Epub 2002/01/05.
22. Henderson ER, Groundland JS, Pala E, Dennis JA, Wooten R, Cheong D, et al. Failure mode classification for tumor endoprosthesis: retrospective review of five institutions and a literature review. *The Journal of bone and joint surgery American volume*. 2011 Mar 2;93(5):418-29. Epub 2011/03/04.
23. Enneking WF, Dunham W, Gebhardt MC, Malawar M, Pritchard DJ. A system for the functional evaluation of reconstructive procedures after surgical treatment of tumors of the musculoskeletal system. *Clinical orthopaedics and related research*. 1993 Jan(286):241-6. Epub 1993/01/01.
24. Aaronson NK, Muller M, Cohen PD, Essink-Bot ML, Fekkes M, Sanderman R, et al. Translation, validation, and norming of the Dutch language version of the SF-36 Health Survey in community and chronic disease populations. *Journal of clinical epidemiology*. 1998 Nov;51(11):1055-68. Epub 1998/11/17.
25. Ware JE, Jr., Kosinski M, Bayliss MS, McHorney CA, Rogers WH, Raczek A. Comparison of methods for the scoring and statistical analysis of SF-36 health profile and summary measures: summary of results from the Medical Outcomes Study. *Medical care*. 1995 Apr;33(4 Suppl):As264-79. Epub 1995/04/01.
26. Winkelmann WW. Rotationplasty. *The Orthopedic clinics of North America*. 1996 Jul;27(3):503-23. Epub 1996/07/01.
27. Schoellner C, Schoellner D. [Pedestal cup operation in acetabular defects after hip cup loosening. A progress report]. *Zeitschrift fur Orthopadie und ihre Grenzgebiete*. 2000 May-Jun;138(3):215-21. Epub 2000/08/10.
28. Perka C, Schneider F, Labs K. Revision acetabular arthroplasty using a pedestal cup in patients with previous congenital dislocation of the hip - four case reports and review of treatment. *Archives of orthopaedic and trauma surgery*. 2002 May;122(4):237-40. Epub 2002/05/25.
29. Dominkus M, Darwish E, Funovics P. Reconstruction of the pelvis after resection of malignant bone tumours in children and adolescents. Recent results in cancer research *Fortschritte der Krebsforschung Progres dans les recherches sur le cancer*. 2009;179:85-111. Epub 2009/02/24.
30. Kelly SJ, Incavo SJ, Beynon B. The use of a hydroxyapatite-coated primary stem in revision total hip arthroplasty. *The Journal of arthroplasty*. 2006 Jan;21(1):64-71. Epub 2006/02/01.
31. Gradl G, de Witte PB, Evans BT, Hornicek F, Raskin K, Ring D. Surgical site infection in orthopaedic oncology. *The Journal of bone and joint surgery American volume*. 2014 Feb 5;96(3):223-30. Epub 2014/02/07.
32. Gosheger G, Harges J, Ahrens H, Streitburger A, Buerger H, Erren M, et al. Silver-coated megaendoprosthesis in a rabbit model--an analysis of the infection rate and toxicological side effects. *Biomaterials*. 2004 Nov;25(24):5547-56. Epub 2004/05/15.
33. Harges J, Ahrens H, Gebert C, Streitburger A, Buerger H, Erren M, et al. Lack of toxicological side-effects in silver-coated megaprotheses in humans. *Biomaterials*. 2007 Jun;28(18):2869-75. Epub 2007/03/21.
34. Guo W, Li D, Tang X, Yang Y, Ji T. Reconstruction with modular hemipelvic prostheses for periacetabular tumor. *Clinical orthopaedics and related research*. 2007 Aug;461:180-8. Epub 2007/04/25.1.



# Chapter 4

## **LUMiC® Endoprosthetic Reconstruction After Periacetabular Tumor Resection: Short-term Results**

M.P.A. Bus<sup>1</sup>

A. Szafranski<sup>2</sup>

S. Sellevold<sup>3</sup>

T. Goryn<sup>4</sup>

P.C. Jutte<sup>5</sup>

J.A.M. Bramer<sup>6</sup>

M. Fiocco<sup>1, 7</sup>

A. Streitbürger<sup>8</sup>

D. Kotrych<sup>9</sup>

M.A.J. van de Sande<sup>1</sup>

P.D.S. Dijkstra<sup>1</sup>

<sup>1</sup>Leiden University Medical Center, Leiden, the Netherlands; <sup>2</sup>Institute of Mother & Child, Warsaw, Poland; <sup>3</sup>Oslo University Hospital, Oslo, Norway; <sup>4</sup>Maria Skłodowska-Curie Memorial Cancer Center and Institute of Oncology, Warsaw, Poland; <sup>5</sup>University Medical Center Groningen, Groningen, the Netherlands; <sup>6</sup>Academic Medical Center, Amsterdam, the Netherlands; <sup>7</sup>Mathematical Institute, Leiden University, Leiden, the Netherlands; <sup>8</sup>Universitätsklinikum Münster, Münster, Germany; <sup>9</sup>Pomeranian Medical University, Szczecin, Poland

## Abstract

**Background:** Reconstruction of periacetabular defects after pelvic tumor resection ranks among the most challenging procedures in orthopaedic oncology, and reconstructive techniques are generally associated with dissatisfying mechanical and non-mechanical complication rates. In an attempt to reduce the risk of dislocation, aseptic loosening, and infection, we introduced the LUMiC prosthesis (implantcast, Buxtehude, Germany) in 2008. The LUMiC prosthesis is a modular device, built of a separate stem (hydroxyapatite-coated uncemented or cemented) and acetabular cup. The stem and cup are available in different sizes (the latter of which is also available with silver coating for infection prevention) and are equipped with sawteeth at the junction to allow for rotational adjustment of cup position after implantation of the stem. Whether this implant indeed is durable at short-term follow-up has not been evaluated.

**Questions/purposes:** (1) What proportion of patients experience mechanical complications and what are the associated risk factors of periacetabular reconstruction with the LUMiC after pelvic tumor resection? (2) What proportion of patients experience non-mechanical complications and what are the associated risk factors of periacetabular reconstruction with the LUMiC after pelvic tumor resection? (3) What is the cumulative incidence of implant failure at 2 and 5 years and what are the mechanisms of reconstruction failure? (4) What is the functional outcome as assessed by Musculoskeletal Tumor Society (MSTS) score at final follow-up?

**Methods:** We performed a retrospective chart review of every patient in whom a LUMiC prosthesis was used to reconstruct a periacetabular defect after internal hemipelvectomy for a pelvic tumor from July 2008 to June 2014 in eight centers of orthopaedic oncology with a minimum follow-up of 24 months. Forty-seven patients (26 men [55%]) with a mean age of 50 years (range, 12 – 78 years) were included. At review, 32 patients (68%) were alive. The reverse Kaplan-Meier method was used to calculate median follow-up, which was equal to 3.9 years (95% confidence interval [CI], 3.4 – 4.3). During the period under study, our general indications for using this implant were reconstruction of periacetabular defects after pelvic tumor resections in which the medial ilium adjacent to the sacroiliac



joint was preserved; alternative treatments included hip transposition and saddle or custom-made prostheses in some of the contributing centers; these were generally used when the medial ilium was involved in the tumorous process or if the LUMiC was not yet available in the specific country at that time. Conventional chondrosarcoma was the predominant diagnosis (n = 22 [47%]); five patients (11%) had osseous metastases of a distant carcinoma and three (6%) had multiple myeloma. Uncemented fixation (n = 43 [91%]) was preferred. Dual-mobility cups (n = 24 [51%]) were mainly used in case of a higher presumed risk of dislocation in the early period of our study; later, dual-mobility cups became the standard for the majority of the reconstructions. Silver-coated acetabular cups were used in 29 reconstructions (62%); because only the largest cup size was available with silver coating, its use depended on the cup size that was chosen. We used a competing risk model to estimate the cumulative incidence of implant failure.

**Results:** Six patients (13%) had a single dislocation; four (9%) had recurrent dislocations. The risk of dislocation was lower in reconstructions with a dual-mobility cup (one of 24 [4%]) than in those without (nine of 23 [39%]) (hazard ratio, 0.11; 95% CI, 0.01 – 0.89; p = 0.038). Three patients (6%; one with a preceding structural allograft reconstruction, one with poor initial fixation as a result of an intraoperative fracture, and one with a cemented stem) had loosening and underwent revision. Infections occurred in 13 reconstructions (28%). Median duration of surgery was 6.5 hours (range, 4.0 – 13.6 hours) for patients with an infection and 5.3 hours (range, 2.8 – 9.9 hours) for those without (p = 0.060); blood loss was 2.3 L (range, 0.8 – 8.2 L) for patients with an infection and 1.5 L (range, 0.4 – 3.8 L) for those without (p = 0.039). The cumulative incidences of implant failure at 2 and 5 years were 2.1% (95% CI, 0 – 6.3) and 17.3% (95% CI, 0.7 – 33.9) for mechanical reasons and 6.4% (95% CI, 0 – 13.4) and 9.2% (95% CI, 0.5 – 17.9) for infection, respectively. Reasons for reconstruction failure were instability (n = 1 [2%]), loosening (n = 3 [6%]), and infection (n = 4 [9%]). Mean MSTs functional outcome score at follow-up was 70% (range, 33%–93%).

**Conclusions:** At short-term follow-up, the LUMiC prosthesis demonstrated a low frequency of mechanical complications and failure when used to reconstruct the acetabulum in patients who underwent major pelvic tumor resections, and we believe this is a useful reconstruction for periacetabular resections for tumor or

failed prior reconstructions. Still, infection and dislocation are relatively common after these complex reconstructions. Dual-mobility articulation in our experience is associated with a lower risk of dislocation. Future, larger studies will need to further control for factors such as dual-mobility articulation and silver coating. We will continue to follow our patients over the longer term to ascertain the role of this implant in this setting.

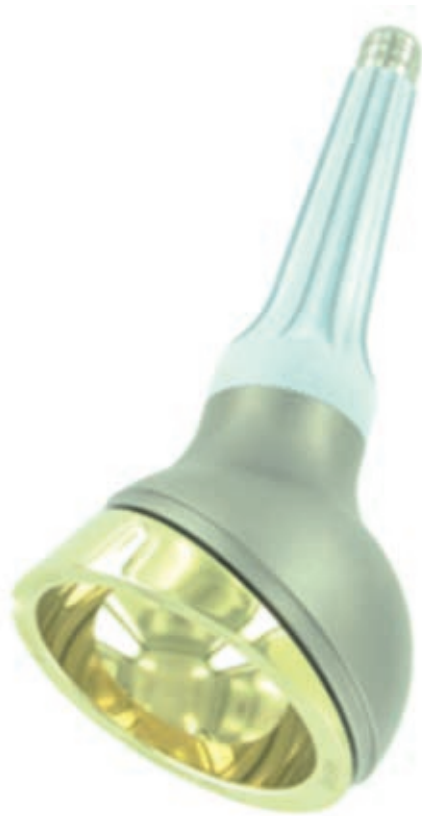## Introduction

Surgical treatment of pelvic bone tumors continues to pose a challenge to the orthopaedic oncology community. Traditionally, pelvic tumors were resected by means of hindquarter amputation, a procedure associated with detrimental cosmetic, physical, and psychological outcomes<sup>1</sup>. At present, the majority of patients can be treated with limb-salvaging internal hemipelvectomies<sup>1, 2</sup>. Complications nevertheless remain frequent, especially for resections comprising the periacetabulum (Enneking type 2 or type 2–3)<sup>3–5</sup>, and for large tumors, which are common in this location because pelvic tumors regularly attain large sizes before diagnosis. Procedures in this location also can be complicated by inadequate margins and, because the procedures are long, infection<sup>6,7</sup>.

Apart from tumor resection, obtaining a well-functioning reconstruction is challenging. As a result of the frequently massive extent of bone and soft tissue resection, the reconstructions are typically exposed to high biomechanical stresses. Reconstructive techniques remain a topic of debate; various biological, mechanical, and combined techniques have been advocated<sup>8–11</sup>. Disadvantages of biological reconstruction using allografts, include the high risk of infection, nonunion, and graft resorption<sup>12</sup>. Many authors therefore consider endoprosthetic replacement a better solution to achieve satisfactory and durable functional and cosmetic results<sup>6, 13, 14</sup>. Several new implants have been introduced during recent decades, including custom-made, saddle, and “inverted ice cream cone” or “pedestal cup” prostheses<sup>6, 9, 13, 15–17</sup>. Most of these have been associated with a disappointing frequency of mechanical complications and failures, especially in the long term, including (recurrent) dislocations (3% – 24%), aseptic loosening (3% – 15%), cranial migration, heterotopic ossification, and periprosthetic or prosthetic fractures<sup>9, 12, 13, 15, 17, 18</sup>. However, adequately comparing different techniques is difficult because most published results are derived from single-center case series with limited patient numbers.

In the leading center of the current study, a pedestal cup prosthesis (Zimmer, Freiburg, Germany) was used for periacetabular reconstruction between 2003 and 2008<sup>9</sup>. We encountered frequent complications, but considered the basic concept behind the implant suitable because it allows for relatively easy, quick, and durable fixation. Moreover, it allows for pelvic reconstruction even if only the medial ilium remains. We theorized that modification of the implant would aid to reduce complication rates and incorporated these ideas in the design of the LUMiC

(implantcast, Buxtehude, Germany). The LUMiC prosthesis is a modular device, built of a separate stem (hydroxyapatite [HA]-coated uncemented or cemented) and acetabular cup (figure 1). The stem and cup are available in different sizes (the latter of which is also available with silver coating for infection prevention) and are equipped with sawteeth at the junction to allow for rotational adjustment of cup position after implantation of the stem. We hypothesized that aforementioned features would lead to a lower risk of aseptic loosening, dislocation, and infection and better restoration of lower limb function. The current study was initiated to evaluate the short-term clinical results of this implant.

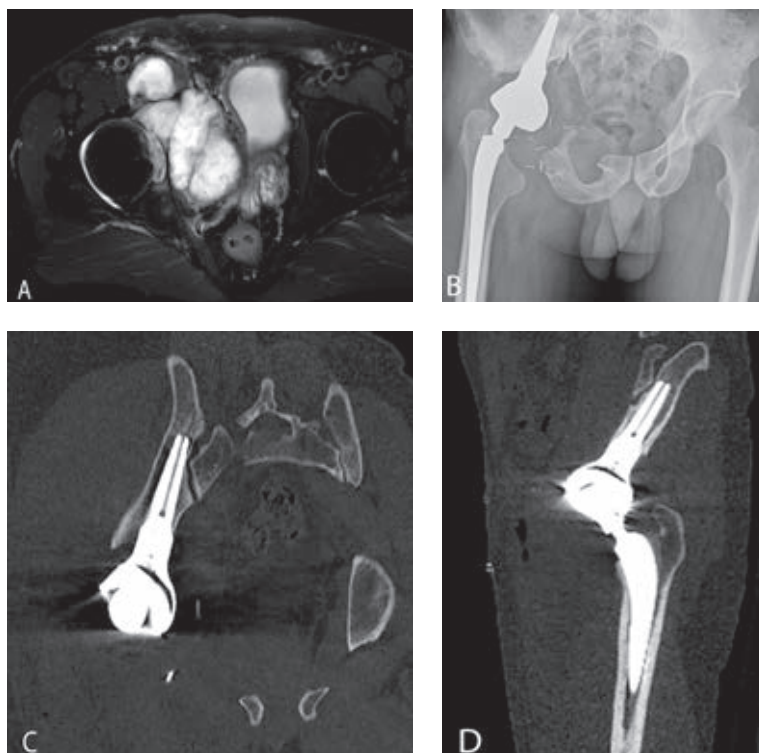


**Figure 1.** The LUMiC prosthesis consists of a separate cup and stem, both available in different sizes and with different coatings (reproduced with permission from implantcast).

Specifically, we asked: (1) What proportion of patients experience mechanical complications and what are the associated risk factors of periacetabular reconstruction with the LUMiC after pelvic tumor resection? (2) What proportion of patients experience non-mechanical complications and what are the associated risk factors of periacetabular reconstruction with the LUMiC after pelvic tumor resection? (3) What is the cumulative incidence of implant failure at two and five years and what are the mechanisms of reconstruction failure? (4) What is the functional outcome as assessed by Musculoskeletal Tumor Society (MSTS) score at final follow-up?

## Materials and Methods

Longitudinally maintained institutional registries were reviewed in eight centers of orthopaedic oncology to identify patients who underwent reconstruction with the LUMiC after periacetabular hemipelvectomy for a pelvic tumor. We reviewed every patient in whom this implant was used for this indication from July 2008 to June 2014 with a minimum follow-up of 24 months. The LUMiC was the preferred technique for reconstruction of pelvic defects after *en bloc* resection of a periacetabular tumor in all centers during the period under study. Alternative treatments included hip transposition and saddle or custom-made prostheses in some centers; these were generally used when the medial ilium was involved in the tumorous process or if the LUMiC was not yet available in the specific country at that time. Our general indications for using the LUMiC were reconstruction of periacetabular defects after pelvic tumor resections in which the medial ilium (adjacent to the sacroiliac joint, part 1A according to a modified version of Enneking's classification<sup>9</sup>) was preserved, allowing the stem to be properly inserted (the conical stem is designed to seat between the anterior and posterior cortices of the medial part of the iliac wing, adjacent to the sacroiliac joint [figure 2]).



**Figures 2A-D.** (A) Case discussion of a 44-year-old male patient. T2-weighted MR image in the transverse plane shows a bulky mass, originating in the right acetabulum and infiltrating the hip joint. CT-guided biopsy showed a grade 2 chondrosarcoma. (B) Conventional radiograph displaying the situation after type 2–3 internal hemipelvectomy and subsequent reconstruction. Reconstruction was performed with an uncemented LUMiC stem (75 mm long, 10-mm core diameter), a 54-mm outer diameter HA-coated cup, and an uncemented Mallory-Head total hip prosthesis (Biomet, Warsaw, IN, USA) with a 28-mm femoral head. (C) CT scan displaying the position of the LUMiC stem in the coronal plane with its tip close to the sacroiliac joint. (D) CT scan displaying the position of the LUMiC stem in the sagittal plane.

Forty-seven patients (26 males [55%]) with a mean age of 50 years (range, 12 – 78 years) were included (table 1). At review, 32 patients (68%) were alive and 15 (32%) had died (nine of disease). Two patients with a metastatic tumor were referred to their local hospital and died within two years. The contributing center checked with their local hospital; no revisions or reoperations were undertaken before they died. One patient was lost to follow-up before two years and was excluded. The reverse Kaplan-Meier method was used to calculate median follow-up, which was equal to 3.9 years (95% confidence interval [CI], 3.4 – 4.3).

Fifteen patients were treated in center 1; other centers had seven, six, five, four, four, four, and two patients, respectively. The indication for pelvic resection was a primary bone tumor in 38 patients (81%; predominantly conventional

chondrosarcoma; n = 22 [47%]), osseous metastases of distant carcinoma in five (11%), multiple myeloma with acetabular destruction in three (6%), and acetabular metastases of a previously resected femoral osteosarcoma in one (2%). Whether patients with metastatic disease were candidates for a pelvic resection and prosthetic reconstruction depended on the extent of acetabular destruction, patient prognosis (based on tumor type, Karnofsky performance score, and the presence of visceral or brain metastases), and morbidity. The technical feasibility of a limb-salvaging resection and subsequent reconstruction was assessed in multidisciplinary teams preoperatively.

The resections were type 2 in 21 patients (45%) and type 2–3 in 26 (55%). Twenty patients (43%) had an extra-articular resection. Nine patients (19%) had surgery before the LUMiC reconstruction, including three pedestal cup reconstructions (6%; all had failed as a result of infection) and two allograft reconstructions (4%; one failed as a result of graft resorption, one as a result of local recurrence) (table 1).

**Table 1.** Study data

Variable	Number	Percent
<i>Sex</i>		
Male	26	55
Female	21	45
<i>Indications for primary resection</i>		
Chondrosarcoma grade 2 or 3	13	28
Metastatic carcinoma	5	11
Osteosarcoma	5	11
Ewing's sarcoma	4	9
Chondrosarcoma grade 1	4	9
Multiple myeloma	3	6
Pleomorphic undifferentiated sarcoma	1	2
Sarcoma not otherwise specified	1	2
Phosphaturic mesenchymal tumor	1	2
<i>Indications for revision procedures (original diagnosis in parentheses)</i>		
Pedestal cup reconstruction (two grade 2 chondrosarcomas, one clear cell chondrosarcoma)	3	6
THA (grade 2 chondrosarcoma)	1	2
Internal hemipelvectomy (P2) reconstructed with massive pelvic allograft and THA (grade 2 chondrosarcoma)	1	2
Total femoral replacement (osteosarcoma)	1	2
THA and Müller cage (chondroblastoma)	1	2
Partial resection of iliac wing (P1) (dedifferentiated chondrosarcoma)	1	2
Partial resection of periacetabulum (P2) reconstructed with femoral head interposition (grade 2 chondrosarcoma)	1	2

**Table 1.** continued

Variable	Number	Percent
<i>Resection type (Enneking classification)</i>		
Type 2-3	26	55
Type 2	21	45
<i>Neoadjuvant and adjuvant therapies</i>		
Neoadjuvant chemotherapy	17	36
Adjuvant chemotherapy	12	26
Neoadjuvant radiotherapy	7	15
Adjuvant radiotherapy	10	21
<i>Surgical details</i>		
Extra-articular resections	20	43
Computer-assisted resections	12	26
MUTARS attachment tube used	16	34
<i>Complications</i>		
Dislocations, all reconstructions	10	21
Dislocations in primary dual-mobility cups (n = 24)	1	4
Structural complications	3	6
Infection	14	30
Local recurrence	5	11
<i>Failure</i>		
Any reason	8	17
<i>Status at final follow-up</i>		
No evidence of disease	29	62
Alive with disease	3	6
Dead of disease	9	19
Died of other cause	6	13

The LUMiC was designed for periacetabular reconstruction after tumor resection or extensive revision hip arthroplasty. It is a modular device built of a separate stem and cup, which are both equipped with sawteeth at the junction to allow for rotational adjustment of cup position after implantation of the stem (figure 1). The stem is hexagonally shaped and carries two additional wings to secure rotational stability. Stems are available for uncemented (TiAl6V4, HA-coated) and cemented (CoCrMo) fixation in three different lengths (65, 75, and 85 mm) and two different core diameters (8 and 10 mm, the latter only uncemented). Uncemented fixation was preferred in all centers unless bone quality was deemed insufficient or adequate press-fit fixation could not be obtained. The cups come in three different sizes (50, 54, and 60-mm outer diameter), uncoated, HA-coated, or silver-coated (only the 60-mm version). The highly crosslinked polyethylene



inserts (implacross; implantcast) are available in a neutral version and with 4-mm offset. The ACCIS liner (Accis BV, Baarn, The Netherlands) was first used in 2010 and offers the possibility of dual-mobility articulation when combined with the Polarc femoral head (implantcast).

Tumor resections were planned on an array of conventional imaging, CT, and MRI. Patients were positioned in the lateral decubitus position, allowing them to be rotated to nearly prone or supine positions. Before surgery, patients received intravenous cephalosporin antibiotics; these were usually continued for one to five days. Eighteen patients (38%) received tranexamic acid. The surgical approach and technique depended on the surgeon and tumor location. After resection, a cannulated probe was introduced in the remaining ilium; fluoroscopy or computer navigation was used to make sure the iliac cortices were not perforated. Use of computer navigation ( $n = 15$  [32%]) depended on center preferences. A Kirschner wire was inserted through the probe, after which the ilium was reamed and a trial shaft was inserted. Next, the femoral component was implanted according to appropriate procedures. The cup was connected to the trial stem and a trial reduction was performed. After assessment of reconstruction length and soft tissue tension, the definitive stem was impacted (or cemented) and the cup was connected; a second trial reduction was then performed. Attachment (Trevira) tubes (implantcast) were used to reattach soft tissues and to stimulate neocapsule formation in 16 (34%) reconstructions<sup>19</sup>. Twenty-four patients (51%) had a dual-mobility cup; these were mainly used in case of a higher presumed risk of dislocation in the early period of our study. Later, dual-mobility cups became the standard for the majority of the reconstructions. Silver-coated acetabular cups were used in 29 reconstructions (62%); its use depended on the cup size that was chosen, because only the largest cup size was available with silver coating (table 2). The iliac stem was cemented in four (9%; two multiple myelomas, one metastatic carcinoma, one chondrosarcoma). Twenty-three patients (49%) had standard hip prostheses and 23 (49%) had proximal femoral replacements; one patient (2%) had a previously implanted total femoral arthroplasty.

Adequate margins were obtained in 39 of the 41 procedures (95%) intended to achieve clear margins; tumor spill occurred in two (5%; one clear cell chondrosarcoma, one phosphaturic mesenchymal tumor). Six patients (13%) had intentional intralesional surgery (five metastatic carcinomas, one chondroblastoma).

Usually, full weight-bearing mobilization was started on the third postoperative day under supervision of a physical therapist. We used a rehabilitation protocol that is identical to that used in patients with revision hip arthroplasty. Starting from day three, partial weight-bearing with two crutches is allowed until six weeks postoperatively. Thereafter, patients start to mobilize with one crutch. We believe it is important to mobilize patients as soon as possible to lessen the likelihood of major complications such as thrombosis. In the first days of mobilization, patients exercise for one to two hours and stay in bed during the remaining hours. Median postoperative hospital stay was 16 days (range, four days to 2.8 months). Routine follow-up included physical examination and radiographic and functional evaluation at one and six weeks; at three (conventional radiographs), six (conventional radiograph and CT), 12, and 24 months (conventional radiographs, CT and MRI); and yearly thereafter (conventional radiographs, MRI).

Medical records were evaluated to obtain characteristics of the patient, tumor, resection, and reconstruction. In consultation with the leading author (MPAB), one physician involved in the care of the patients in each center collected the data. Complications were classified according to Henderson *et al*<sup>20</sup>. Aseptic loosening and periprosthetic and prosthetic fractures were diagnosed on imaging or intraoperatively. Aseptic loosening was defined as migration of the implant on conventional radiographs or CT or halo formation on CT in the absence of infection. Infection was defined as any deep (periprosthetic) infectious process diagnosed by physical examination, imaging, laboratory tests (C-reactive protein, erythrocyte sedimentation rate, leukocyte count), and microbiologic cultures. The occurrence of local recurrences was determined on imaging (usually MRI) and on histopathology in case surgery was performed. Failure was defined as removal or revision of (part of) the implant for any reason.

## Statistical Analysis

A competing risks model was used to estimate the cumulative incidence of implant failure for mechanical failure and infection with patient mortality as a competing event<sup>21, 22</sup>. A Cox regression model was used to study the effect of prognostic factors on survival. Categorical variables were compared between groups with chi-square tests and numerical variables with Mann-Whitney U tests. Outcomes are expressed in hazard ratios (HRs), 95% CIs, and p-values. Functional outcome was assessed with the 1993 version of the MSTs questionnaires<sup>23</sup> at last

follow-up; questionnaires were available for 24 patients (51%). Statistical analysis was performed using SPSS 21.0 (IBM Corp, Armonk, NY, USA) with the level of significance at  $p < 0.05$ .

**Table 2.** Details of prosthetic components

Variable	Number	Percent
<i>LUMiC stem size (uncemented, unless otherwise stated)</i>		
65 mm, 8 mm Ø	5	11
65 mm, 10 mm Ø	9	19
75 mm, 8 mm Ø	1	2
75 mm, 8 mm Ø, cemented	2	4
75 mm, 10 mm Ø	11	23
85 mm, 8 mm Ø	6	13
85 mm, 10 mm Ø	13	28
<i>LUMiC cup size (outer Ø)</i>		
50 mm	6	13
54 mm	12	26
60 mm	29	62
<i>Femoral component</i>		
Cemented	12	26
Standard total hip prosthesis	24	51
Proximal femoral replacement	22	47
Total femoral replacement	1	2
<i>Femoral head size and articulation</i>		
28 mm, dual-mobility	16	34
32 mm	2	4
32 mm, dual-mobility	1	2
36 mm	21	45
36 mm, dual-mobility	7	15

## Results

A total of 30% (14 of 47) of our patients experienced one or more mechanical complications. A single dislocation (Henderson type I) occurred in six patients (13%); four patients had recurrent dislocations (9%; one of whom sustained a first dislocation after resection of an extensive recurrence). The first dislocation occurred after a median of 20 days (range, one day to 2.6 months). Patients with a single dislocation were managed with open ( $n = 3$ ) or closed ( $n = 3$ ) reduction. Two patients with recurrent dislocations underwent revision to a dual-mobility cup with good results; no further dislocations occurred. Others were managed

with open reduction and reinforced with an attachment tube. The proportion of patients who experienced a dislocation was comparable between patients who had type 2 (five of 21 [24%]) and type 2–3 (five of 26 [19%]) resections (odds ratio [OR], 0.76; 95% CI, 0.19– 3.09;  $p = 0.703$ ). With the numbers we had we could not detect a difference in dislocation in those who had reconstructions with (two of 16 [13%]) or without (eight of 31 [26%]) attachment tubes (OR, 0.41; 95% CI, 0.08 – 2.22;  $p = 0.301$ ). The risk of dislocation was lower for patients with a dual-mobility cup (one of 24 [4%]) compared with those without (nine of 23 [39%]); consequently, dislocation-free survival was significantly better (HR, 0.11; 95% CI, 0.01 – 0.89;  $p = 0.038$ ).

Aseptic loosening (Henderson type II) occurred in three reconstructions (6%). Loosening occurred in two cases with an uncemented stem (one, 57 months after fixation in a structural pelvic allograft that had failed as a result of allograft resorption; and one, 36 months after implantation with an intraoperative fracture, which had caused insufficient primary fixation) and in one with a cemented stem.

Structural complications (Henderson type III) occurred in four patients (9%); two had periprosthetic iliac fractures (one treated conservatively with a good result, one was removed as a result of infection), two had a fracture during implantation (one is discussed previously, the fracture was treated conservatively and later failed as a result of implant loosening; one was fixed with non-absorbable sutures – the stem penetrated the iliac cortex 7 days later, for which re-fixation was performed; no further complications occurred). Structural failure of the implant itself was not observed.

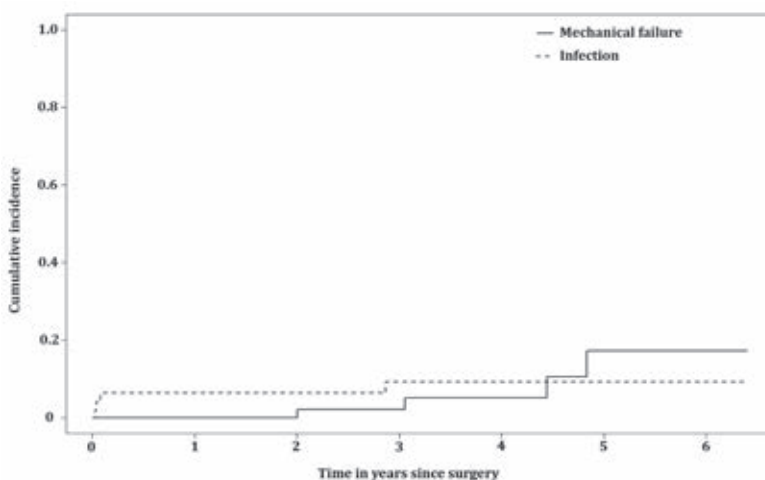
A total of 38% (18 of 47) of our patients experienced one or more non-mechanical complications. Deep infections (Henderson type IV) occurred in 13 patients (28%), 10 within 2 months, two after 3 months, and one after 34 months. Nine were successfully treated with surgical debridement and intravenous antibiotics. In four patients (10%; two with previous surgery – one THP, one pedestal cup), the implant was removed (three within one month, one after 34 months). At review, two of these patients were left flail without reconstruction and a hindquarter amputation, a type BII rotationplasty<sup>24</sup> and a second LUMiC were performed in one each. Median duration of surgery was 6.5 hours (range, 4.0 – 13.6 hours) for patients with an infection and 5.3 hours (range, 2.8 – 9.9 hours) for those without ( $p = 0.060$ ). Blood loss showed a statistically significant correlation with the risk of infection; blood loss was 2.3 L (range, 0.8 – 8.2 L) for patients with an infection and 1.5 L (range, 0.4 – 3.8 L) for those without ( $p = 0.039$ ). Other factors

we analyzed (attachment tubes, silver-coated cups) were not correlated to the risk of infection.

Local recurrence (Henderson type V) occurred in six patients (13%; four chondrosarcomas, one clear cell chondrosarcoma, and one phosphaturic mesenchymal tumor; the latter two had tumor spill during the index procedure) after a median of 22 months (range, 10 months to 4.5 years). Five were treated with construct-sparing resections and one patient had an extensive periprosthetic recurrence; no further surgery was undertaken because of a poor prognosis. Four of 41 primary tumors metastasized (10%).

The cumulative incidences of implant failure at two and five years were 2.1% (95% CI, 0 – 6.3) and 17.3% (95% CI, 0.7– 33.9) for mechanical reasons and 6.4% (95% CI 0 – 13.4) and 9.2% (95% CI, 0.5 – 17.9) for infection, respectively (figure 3). Mechanical reasons for failure were instability ( $n = 2$  [4%]; one patient underwent cup revision and was free of further complications; one patient underwent cup revision and the stem was later revised for loosening ( $n = 2$  [4%]). Infection was the only non-mechanical failure mechanism ( $n = 4$  [9%]). In all, 71 reoperations were performed in 25 patients (53%; range, one to eight), 59 of which (83%) were in the first postoperative year. Predominant reasons for reoperations were infection ( $n = 46$  [65%]), mechanical reasons ( $n = 15$  [21%]), and local recurrences ( $n = 6$  [8%]).

Mean MSTS scores at final follow-up were available for 24 patients (51%). The mean score was 21 of 30 points (70%; range, 30% – 93%); these were evaluated after a median of 39 months (range, 6 – 68 months).



**Figure 3.** Competing risk analyses of implant failure. This plot shows the cumulative incidence of mechanical failure (type 1–3) and infection (type 4). Patient mortality was used as a competing event in these analyses.

## Discussion

Periacetabular resection and subsequent reconstructions pose a difficult challenge to orthopaedic oncologists. In this retrospective multicenter study, we aimed to evaluate the short-term clinical results of periacetabular reconstruction with the LUMiC prosthesis after internal hemipelvectomy for a pelvic tumor. We found that this implant is associated with a low risk of mechanical failure at short-term follow-up. Nevertheless, these complex reconstructions were associated with a considerable risk of complications, most notably infection.

Our study has a number of limitations. Follow-up duration was limited and longer-term follow-up certainly will be needed to make any claims about intermediate- and long-term durability of this new implant. We tried to compensate for this by performing a multi-institutional study to increase our numbers. Also, we included heterogeneous diagnoses in this study. However, patient numbers are limited and we mainly focus on the reconstruction itself rather than on oncologic outcome. In addition, as a result of the multicenter design of this study, different surgical techniques and treatment protocols have been used. A considerable number of surgeons have operated on our patients and results may have been subject to learning curves. Surgeons involved in the care of the patients were involved with data collection and reporting, which may influence the reporting of complications. We however chose to report on hard endpoints and thereby reduced the risk of assessor bias. Unfortunately, the cumulative incidence plot for implant failure does not show a clear plateau phase and further failures may be expected. We will continue to follow our patients to ascertain the role of the LUMiC in the longer term. Also, we had MSTS functional data on half of our patients, so it is possible that we have overestimated the function we might have seen if we had MSTS scores on all of the patients.

Dislocation rates were dissatisfying in the early period of our study. We were able to improve this by introducing dual-mobility articulation (one single dislocation in 24 dual-mobility cups [4%]). The results obtained with dual-mobility cups compare favorably with results previously obtained with the pedestal cup prosthesis (16% recurrent dislocations, 11% single dislocation)<sup>9</sup> and with most other reports on periacetabular reconstruction (12% – 24%)<sup>6, 13, 17, 18, 25, 26</sup>. Two previous authors reported comparable dislocation rates (3% – 4%)<sup>14, 16</sup>. Our results suggest that that dual-mobility articulation may be useful for treating instability around the hip, a finding that has been reported elsewhere<sup>27</sup>. Currently, we use

dual-mobility cups for any LUMiC reconstruction after *en bloc* tumor resection. Owing to the frequently massive extent of soft tissue resection, muscular function can be heavily impaired and distorted after pelvic resection. Therefore, obtaining a stable reconstruction can be difficult. In a study on 27 reconstructions with the “ice-cream cone prosthesis” (Stanmore Implants Worldwide, Elstree, UK), Fisher *et al*<sup>6</sup> noted that dislocations occurred mainly after type 2-3 resection and attributed this to the fact that virtually all muscles that attached the leg to the pelvis had been resected. The authors stated that patients should be instructed to contract their gluteal muscles before attempting to move their leg. Although we found no difference in the risk of dislocation between resection types, their “buttock-up” instruction may aid to reduce dislocation rates. We aimed to prevent dislocations by introducing an implant that would offer optimal possibilities for cup orientation and positioning and by using large-diameter femoral heads. Orientation can be difficult with the patient loosely in lateral decubitus; in experience of the leading center, computer assistance is of added value in these situations. An influence of femoral head size was not demonstrated in our study, whereas it has been reported that large-diameter heads offer advantages in terms of stability both in hip arthroplasty and pelvic reconstruction<sup>6, 17, 28</sup>.

Loosening occurred in three reconstructions (6%): one in a patient who received uncemented fixation in a previous allograft reconstruction, one as a result of an intraoperative fracture, and one cemented stem. Our results compare favorably with the loosening rate we found in our study on the pedestal cup prosthesis (16%)<sup>9</sup>. On the other hand, Fisher *et al*<sup>6</sup> reported comparable results; they described loosening in one patient with insufficient bone stock (3%). Others reported loosening of the pelvic component in 12% to 15%<sup>14, 25</sup>. Because the long axis of the conical stem is in line with the load-bearing axis, loading of the LUMiC causes it to anchor itself into the iliac wing. This is fundamentally different from the biomechanics of custom three-dimensional-printed or modular hemipelvic implants. Furthermore, the stem is coated with HA, which reportedly reduces the risk of loosening of uncemented implants by enhancing bony ingrowth<sup>29</sup>. For the aforementioned reasons, we consider this design suitable for long-term stable fixation, and we prefer uncemented press-fit fixation. Possible indications for cemented fixation include radiation, metastatic disease, and the inability to obtain rigid primary fixation.

Infection was the most common complication (28%). Although most infections (nine of 13) were successfully eradicated with debridement and antibiotics, many



reoperations were performed and four reconstructions failed as a result. Previously, we reported an infection rate of 47% in reconstructions with the pedestal cup prosthesis<sup>9</sup>. We attempted to reduce the risk of infection by introducing silver-coated cups, but with the numbers we had, we could not demonstrate an advantage with this approach. However, only the outside of the 60-mm cup was silver-coated, and limited patient numbers hampered us. It has been shown that the release of silver ions protects against infection and favorable results have been reported by others<sup>30, 31</sup>; future studies will need to evaluate this in greater depth. With interest we noted the promising infection rate reported by Fisher et al<sup>6</sup>; three infections occurred in 27 patients (11%), and none resulted in implant failure in their short-term follow-up study. The authors theorized that the large amount of antibiotic-laden bone cement that they apply around the prosthesis minimizes the infection risk and allows effective treatment if it occurs. We are of the opinion that surgical duration should also be considered and, although this did not reach statistical significance, we found that the duration of surgery was greater for patients who developed an infection. This was in concordance with previous reports<sup>32</sup>. It is conceivable that surgical duration decreases when surgeons perform these procedures more often and in experienced teams; therefore, it might be worth considering having centralized centers that treat the majority of these patients so that patients can benefit from a team that has extensive experience in these reconstructions.

Overall cumulative incidences of implant failure at two and five years were 6.4% and 17.9%, respectively. Most studies on pelvic endoprostheses have not reported implant survival rates; however, our results compare favorably with others, reporting Kaplan-Meier estimated survival rates of 78% to 84% at two years<sup>13, 14</sup> and 40% to 60% at five years<sup>13, 18</sup>.

Mean MSTS score was 70%; this is comparable with two previous studies reporting mean scores of 69% and 70%<sup>6, 13</sup> with either MSTS<sup>23</sup> or Toronto Extremity Salvage Score (TESS)<sup>33</sup> questionnaires. Most authors report worse functional outcome with mean scores typically ranging between 47% and 64%<sup>14, 16-18, 26</sup>.

At short-term follow-up, the LUMiC prosthesis demonstrated a low frequency of mechanical complications and reoperations when used to reconstruct the acetabulum in patients who underwent major pelvic tumor resections, and we believe this is a useful reconstruction for certain periacetabular resections for tumor or failed prior reconstructions. Still, like with any type of pelvic reconstruction, complications are common after these complex procedures and we have not



directly compared our patients with a similar group with a different reconstruction. Infection was the main reason for implant failure. Although the majority of the infections were eradicated with surgical debridement and antibiotics, additional ways should be sought to reduce the infection risk. Our early results are reassuring that the use of dual-mobility articulation provides for stable pelvic reconstruction in the short term. Nevertheless, future larger studies will need to confirm the durability of the construct. We will continue to follow our patients over the longer term to ascertain the role of this implant in this setting.

*Note: we thank Professor Georg Gosheger MD, PhD, Joanna Krzywda-Pogorzelska MD, PhD, Magdalena Rychlowska-Pruszyńska MD, PhD, and Andrzej Pienkowski MD, PhD, for their cooperation, for operating on patients included in our study, and for critically reading our manuscript.*



## References


1. Grimer RJ, Chandrasekar CR, Carter SR, Abudu A, Tillman RM, Jeys L. Hindquarter amputation: is it still needed and what are the outcomes? *The bone & joint journal*. 2013 Jan;95-b(1):127-31. Epub 2013/01/12.
2. Wirbel RJ, Schulte M, Mutschler WE. Surgical treatment of pelvic sarcomas: oncologic and functional outcome. *Clinical orthopaedics and related research*. 2001 Sep(390):190-205. Epub 2001/09/12.
3. Campanacci M, Capanna R. Pelvic resections: the Rizzoli Institute experience. *The Orthopedic clinics of North America*. 1991 Jan;22(1):65-86. Epub 1991/01/01.
4. Donati D, Di Bella C, Frisoni T, Cevolani L, DeGroot H. Alloprosthetic composite is a suitable reconstruction after periacetabular tumor resection. *Clinical orthopaedics and related research*. 2011 May;469(5):1450-8. Epub 2011/02/12.
5. Enneking WF, Dunham WK. Resection and reconstruction for primary neoplasms involving the innominate bone. *The Journal of bone and joint surgery American volume*. 1978 Sep;60(6):731-46. Epub 1978/09/01.
6. Fisher NE, Patton JT, Grimer RJ, Porter D, Jeys L, Tillman RM, et al. Ice-cream cone reconstruction of the pelvis: a new type of pelvic replacement: early results. *The Journal of bone and joint surgery British volume*. 2011 May;93(5):684-8. Epub 2011/04/23.
7. Angelini A, Drago G, Trovarelli G, Calabro T, Ruggieri P. Infection after surgical resection for pelvic bone tumors: an analysis of 270 patients from one institution. *Clinical orthopaedics and related research*. 2014 Jan;472(1):349-59. Epub 2013/08/27.
8. Beadel GP, McLaughlin CE, Wunder JS, Griffin AM, Ferguson PC, Bell RS. Outcome in two groups of patients with allograft-prosthetic reconstruction of pelvic tumor defects. *Clinical orthopaedics and related research*. 2005 Sep;438:30-5. Epub 2005/09/01.
9. Bus MP, Boerhout EJ, Bramer JA, Dijkstra PD. Clinical outcome of pedestal cup endoprosthetic reconstruction after resection of a peri-acetabular tumour. *The bone & joint journal*. 2014 Dec;96-b(12):1706-12. Epub 2014/12/03.
10. Delloye C, Banse X, Brichard B, Docquier PL, Cornu O. Pelvic reconstruction with a structural pelvic allograft after resection of a malignant bone tumor. *The Journal of bone and joint surgery American volume*. 2007 Mar;89(3):579-87. Epub 2007/03/03.
11. Sys G, Uyttendaele D, Poffyn B, Verdonk R, Verstraete L. Extracorporeally irradiated autografts in pelvic reconstruction after malignant tumour resection. *International orthopaedics*. 2002;26(3):174-8. Epub 2002/06/20.
12. Bell RS, Davis AM, Wunder JS, Buconjic T, McGoveran B, Gross AE. Allograft reconstruction of the acetabulum after resection of stage-IIb sarcoma. Intermediate-term results. *The Journal of bone and joint surgery American volume*. 1997 Nov;79(11):1663-74. Epub 1997/12/31.
13. Menendez LR, Ahlmann ER, Falkinstein Y, Allison DC. Periacetabular reconstruction with a new endoprosthesis. *Clinical orthopaedics and related research*. 2009 Nov;467(11):2831-7. Epub 2009/08/21.
14. Witte D, Bernd L, Bruns J, Gosheger G, Harges J, Hartwig E, et al. Limb-salvage reconstruction with MUTARS® hemipelvic endoprosthesis: a prospective multicenter study. *European journal of surgical oncology : the journal of the European Society of Surgical Oncology and the British Association of Surgical Oncology*. 2009 Dec;35(12):1318-25. Epub 2009/05/30.
15. Dominkus M, Darwish E, Funovics P. Reconstruction of the pelvis after resection of malignant bone tumours in children and adolescents. Recent results in cancer research *Fortschritte der Krebsforschung Progres dans les recherches sur le cancer*. 2009;179:85-111. Epub 2009/02/24.
16. Guo W, Li D, Tang X, Yang Y, Ji T. Reconstruction with modular hemipelvic prostheses for periacetabular tumor. *Clinical orthopaedics and related research*. 2007 Aug;461:180-8. Epub 2007/04/25.
17. Jaiswal PK, Aston WJ, Grimer RJ, Abudu A, Carter S, Blunn G, et al. Peri-acetabular resection and endoprosthetic reconstruction for tumours of the acetabulum. *The Journal of bone and joint surgery British volume*. 2008 Sep;90(9):1222-7. Epub 2008/09/02.
18. Jansen JA, van de Sande MA, Dijkstra PD. Poor long-term clinical results of saddle prosthesis after resection of periacetabular tumors. *Clinical orthopaedics and related research*. 2013 Jan;471(1):324-31. Epub 2012/10/12.

19. Gosheger G, Hillmann A, Lindner N, Rodl R, Hoffmann C, Burger H, et al. Soft tissue reconstruction of megaprotheses using a trevira tube. *Clinical orthopaedics and related research*. 2001 Dec(393):264-71. Epub 2002/01/05.
20. Henderson ER, Groundland JS, Pala E, Dennis JA, Wooten R, Cheong D, et al. Failure mode classification for tumor endoprotheses: retrospective review of five institutions and a literature review. *The Journal of bone and joint surgery American volume*. 2011 Mar 2;93(5):418-29. Epub 2011/03/04.
21. Keurentjes JC, Fiocco M, Schreurs BW, Pijls BG, Nouta KA, Nelissen RG. Revision surgery is overestimated in hip replacement. *Bone & joint research*. 2012 Oct;1(10):258-62. Epub 2013/04/24.
22. Putter H, Fiocco M, Geskus RB. Tutorial in biostatistics: competing risks and multi-state models. *Statistics in medicine*. 2007 May 20;26(11):2389-430. Epub 2006/10/13.
23. Enneking WF, Dunham W, Gebhardt MC, Malawar M, Pritchard DJ. A system for the functional evaluation of reconstructive procedures after surgical treatment of tumors of the musculoskeletal system. *Clinical orthopaedics and related research*. 1993 Jan(286):241-6. Epub 1993/01/01.
24. Hillmann A, Gosheger G, Hoffmann C, Ozaki T, Winkelmann W. Rotationplasty--surgical treatment modality after failed limb salvage procedure. *Archives of orthopaedic and trauma surgery*. 2000;120(10):555-8. Epub 2000/12/08.
25. Aboulafia AJ, Buch R, Mathews J, Li W, Malawar MM. Reconstruction using the saddle prosthesis following excision of primary and metastatic periacetabular tumors. *Clinical orthopaedics and related research*. 1995 May(314):203-13. Epub 1995/05/01.
26. Aljassir F, Beadel GP, Turcotte RE, Griffin AM, Bell RS, Wunder JS, et al. Outcome after pelvic sarcoma resection reconstructed with saddle prosthesis. *Clinical orthopaedics and related research*. 2005 Sep;438:36-41. Epub 2005/09/01.
27. Levine BR, Della Valle CJ, Deirmengian CA, Breien KM, Weeden SH, Sporer SM, et al. The use of a tripolar articulation in revision total hip arthroplasty: a minimum of 24 months' follow-up. *The Journal of arthroplasty*. 2008 Dec;23(8):1182-8. Epub 2008/06/07.
28. Rodriguez JA, Rathod PA. Large diameter heads: is bigger always better? *The Journal of bone and joint surgery British volume*. 2012 Nov;94(11 Suppl A):52-4. Epub 2012/11/09.
29. Blunn GW, Briggs TW, Cannon SR, Walker PS, Unwin PS, Culligan S, et al. Cementless fixation for primary segmental bone tumor endoprotheses. *Clinical orthopaedics and related research*. 2000 Mar(372):223-30. Epub 2000/03/30.
30. Gosheger G, Harges J, Ahrens H, Streitburger A, Buerger H, Erren M, et al. Silver-coated megaendoprotheses in a rabbit model--an analysis of the infection rate and toxicological side effects. *Biomaterials*. 2004 Nov;25(24):5547-56. Epub 2004/05/15.
31. Harges J, Ahrens H, Gebert C, Streitburger A, Buerger H, Erren M, et al. Lack of toxicological side-effects in silver-coated megaprotheses in humans. *Biomaterials*. 2007 Jun;28(18):2869-75. Epub 2007/03/21.
32. Gradl G, de Witte PB, Evans BT, Hornicek F, Raskin K, Ring D. Surgical site infection in orthopaedic oncology. *The Journal of bone and joint surgery American volume*. 2014 Feb 5;96(3):223-30. Epub 2014/02/07.
33. Davis AM, Wright JG, Williams JI, Bombardier C, Griffin A, Bell RS. Development of a measure of physical function for patients with bone and soft tissue sarcoma. *Quality of life research : an international journal of quality of life aspects of treatment, care and rehabilitation*. 1996 Oct;5(5):508-16. Epub 1996/10/01.



# Part II

# Management of Extremity Bone Tumors





# Chapter 5

## **Intercalary Allograft Reconstructions Following Resection of Primary Bone Tumors**

*A Nationwide Multicenter Study*

M.P.A. Bus<sup>1</sup>

P.D.S. Dijkstra<sup>1</sup>

M.A.J. van de Sande<sup>1</sup>

A.H.M. Taminiau<sup>1</sup>

H.W.B. Schreuder<sup>2</sup>

P.C. Jutte<sup>3</sup>

I.C.M. van der Geest<sup>2</sup>

G.R. Schaap<sup>4</sup>

J.A.M. Bramer<sup>4</sup>

<sup>1</sup>Orthopaedic Surgery, Leiden University Medical Center, Leiden, the Netherlands

<sup>2</sup>Orthopaedic Surgery, Radboud University Medical Center, Nijmegen, the Netherlands

<sup>3</sup>Orthopaedic Surgery, University Medical Center Groningen, Groningen, the Netherlands

<sup>4</sup>Orthopaedic Surgery, Academic Medical Center, Amsterdam, the Netherlands

## Abstract

**Background:** Favorable reports on the use of massive allografts to reconstruct intercalary defects underline their place in limb-salvage surgery. However, little is known about optimal indications as reports on failure and complication rates in larger populations remain scarce. We evaluated the incidence of and risk factors for failure and complications, time to full weight-bearing, and optimal fixation methods for intercalary allografts after tumor resection.

**Methods:** A retrospective study was performed in all four centers of orthopaedic oncology in the Netherlands. All consecutive patients reconstructed with intercalary (whole-circumference) allografts after tumor resection in the long bones during 1989 to 2009 were evaluated. The minimum follow-up was 24 months. Eighty-seven patients with a median age of 17 years (1.5 to 77.5) matched inclusion criteria. The most common diagnoses were osteosarcoma, Ewing sarcoma, adamantinoma, and chondrosarcoma. The median follow-up period was 84 months (25 to 262). Ninety percent of tumors were localized in the femur or the tibia.

**Results:** Fifteen percent of our patients experienced a graft-related failure. The major complications were nonunion (40%), fracture (29%), and infection (14%). Complications occurred in 76% of patients and reoperations were necessary in 70% of patients. The median time to the latest complication was 32 months (0 to 200). The median time to full weight-bearing was nine months (1 to 80). Fifteen grafts failed, 12 of which failed in the first four years. None of the 34 tibial reconstructions failed. Reconstruction site, patient age, allograft length, nail-only fixation, and non-bridging osteosynthesis were the most important risk factors for complications. Adjuvant chemotherapy and irradiation had no effects on complication rates.

**Conclusions:** We report high complication rates and considerable failure rates for the use of intercalary allografts; complications primarily occurred in the first years after surgery, but some occurred much later after surgery. To reduce the number of failures, we recommend reconsidering the use of allografts for reconstructions of defects that are  $\geq 15$  cm, especially in older patients, and applying bridging osteosynthesis with use of plate fixation.



## Introduction

Until the 1970s, the treatment of high-grade extremity sarcoma routinely consisted of the amputation of affected limbs. Despite aggressive surgery, the five-year survival rate was  $\leq 20\%$ <sup>1-3</sup>. Because of the introduction of chemotherapy and advances in imaging and surgical techniques, limb salvage became feasible in an increasing number of patients and five-year survival rates increased to 55% to 70%<sup>4-11</sup>.

Most primary malignant bone tumors are localized in the epiphysis and/or metaphysis of the long bones, often necessitating resection of joints. Still, numerous tumors are located in the metaphysis or diaphysis<sup>10,12</sup>, in which case it is desirable to save adjacent joints. Reconstruction with intercalary allografts is a well-accepted surgical technique to reconstruct the osseous defect after such resections. Intercalary allografts have been recommended as a reliable solution with long-term success rates and good functional outcome in 82% to 84% of patients<sup>13,14</sup>. As intercalary allografts have relatively good stability compared with autografts, the main advantage of using intercalary allografts is the opportunity to biologically reconstruct a large long-bone deficit without donor site morbidity. Nevertheless, allografts are associated with high rates of infection (0% to 18%), fracture (0% to 30%), and delayed union or nonunion (15% to 55%)<sup>13-20</sup>. Finally, widespread use might be restricted by limited availability in some countries and by the minor possibility of transmission of infectious diseases.

In this multicenter study, we retrospectively evaluated (1) incidence of and risk factors for failure, (2) incidence of and risk factors for complications (with special emphasis on infection, fracture, and nonunion), (3) time to full weight-bearing, and (4) optimal fixation methods for intercalary allograft reconstructions after bone tumor surgery.

## Materials and Methods

In the Netherlands, primary bone tumors are treated in four appointed centers for orthopaedic oncology. To identify eligible patients, we assessed all massive allografts that were delivered to these centers by our national bone bank between 1989 and 2009. All consecutive whole-circumference resections of primary tumors in the long bones that were reconstructed with an intercalary allograft were included and retrospectively reviewed. The minimum follow-up was 24 months (figure 1).

Eighty-seven patients (46 male patients and 41 female patients) with a median age of 17 years (1.5 to 77.5) matched our inclusion criteria. Twenty-eight patients (32%) were younger than 14 years of age and 44 patients (51%) were younger than 18 years of age. The most common diagnoses were osteosarcoma (34 patients [39%]), Ewing sarcoma (17 patients [20%]), adamantinoma (15 patients [17%]), and chondrosarcoma (11 patients [13%]). Fifty-two patients (60%) received chemotherapy (34 for conventional osteosarcoma, 17 for Ewing sarcoma, and one for juxta-cortical osteosarcoma, according to EURAMOS [European and American Osteosarcoma Study Group] or Euro-EWING protocol), and nine patients (10%) underwent radiation therapy. The median follow-up was 84 months (25 to 262). Fifty-seven patients (66%) had follow-up for more than five years and 29 patients (33%) had follow-up for more than ten years (figure 2).

Tumor localizations included the femur (44 patients [51%]), the tibia (34 patients [39%]), the humerus (seven patients [8%]), and the radius (two patients [2%]). Twenty reconstructions (23%) were located in the proximal third of the bone and 24 reconstructions (28%) were located in the distal third of the bone. The remaining 43 reconstructions (49%) were diaphyseal. Thirty-five reconstructions (40%) spanned diaphysis to metaphysis, and nine reconstructions (10%) also affected the epiphysis. The median allograft reconstruction length (and standard deviation) was  $14.0 \pm 4.8$  cm (5.0 to 30.0) and did not differ significantly among reconstructions of femur (16.0 cm), tibia (14.0 cm), humerus (14.0 cm), and radius (13.0 cm).

Allografts were harvested under sterile conditions during postmortem tissue donation and were stored at  $-80^{\circ}\text{C}$  by our national bone bank. Processing was performed by either Osteotech (Eatontown, New Jersey) or the Musculoskeletal Transplant Foundation (Edison, New Jersey). Allografts were thawed in saline solution and antibiotics in the operating room during tumor resection. All patients received perioperative antibiotics according to protocol.

Allografts were attached to host bones with an array of plate-and-screw combinations in 62 patients (71%) (examples in figures 3A and 3B), a combination of intramedullary nails and plate(s) in 12 patients (14%), intramedullary nails only (in all cases locked at both ends) in eight patients (9%) (examples in figures 4A, 4B, and 4C), and screws with or without cerclage wires in five patients (6%). In the latter group, patients were 1.5 to 12 years of age. Primary hybrid reconstructions, combining intercalary allografts with vascularized fibular autografts, were performed in six patients (7%).

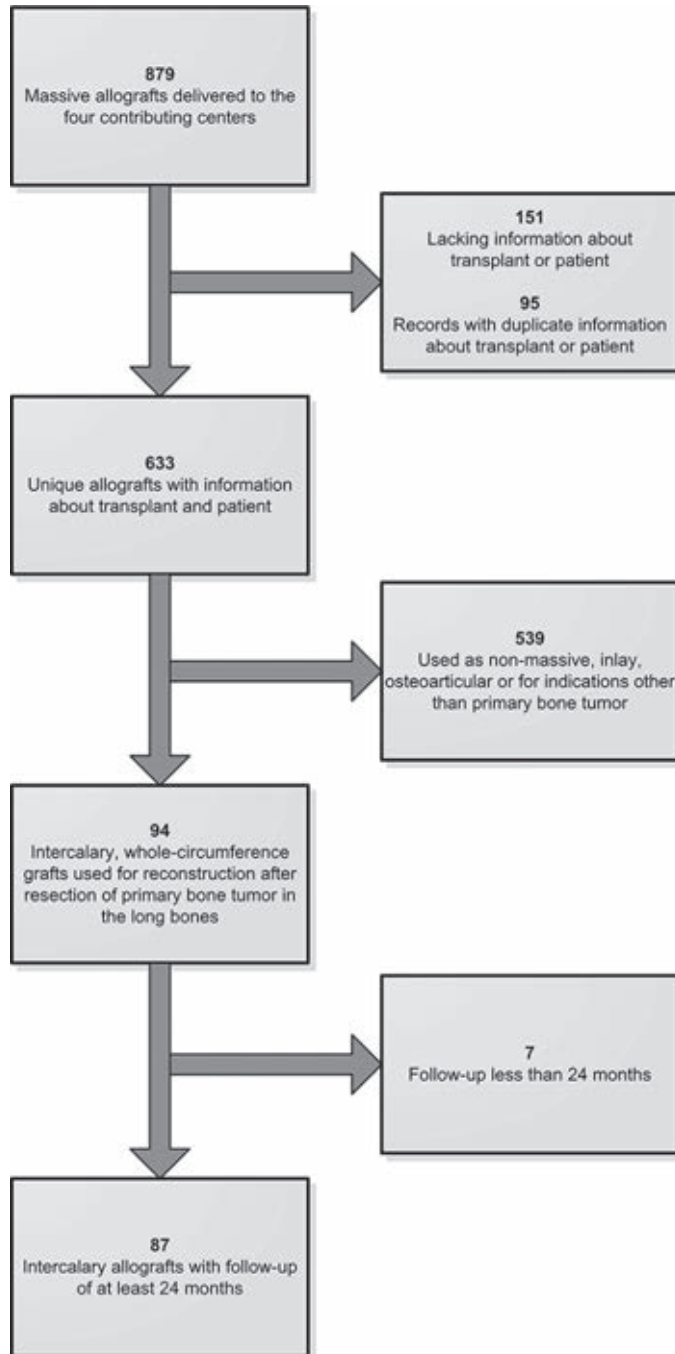
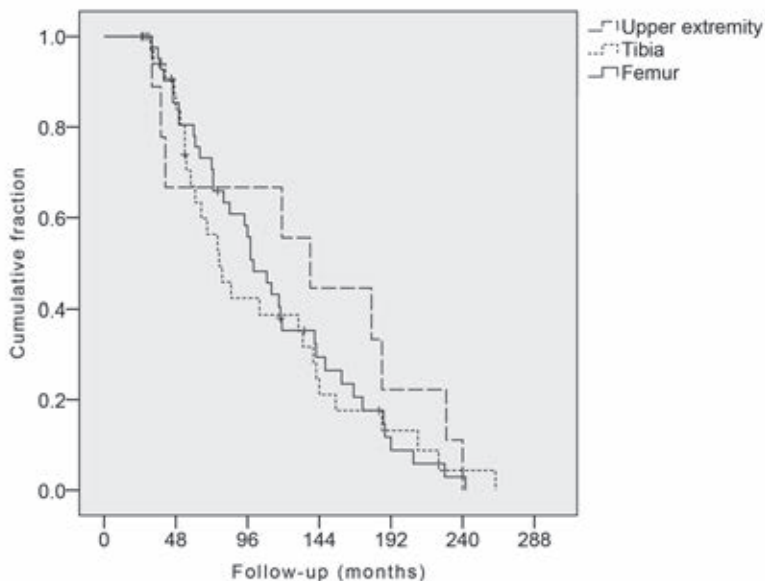


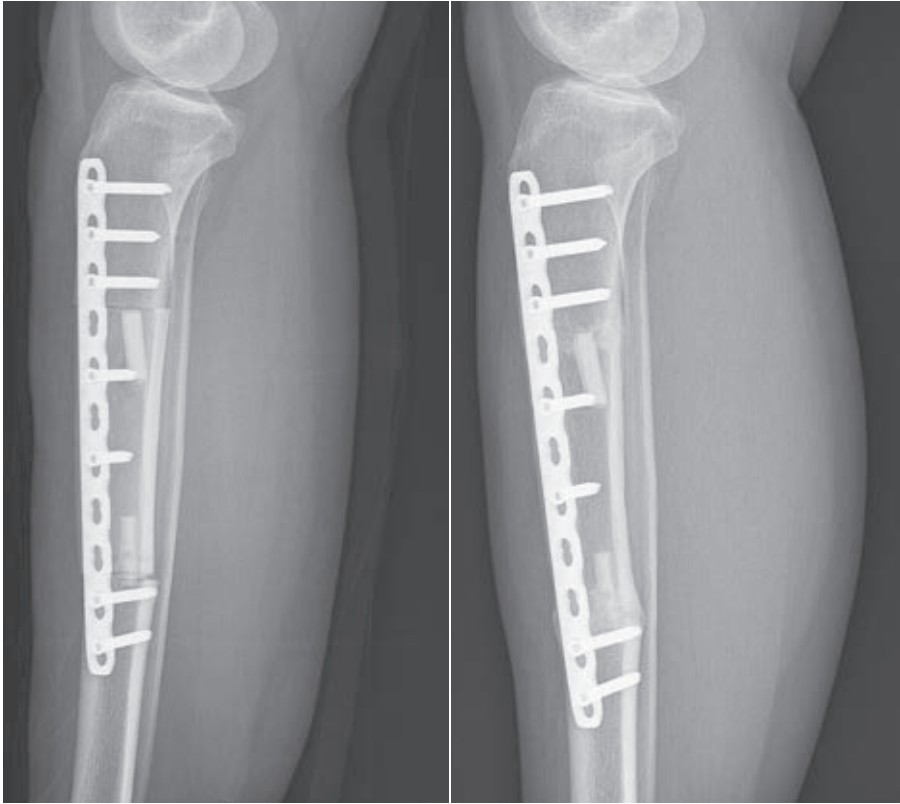
Figure 1. A flowchart showing an inclusion diagram.



**Figure 2.** Kaplan-Meier curve for patient follow-up plotted according to localization (n = 87).

Two separate definitions were applied to assess the union of allograft-host junctions. In the first definition, to compare the incidence of nonunion with that in prior series, unions of junctions were determined with use of conventional radiographs, and nonunion was defined as the lack of continuity in three cortices at the junction one year after surgery. If assessment of union was inconclusive on conventional radiographs, union was assessed with computed tomography (CT). In the second definition, to analyze risk factors for nonunion, surgical intervention to facilitate union of osseous junctions, at least six months after primary surgery, was defined as nonunion.

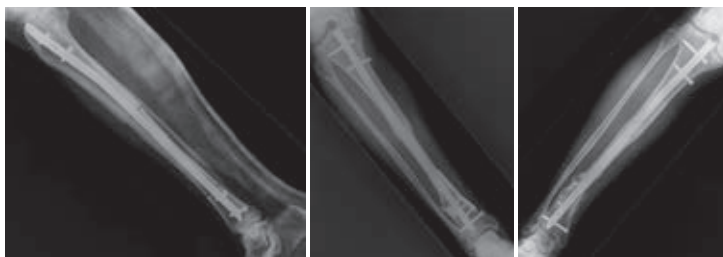
Allografts that were removed or were replaced were defined as failures. Graft-related failures were considered separately for statistical analysis. The type of osteosynthesis was defined as bridging if the intramedullary nail or plate osteosynthesis spanned the entire allograft and had a proximal and distal fixation zone in unaffected bone.



**Figures 3A and 3B.** Postoperative lateral radiographs showing a twenty-six-year-old woman who underwent osteosynthesis and received an 11-cm-long allograft that was implanted after radical resection of a low-grade osteosarcoma. (3A) Osteosynthesis was performed with use of a bridging plate. Two intramedullary fibular allografts were used to augment the reconstruction. (3B) Both proximal and distal osteotomy lines had excellent consolidation at thirteen months postoperatively.

We evaluated sex, age, diagnosis, affected bone, date of primary surgery, localization within bone level, and type of neo-adjuvant or adjuvant therapy. For reconstructions, we evaluated graft and fixation type, addition of autografts, and length of the reconstruction. Allograft length was measured on conventional radiographs and was corrected for magnification. We determined occurrence and time to complications. These determinations were performed separately for the lower extremity. Time to full weight-bearing was determined for lower-extremity reconstructions. Weight-bearing was allowed if the limb was considered stable, on the basis of imaging, physical examination, and duration since surgery. Study data were obtained from medical records, operation reports, and imaging, and

were specified in terms of frequencies and percentages (table 1). All data were complete except for time to full weight-bearing, for which there were missing data in 29 (37%) of the 78 patients in the lower-extremity reconstruction group.



**Figures 4A-C.** Radiographs of a sixty-nine-year-old man who underwent resection of an adamantinoma in the tibia and implantation of an allograft. (4A) A lateral radiograph made one day after implantation of the allograft. An intramedullary nail was used to fixate this 15-cm-long allograft. Osteotomy lines can be easily identified. (4B) A radiograph made thirteen months after implantation of the allograft. There is persistent pseudarthrosis of the distal allograft-host junction. Cancellous bone grafting and plate osteosynthesis were performed at the distal junction. (4C) An anteroposterior radiograph made thirty-eight months after the initial operation. Satisfactory consolidation was still not seen at the distal osteotomy site. Four months later, the intramedullary nail was removed and a vascularized fibular transposition was performed.

Nominal variables were compared between groups with use of chi-square tests, and continuous variables were compared between groups with use of Mann-Whitney tests. Logistic regression analysis was performed for nominal or categorical values in case of (a trend toward) significance. Cox regression analysis was performed for influence on time to failure. Kaplan-Meier curves were used to analyze time to complications. Outcomes are expressed in odds ratios (ORs), hazard ratios (HRs), 95% confidence intervals (95% CI), and p-values (significance was set at  $p < 0.05$ ).

**Table 1.** Study data

Variable	All localizations* (n = 87)	Lower extremity* (n = 78)
Sex		
Male	46 (53)	40 (51)
Female	41 (47)	38 (49)
Diagnosis		
Osteosarcoma (conventional type)	34 (39)	31 (40)
Ewing sarcoma	17 (20)	13 (17)
Adamantinoma	15 (17)	15 (19)
Chondrosarcoma	11 (13)	9 (12)
Pleomorphic undifferentiated sarcoma	3 (3)	3 (4)
Juxta-cortical osteosarcoma	3 (3)	3 (4)
Low-grade osteosarcoma	2 (2)	2 (3)
Leiomyosarcoma	1 (1)	1 (1)
Hemangioma	1 (1)	1 (1)
Patient age at the time of diagnosis		
Less than fourteen years	28 (32)	26 (33)
Less than eighteen years	44 (51)	41 (53)
Localization		
Femur	44 (51)	44 (56)
Tibia	34 (39)	34 (44)
Humerus	7 (8)	-
Radius	2 (2)	-
Localization within bone piece		
Diaphyseal	43 (49)	38 (49)
Metadiaphyseal	35 (40)	31 (40)
Epidiaphyseal	9 (10)	9 (12)
Neo-adjuvant and adjuvant therapy		
Neo-adjuvant chemotherapy	51 (59)	44 (56)
Adjuvant chemotherapy	52 (60)	45 (58)
Neo-adjuvant radiation therapy	2 (2)	2 (3)
Adjuvant radiation therapy	9 (10)	7 (9)
Osteosynthesis		
Bridging osteosynthesis	54 (62)	50 (64)
Plates†	62 (71)	55 (71)
Bridging plate(s)	35 (40)	33 (42)
Intramedullary nail and plate(s)	12 (14)	11 (14)
Intramedullary nail only	8 (9)	7 (9)
Screws and cerclage wires	5 (6)	5 (6)
Hybrid grafts (allograft and vascularized fibula)	6 (7)	6 (8)
Complications		
Number of complications		
None	21 (24)	21 (27)
One	26 (30)	23 (30)
Two	23 (26)	19 (24)

**Table 1.** Study data

Variable	All localizations* (n = 87)	Lower extremity* (n = 78)
Three	9 (10)	8 (10)
Four	5 (6)	4 (5)
Five	2 (2)	2 (3)
Eight	1 (1)	1 (1)
Type of complication		
Infection	12 (14)	8 (10)
Fracture	25 (29)	23 (30)
Nonunion	35 (40)	29 (37)
Associated with osteosynthesis materials	23 (26)	22 (25)
Reoperation	61 (70)	53 (68)
Failure		
Total number of removed allografts	15 (17)	10 (13)
Allograft-related failures	13 (15)	9 (12)
Duration of follow-up		
Five years or more	57 (66)	51 (65)
Ten years or more	29 (33)	23 (29)

\*The values are given as the number of patients, with the percentage in parentheses.

†The osteosynthesis with plates occurred with or without addition of fibular strut grafts and/or screws.

## Results

### Incidence of and Risk Factors for Failure

During follow-up, 15 patients (17%) had allografts removed, including 13 patients who had allografts removed because of graft-related complications (nine patients with complications in the femur and four patients with complications in the humerus) and two patients who had local recurrences and underwent ablative surgery (one patient underwent rotationplasty and one patient underwent amputation). The reasons for graft-related failures were fracture ( $n = 5$ ), infection ( $n = 4$ ), and nonunion ( $n = 4$ ). Of the graft-related failures, 12 occurred in the first four years after the index surgery. Three patients had late failures due to nonunion after six years, fracture after 11 years, and infection after 15 years. None of the graft-related failures necessitated ablative surgery; limb salvage was achieved in 98% of patients.

There were no significant differences in allograft survival or complication rates for patients who underwent operations in the late 1980s and early 1990s ( $n = 31$  [36%]), compared with those whose primary surgery took place after 1995.



Infection increased the risk of failure ( $n = 12$ ;  $p = 0.02$ ), and weak trends were seen for fracture ( $n = 25$ ;  $p = 0.09$ ) and nonunion ( $n = 35$ ;  $p = 0.09$ ). Failure rates were significantly higher in patients who were 18 years of age and older ( $n = 43$ ;  $p < 0.01$ ), in patients with reconstruction sites other than the tibia ( $n = 53$ ;  $p < 0.01$ ), and in patients undergoing diaphyseal reconstructions ( $n = 43$ ;  $p = 0.04$ ).

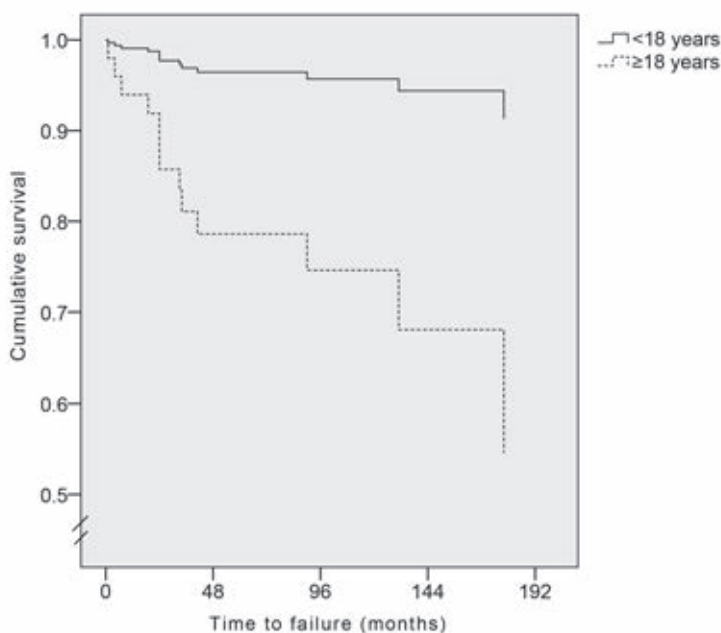
Failure rates for lower-extremity reconstructions were significantly higher in patients who were 18 years of age and older ( $n = 43$ ; OR, 11.03;  $p = 0.03$ ) and in patients undergoing reconstructions with an allograft of  $\geq 15$  cm in length ( $n = 39$ ; OR, 10.40;  $p = 0.03$ ) (table 2). In multivariable analyses, patients who were 18 years of age and older ( $n = 43$ ) demonstrated higher failure rates, independent of diaphyseal localization (OR, 6.23) and reconstruction length  $\geq 15$  cm (OR, 6.15) (table 3). Because none of the tibial reconstructions failed, reconstruction site was excluded from regression analysis.

**Table 2.** Univariate logistic regression analysis for the risk of failure, infection, and nonunion.

Complications and covariates	All localizations		Lower extremity	
	Odds ratio*	p-value	Odds ratio*	p-value
Failure†				
Patient age of $\geq 18$ years	7.22 (1.49 - 34.88)	0.01	11.03 (1.31 - 93.14)	0.03
Allograft length of $\geq 15.0$ cm	3.30 (0.93 - 11.70)	0.07	10.40 (1.23 - 87.75)	0.03
Localization within bone piece: diaphyseal	-	-	4.29 (0.83 - 22.15)	0.08
Infection‡				
Localization: femur	0.28 (0.07 - 1.10)	0.07	-	-
Osteosynthesis: bridging plate(s)	0.26 (0.05 - 1.24)	0.09	-	-
Osteosynthesis: plates§	0.34 (0.09 - 1.18)	0.09	-	-
Nonunion#				
Localization: tibia	0.37 (0.15 - 0.95)	0.04	-	-
Osteosynthesis: intramedullary nail only	5.17 (0.98 - 27.32)	0.05	4.90 (0.88 - 27.12)	0.07
Patient age of $\geq 14$ years	-	-	2.64 (0.91 - 7.66)	0.07
Allograft length of $\geq 10.0$ cm	3.93 (0.81 - 19.17)	0.09	-	-

\*The values are given as the odds ratio, with the 95% CI in parentheses. †There were thirteen patients who had failure in all locations and nine patients who had failure in the lower extremity. ‡There were twelve patients who had infection in all locations and eight patients who had infection in the lower extremity. §The osteosynthesis with plates occurred with or without addition of fibular strut grafts and/or screws. #There were thirty-five patients who had nonunion in all locations and twenty-nine patients who had nonunion in the lower extremity.

In univariable Cox regression analysis for influence on time to failure, bridging plate fixation (HR, 0.11) and patient age of eighteen years or older (HR, 6.66) were the most important factors (see appendix). For lower-extremity reconstructions, patient age of 18 years or older (HR, 9.46) and allograft length of  $\geq 15$  cm (HR, 9.00) were related to a shorter time to failure (figure 5; see appendix). In multivariable analysis, patient age of 18 years or older was the most important factor influencing time to failure (see appendix). Its influence was also significant in multivariable analyses with infection (HR, 6.22 [95% CI, 1.37 to 28.20];  $p = 0.02$ ), fracture (HR, 8.27 [95% CI, 1.79 to 38.16];  $p < 0.01$ ), and nonunion (HR, 6.43 [95% CI, 1.42 to 29.18];  $p = 0.02$ ).



**Figure 5.** A line graph showing Cox regression analysis for the influence of patient age of eighteen years or more on the time to failure.

## Complication Rates

During follow-up, 137 complications occurred in 66 patients (76%). Forty patients (46%) had two or more complications. With regard to major complications, 35 patients (40%) had nonunion, 25 patients (29%) had fracture, and 12 patients (14%) had infection. As for the time at which the different complications tended

to occur, there were no significant differences. Twenty-three patients (26%) had a complication related to the osteosynthesis materials: broken implants (11 patients, eight of whom were under treatment for nonunion), aseptic loosening (five patients), pain (four patients), or malposition and instability of osteosynthesis materials (three patients).

Reoperations were performed in 61 patients (70%). Whereas reoperation rates were significantly lower in tibial reconstructions ( $p < 0.01$ ), nail-only fixation increased reoperation rates ( $p = 0.04$ ). Because none of the nail-only reconstructions were free from reoperations, regression analysis was not performed.

The median time to first complication was 14 months (0 to 66; 95% CI 9 to 19); 44% occurred in less than one year and 68% occurred in less than two years after the index procedure. The median time to the latest complication was 32 months (0 to 200; 95% CI 4 to 40); 24% occurred within one year after primary surgery and 70% occurred within four years.

Complication rates were significantly lower in tibial reconstructions ( $n = 34$ ;  $p = 0.01$ ). Nail-only fixation ( $n = 8$ ) was weakly associated with a higher complication risk ( $p = 0.09$ ). Because all nail-only reconstructions had at least one complication, multivariable analysis could not be performed.

## Infection

Although not significant, the infection rate was lower for femoral reconstructions (OR, 0.28) (table 2). In eight (24%) of the 34 tibial reconstructions, muscle flaps were used. Of the six patients with a hybrid reconstruction, three developed infection ( $p < 0.01$ ); all were adequately treated with antibiotics.

## Fracture

None of the investigated factors significantly influenced fracture rates. In the lower extremity, fracture risk was higher after non-bridging fixation ( $n = 28$ ;  $p = 0.05$ ).

## Nonunion

One year after primary surgery, there was lack of continuity of three cortices at the allograft-host junctions in 23 patients (26%). In two of the patients in whom the graft was considered to be incorporated on radiographs one year after primary surgery, cancellous bone grafting was performed at a later stage. In total, 35 patients (40%) with allografts required surgical intervention to facilitate the union of allograft-host junctions: ten patients underwent secondary surgery six

to 12 months after the initial surgery, and the remaining 25 patients underwent secondary surgery more than a year after the initial surgery.

In univariable analysis, tibial localization (OR, 0.37) decreased the nonunion risk, but nail-only fixation (OR, 5.17) and allograft length of  $\geq 10$  cm (OR, 3.93) both showed trends toward higher nonunion rates (table 2). In multivariable analysis, nail-only fixation (OR, 7.30) and tibial localization (OR, 0.33) were of significance (table 3).

### Time to Full Weight-Bearing

The median time to full weight-bearing was nine months (1 to 81, 95% CI 7.5 to 10.5). Because there were missing data in 37% of relevant patients, a comparison between groups was not performed.

**Table 3.** Multivariate logistic regression analysis for the risk of failure and nonunion

Complications and covariates	All localizations		Lower extremity	
	Odds ratio*	p-value	Odds ratio*	p-value
Failure†				
First analysis				
Patient age of $\geq 18$ years	6.15 (1.25 - 30.34)	0.03	8.04 (0.92 - 70.53)	0.06
Allograft length of $\geq 15.0$ cm	2.51 (0.67 - 9.36)	0.01	7.47 (0.85 - 65.75)	0.07
Second analysis				
Patient age of $\geq 18$ years	6.23 (1.24 - 31.34)	0.03	8.57 (0.98 - 75.19)	0.05
Localization within bone piece: diaphyseal	1.68 (0.44 - 6.42)	0.45	2.66 (0.48 - 14.76)	0.26
Nonunion‡				
Localization: tibia	0.33 (0.12 - 0.91)	0.03	0.38 (0.14 - 1.08)	0.07
Osteosynthesis: intramedullary nail only	7.30 (1.16 - 45.69)	0.03	6.66 (1.05 - 42.22)	0.04
Allograft length of $\geq 10.0$ cm	3.81 (0.74 - 19.72)	0.11	2.97 (0.56 - 15.76)	0.20

\*The values are given as the odds ratio, with the 95% CI in parentheses. †There were thirteen patients who had failure in all locations and nine patients who had failure in the lower extremity. ‡There were thirty-five patients who had nonunion in all locations and twenty-nine patients who had nonunion in the lower extremity.

## Discussion

We evaluated (1) incidence of and risk factors for failure, (2) incidence of and risk factors for complications, (3) time to full weight-bearing, and (4) optimal fixation methods for intercalary allografts after tumor resection. Judging from the literature,

intercalary allografts provide a reasonable solution in the reconstruction of large osseous defects, with the possibility of preserving native joints while avoiding donor site morbidity<sup>13-18,21-26</sup>. In our study, a considerable percentage of graft-related failures was observed (15%), and 76% of the patients had one or more complications. The major complications were nonunion (40%), fracture (29%), and infection (14%). In addition, 26% of patients had a complication related to the osteosynthesis implants.

Our 17% failure rate was comparable with prior studies, ranging from 10% to 39% (see appendix). Although it is conceivable that adverse events are influenced by techniques and implants used in the earlier period of our study compared with modern techniques, we found no differences in graft survival and complication rates between patients undergoing operations from 1989 to 1995 and those undergoing operations after 1995.

The most important risk factors for failure and complications in our study population were anatomical site other than tibia, patient age of eighteen years or older, allograft length of  $\geq 15$  cm, intramedullary nail-only fixation, and diaphyseal localization. Four of seven humeral reconstructions failed. Previous studies did not show significant differences in outcome between different anatomical sites<sup>14,17,19</sup>.

Tibial reconstructions are often thought to be demanding because of limited possibilities of soft-tissue coverage and poor vascularity<sup>22,27,28</sup>. Nevertheless, we found lower complication and nonunion rates for tibial reconstructions. The fact that femoral allografts displayed lower infection rates might be explained by the better soft-tissue coverage of the femur as compared with the tibia.

In our population, adult age was associated with a higher risk of failure. Previous studies have also shown associations between increasing age and higher incidences of delayed union or nonunion<sup>20,29</sup>.

Nail-only fixation was associated with a higher risk of nonunion and the reoperation rate was lower after plate fixation. Previous studies have shown that fixation providing rigid stability might improve allograft incorporation<sup>13,30</sup>. Vander Griend stated that there is an important association between achieving stable fixation, more easily done using plates, and decreasing nonunion<sup>30</sup>.

Previously, allograft length has been described as a risk factor for fracture<sup>20</sup>. Although associated with a higher risk of both failure and nonunion, we were unable to identify an association between graft length and fracture rate.

Diaphyseal localization was adversely related to the time to failure. Previously, unfavorable results have been reported for diaphyseal junctions<sup>13,15</sup>. These

unfavorable results might be explained by the smaller contact surface of these junctions, as compared with metaphyseal and epiphyseal junctions. However, other studies found no differences or even a higher rate of delayed union for osteotomy lines placed in metaphyseal cancellous bone<sup>20,31</sup>.

Nonunion rates vary greatly throughout literature (15% to 55%)<sup>13,14,16-19,32-34</sup>. Whereas some studies assess nonunion per patient, others consider both osteotomy lines and thus score more nonunions. In a large prior study, nonunion was defined as the lack of continuity in three cortices at the junctional site one year after surgery<sup>20</sup>. Whereas 47% of patients in that study matched this definition, only 26% of patients in our study did. We chose to report on nonunion in a second way: if additional surgery was performed to facilitate union, taking place at least six months after implantation of the graft. Forty percent of our patients matched this definition. Previous large series have shown reoperation rates for nonunion ranging from 15% to 28%<sup>13,15,20</sup>.

The overall complication rate in our study was high compared with those in previous series, which showed complication rates ranging from 42% to 46% (see appendix). However, this rate appears to be related to those complications that were tracked, rather than a difference in the incidence of major complications (infection, fracture, and nonunion).

Whereas adverse effects of adjuvant treatment have been described in the literature<sup>20,29</sup>, we were not able to identify any unfavorable associations for adjuvant chemotherapy or irradiation.

Fracture and infection rates in our population were high, but comparable with previously reported rates<sup>14,15,20,35,36</sup>. Because of the retrospective character of this study, we were unable to retrieve all data on the time to full weight-bearing and, thus, conclusions must be made with caution. Nevertheless, partial and non-weight-bearing periods were considerable in our patients. Authors in previous studies have not reported time to full weight-bearing<sup>13-15,20</sup>.

Our study had additional limitations. Although follow-up in our study is among the longest reported on intercalary allografts (see appendix), there is a possibility of underestimating real complication percentages, as there are considerable percentages of late complications. Also, we were unable to acquire functional outcome.

In conclusion, we found high rates of complications leading to reoperations. The majority of complications occurred in the first two years after implantation. Even though complication rates were high, the graft survival rate was 83% and

limb salvage was achieved in 98% of patients. Reconstruction site, patient age, allograft length, nail-only fixation, and non-bridging osteosynthesis were the most important risk factors for complications. Nevertheless, in selected cases, intercalary allografts provide an acceptable surgical treatment of many bone tumors.

## Appendices

**Table A-1.** Univariate Cox regression analysis for the time to failure (n = 15) and time to full weight-bearing (n = 49).

Covariates	All localizations		Lower extremity	
	Hazard ratio*	p-value	Hazard ratio*	p-value
Time to failure				
Infection	3.12 (0.95 - 10.20)	0.06	-	-
Fracture	2.81 (0.94 - 8.41)	0.06	4.67 (1.17 - 18.66)	0.02
Patient age of ≥18 years	6.66 (1.47 - 30.11)	0.01	9.46 (1.18 - 75.71)	0.03
Osteosynthesis: bridging plate(s)	0.11 (0.01 - 0.82)	0.03	0.15 (0.02 - 1.23)	0.08
Localization within bone piece: diaphyseal	2.83 (0.86 - 9.30)	0.08	4.08 (0.85 - 19.68)	0.08
Allograft length of ≥15.0 cm	2.80 (0.86 - 9.11)	0.09	9.00 (1.12 - 72.07)	0.04
Time to full weight-bearing				
Nonunion	-	-	0.36 (0.18 - 0.74)	<0.01
Osteosynthesis: intramedullary nail only	-	-	0.27 (0.09 - 0.77)	0.02
Adjuvant radiation therapy	-	-	0.42 (0.16 - 1.08)	0.07

\*The values are given as the hazard ratio, with the 95% CI in parentheses.

**Table A-2.** Multivariate Cox regression analysis for the time to failure

Covariates	All localizations		Lower extremity	
	Hazard ratio*	p-value	Hazard ratio*	p-value
First analysis				
Patient age of ≥18 years	5.66 (1.25 - 25.68)	0.03	8.23 (1.03 - 66.03)	0.05
Osteosynthesis: bridging plate(s)	0.13 (0.02 - 0.98)	0.05	0.19 (0.02 - 1.48)	0.11
Second analysis				
Patient age of ≥18 years	5.57 (1.18 - 26.32)	0.03	7.45 (0.91 - 61.28)	0.06
Localization within bone piece: diaphyseal	1.78 (0.53 - 6.02)	0.36	2.72 (0.55 - 13.46)	0.22
Third analysis				
Patient age of ≥18 years	5.65 (1.21 - 26.27)	0.03	6.45 (0.79 - 52.67)	0.08
Allograft length of ≥15.0 cm	1.91 (0.58 - 6.37)	0.29	6.01 (0.74 - 49.04)	0.09
Fourth analysis				
Localization within bone piece: diaphyseal	2.85 (0.86 - 9.47)	0.09	3.70 (0.77 - 17.87)	0.10
Osteosynthesis: bridging plate(s)	0.11 (0.01 - 0.82)	0.03	3.70 (0.77 - 17.87)	0.09

\*The values are given as the hazard ratio, with the 95% CI in parentheses.



Table A-3. Overview of literature on intercalary allografts.

Data	Reference								
	Ortiz-Cruz <sup>14</sup> (1997)	Frisoni <sup>20</sup> (2012)	Aponte-Tiniao <sup>13</sup> (2012)	Muscolo <sup>15</sup> (2004)	Donati <sup>16</sup> (2000)	Zimel <sup>18</sup> (2009)	Cara <sup>17</sup> (1994)	Gerrand <sup>19</sup> (2003)	Current study (2013)
No. of patients	104	101	83	59	39	38	23	20	87
Localization									
Femur	38%	100%	100%	68%	72%	100%	61%	25%	51%
Tibia	37%	-	-	32%	28%	-	35%	30%	39%
Humerus	18%	-	-	-	-	-	4%	45%	8%
Radius	3%	-	-	-	-	-	-	-	2%
Fibula	3%	-	-	-	-	-	-	-	-
Ulna	3%	-	-	-	-	-	-	-	-
Follow-up*	67 (24 - 220)	112 (24 - 238)	61 (24 - 182)	60† (24 - 264)	‡	84‡ (14 - 231)	35 (12 - 75)	54 (10 - 134)	84 (25 - 262)
Fixation type									
Plates	93%	90%	65%	-	59%	8%	78%	-	71%
Intramedullary nail	7%	10%	19%	33%	15%	92%	4%	-	9%
Screws	-	-	16%	16%	-	-	-	-	6%
Plates and screws	-	-	-	52%	26%	-	-	-	-
Intramedullary nail and plate	-	-	-	-	-	-	17%	-	14%
Overall complications	-	-	46%	-	-	-	42%	-	76%
Specific complications									
Infection	12%	-	1%	5%	0%	18%	17%	10%	14%
Fracture	17%	27%	16%	7%	30%	3%	9%	0%	29%
Nonunion	30%	47%	24%	15%	55%	16%	15%	15%	40%
Failure	14%	24%	18%	15%	15%	39%	12%	10%	17%
Details	More complications with adjunct therapy, no clear influence of osteosynthesis type.	26% hybrid grafts; age and allograft length adversely related to outcome.	More nonunions after intramedullary nail fixation and in diaphyseal junctions.	More nonunions in diaphyseal junctions.	29% of femoral and 73% of tibial reconstructions were hybrid grafts.	Allograft-prosthesis comparison; total population: 85 patients, 47 endoprostheses.	Deceased patients excluded.	All reconstructions reinforced with pressurized intramedullary cement.	-

\*The values are given as the median, with the range in parentheses, in months. †The values are given as the mean, with the range in parentheses, in months. ‡This value was not reported for intercalary allografts specifically.

## References

1. Friedman MA, Carter SK. The therapy of osteogenic sarcoma: current status and thoughts for the future. *Journal of surgical oncology*. 1972;4(5):482-510. Epub 1972/01/01.
2. Link MP, Goorin AM, Miser AW, Green AA, Pratt CB, Belasco JB, et al. The effect of adjuvant chemotherapy on relapse-free survival in patients with osteosarcoma of the extremity. *The New England journal of medicine*. 1986 Jun 19;314(25):1600-6. Epub 1986/06/19.
3. Eilber F, Giuliano A, Eckardt J, Patterson K, Moseley S, Goodnight J. Adjuvant chemotherapy for osteosarcoma: a randomized prospective trial. *Journal of clinical oncology : official journal of the American Society of Clinical Oncology*. 1987 Jan;5(1):21-6. Epub 1987/01/01.
4. Tierney JF, Mosseri V, Stewart LA, Souhami RL, Parmar MK. Adjuvant chemotherapy for soft-tissue sarcoma: review and meta-analysis of the published results of randomised clinical trials. *British journal of cancer*. 1995 Aug;72(2):469-75. Epub 1995/08/01.
5. Enneking WF. An abbreviated history of orthopaedic oncology in North America. *Clinical orthopaedics and related research*. 2000 May(374):115-24. Epub 2000/05/20.
6. Grimer RJ, Taminiau AM, Cannon SR. Surgical outcomes in osteosarcoma. *The Journal of bone and joint surgery British volume*. 2002 Apr;84(3):395-400. Epub 2002/05/11.
7. Renard AJ, Veth RP, Schreuder HW, van Loon CJ, Koops HS, van Horn JR. Function and complications after ablative and limb-salvage therapy in lower extremity sarcoma of bone. *Journal of surgical oncology*. 2000 Apr;73(4):198-205. Epub 2000/05/08.
8. Rosen G. Preoperative (neoadjuvant) chemotherapy for osteogenic sarcoma: a ten year experience. *Orthopedics*. 1985 May;8(5):659-64. Epub 1985/05/01.
9. Simon MA, Aschliman MA, Thomas N, Mankin HJ. Limb-salvage treatment versus amputation for osteosarcoma of the distal end of the femur. *The Journal of bone and joint surgery American volume*. 1986 Dec;68(9):1331-7. Epub 1986/12/01.
10. Bielack SS, Kempf-Bielack B, Delling G, Exner GU, Flege S, Helmke K, et al. Prognostic factors in high-grade osteosarcoma of the extremities or trunk: an analysis of 1,702 patients treated on neoadjuvant cooperative osteosarcoma study group protocols. *Journal of clinical oncology : official journal of the American Society of Clinical Oncology*. 2002 Feb 1;20(3):776-90. Epub 2002/02/01.
11. Whelan JS, Jinks RC, McTiernan A, Sydes MR, Hook JM, Trani L, et al. Survival from high-grade localised extremity osteosarcoma: combined results and prognostic factors from three European Osteosarcoma Intergroup randomised controlled trials. *Annals of oncology : official journal of the European Society for Medical Oncology / ESMO*. 2012 Jun;23(6):1607-16. Epub 2011/10/22.
12. Arndt CA, Crist WM. Common musculoskeletal tumors of childhood and adolescence. *The New England journal of medicine*. 1999 Jul 29;341(5):342-52. Epub 1999/07/29.
13. Aponte-Tinao L, Farfalli GL, Ritacco LE, Ayerza MA, Muscolo DL. Intercalary femur allografts are an acceptable alternative after tumor resection. *Clinical orthopaedics and related research*. 2012 Mar;470(3):728-34. Epub 2011/06/22.
14. Ortiz-Cruz E, Gebhardt MC, Jennings LC, Springfield DS, Mankin HJ. The results of transplantation of intercalary allografts after resection of tumors. A long-term follow-up study. *The Journal of bone and joint surgery American volume*. 1997 Jan;79(1):97-106. Epub 1997/01/01.
15. Muscolo DL, Ayerza MA, Aponte-Tinao L, Ranalletta M, Abalo E. Intercalary femur and tibia segmental allografts provide an acceptable alternative in reconstructing tumor resections. *Clinical orthopaedics and related research*. 2004 Sep(426):97-102. Epub 2004/09/04.
16. Donati D, Di Liddo M, Zavatta M, Manfrini M, Bacci G, Picci P, et al. Massive bone allograft reconstruction in high-grade osteosarcoma. *Clinical orthopaedics and related research*. 2000 Aug(377):186-94. Epub 2000/08/16.
17. Cara JA, Lacleriga A, Canadell J. Intercalary bone allografts. 23 tumor cases followed for 3 years. *Acta orthopaedica Scandinavica*. 1994 Feb;65(1):42-6. Epub 1994/02/01.
18. Zimel MN, Cizik AM, Rapp TB, Weisstein JS, Conrad EU, 3rd. Megaprosthesis versus Condyle-sparing intercalary allograft: distal femoral sarcoma. *Clinical orthopaedics and related research*. 2009 Nov;467(11):2813-24. Epub 2009/08/08.

19. Gerrand CH, Griffin AM, Davis AM, Gross AE, Bell RS, Wunder JS. Large segment allograft survival is improved with intramedullary cement. *Journal of surgical oncology*. 2003 Dec;84(4):198-208. Epub 2004/02/06.
20. Frisoni T, Cevolani L, Giorgini A, Dozza B, Donati DM. Factors affecting outcome of massive intercalary bone allografts in the treatment of tumours of the femur. *The Journal of bone and joint surgery British volume*. 2012 Jun;94(6):836-41. Epub 2012/05/26.
21. Muscolo DL, Ayerza MA, Aponte-Tinao LA, Ranalletta M. Partial epiphyseal preservation and intercalary allograft reconstruction in high-grade metaphyseal osteosarcoma of the knee. *The Journal of bone and joint surgery American volume*. 2004 Dec;86-a(12):2686-93. Epub 2004/12/14.
22. Farfalli GL, Aponte-Tinao L, Lopez-Millan L, Ayerza MA, Muscolo DL. Clinical and functional outcomes of tibial intercalary allografts after tumor resection. *Orthopedics*. 2012 Mar;35(3):e391-6. Epub 2012/03/06.
23. Makley JT. The use of allografts to reconstruct intercalary defects of long bones. *Clinical orthopaedics and related research*. 1985 Jul-Aug(197):58-75. Epub 1985/07/01.
24. Abed R, Grimer R. Surgical modalities in the treatment of bone sarcoma in children. *Cancer treatment reviews*. 2010 Jun;36(4):342-7. Epub 2010/03/13.
25. Grimer RJ. Surgical options for children with osteosarcoma. *The Lancet Oncology*. 2005 Feb;6(2):85-92. Epub 2005/02/03.
26. Muscolo DL, Ayerza MA, Aponte-Tinao L, Farfalli G. Allograft reconstruction after sarcoma resection in children younger than 10 years old. *Clinical orthopaedics and related research*. 2008 Aug;466(8):1856-62. Epub 2008/05/29.
27. Graci C, Maccauro G, Muratori F, Spinelli MS, Rosa MA, Fabbriani C. Infection following bone tumor resection and reconstruction with tumoral prostheses: a literature review. *International journal of immunopathology and pharmacology*. 2010 Oct-Dec;23(4):1005-13. Epub 2011/01/20.
28. Jeys LM, Grimer RJ, Carter SR, Tillman RM. Periprosthetic infection in patients treated for an orthopaedic oncological condition. *The Journal of bone and joint surgery American volume*. 2005 Apr;87(4):842-9. Epub 2005/04/05.
29. Hornicek FJ, Gebhardt MC, Tomford WW, Sorger JI, Zavatta M, Menzner JP, et al. Factors affecting nonunion of the allograft-host junction. *Clinical orthopaedics and related research*. 2001 Jan(382):87-98. Epub 2001/01/12.
30. Vander Griend RA. The effect of internal fixation on the healing of large allografts. *The Journal of bone and joint surgery American volume*. 1994 May;76(5):657-63. Epub 1994/05/01.
31. Deijkers RL, Bloem RM, Kroon HM, Van Lent JB, Brand R, Taminiau AH. Epidiaphyseal versus other intercalary allografts for tumors of the lower limb. *Clinical orthopaedics and related research*. 2005 Oct;439:151-60. Epub 2005/10/06.
32. Brunet O, Anract P, Bouabid S, Babinet A, Dumaine V, Tomeno B, et al. Intercalary defects reconstruction of the femur and tibia after primary malignant bone tumour resection. A series of 13 cases. *Orthopaedics & traumatology, surgery & research : OTSR*. 2011 Sep;97(5):512-9. Epub 2011/07/12.
33. Bullens PH, Minderhoud NM, de Waal Malefijt MC, Veth RP, Buma P, Schreuder HW. Survival of massive allografts in segmental oncological bone defect reconstructions. *International orthopaedics*. 2009 Jun;33(3):757-60. Epub 2008/12/04.
34. Mankin HJ, Springfield DS, Gebhardt MC, Tomford WW. Current status of allografting for bone tumors. *Orthopedics*. 1992 Oct;15(10):1147-54. Epub 1992/10/01.
35. Berrey BH, Jr., Lord CF, Gebhardt MC, Mankin HJ. Fractures of allografts. Frequency, treatment, and end-results. *The Journal of bone and joint surgery American volume*. 1990 Jul;72(6):825-33. Epub 1990/07/01.
36. Thompson RC, Jr., Garg A, Clohisy DR, Cheng EY. Fractures in large-segment allografts. *Clinical orthopaedics and related research*. 2000 Jan(370):227-35. Epub 2000/02/08.





# Chapter 6

## **Hemicortical Resection and Inlay Allograft Reconstruction for Primary Bone Tumors**

*A Retrospective Evaluation in the Netherlands  
and Review of the Literature*

M.P.A. Bus<sup>1</sup>

J.A.M. Bramer<sup>2</sup>

G.R. Schaap<sup>2</sup>

H.W.B. Schreuder<sup>3</sup>

P.C. Jutte<sup>4</sup>

I.C.M. van der Geest<sup>2</sup>

M.A.J. van de Sande<sup>1</sup>

P.D.S. Dijkstra<sup>1</sup>

<sup>1</sup>Orthopaedic Surgery, Leiden University Medical Center, Leiden, the Netherlands

<sup>2</sup>Orthopaedic Surgery, Academic Medical Center, Amsterdam, the Netherlands

<sup>3</sup>Orthopaedic Surgery, Radboud University Medical Center, Nijmegen, the Netherlands

<sup>4</sup>Orthopaedic Surgery, Academic Medical Center, Amsterdam, the Netherlands

## Abstract

**Background:** Selected primary tumors of the long bones can be adequately treated with hemicortical resection, allowing for optimal function without compromising the oncological outcome. Allografts can be used to reconstruct the defect. As there is a lack of studies of larger populations with sufficient follow-up, little is known about the outcomes of these procedures.

**Methods:** In this nationwide retrospective study, all patients treated with hemicortical resection and allograft reconstruction for a primary bone tumor from 1989 to 2012 were evaluated for (1) mechanical complications and infection, (2) oncological outcome, and (3) failure or allograft survival. The minimum duration of follow-up was 24 months.

**Results:** The study included 111 patients with a median age of 28 years (7 to 73). The predominant diagnoses were adamantinoma ( $n = 37$ ; 33%) and parosteal osteosarcoma ( $n = 18$ ; 16%). At the time of review, 104 patients (94%) were alive (median duration of follow-up, 6.7 years). Seven patients (6%) died, after a median of 26 months. Thirty-seven patients (33%) had non-oncological complications, with host bone fracture being the most common ( $n = 20$ , 18%); all healed uneventfully. Other complications included nonunion ( $n = 8$ ; 7%), infection ( $n = 8$ ; 7%), and allograft fracture ( $n = 3$ ; 3%). Of 97 patients with a malignant tumor, 15 (15%) had residual or recurrent tumor and six (6%) had metastasis. The risk of complications and fractures increased with the extent of cortical resection.

**Conclusions:** Survival of hemicortical allografts is excellent. Host bone fracture is the predominant complication; however, none of these fractures necessitated allograft removal in our series. The extent of resection is the most important risk factor for complications. Hemicortical resection is not recommended for high-grade lesions; however, it may be superior to segmental resection for treatment of carefully selected tumors, provided that it is possible to obtain adequate margins.

## Introduction

The ability to accurately stage primary bone tumors has improved dramatically during recent decades, mainly because of progression of preoperative imaging techniques<sup>1,2</sup>. Concomitant advances in surgical techniques gave rise to the idea that segmental resection may not always be necessary to adequately excise primary tumors of the long bones<sup>3</sup>.

Bone tumors frequently arise in close proximity to joints, commonly necessitating resection of adjacent joints. Osteoarticular allografts, allograft-prosthetic composites, or endoprostheses may then be used for joint replacement. Endoprostheses are generally considered the gold standard, although recent literature describes relatively high short and long-term revision rates due to infection, component wear, and loosening<sup>4,5</sup>. If the adjacent joint can be salvaged and a segmental resection is performed, vascularized fibular autografts or intercalary allografts may be used. Autografts, however, can cause donor-site morbidity and, until solid union is achieved, are at substantial risk for fracture. Therefore, long non-weight-bearing periods are required<sup>6</sup>. Intercalary allografts offer superior initial stability, but demonstrate high rates of nonunion (27% to 47%), fracture (16% to 29%), and infection (1% to 14%), causing failures in 14% to 24% of cases<sup>7-10</sup>.

Compared with the aforementioned techniques, hemicortical resection offers potential advantages, including preservation of joints, bone stock, and cortical continuity. It may result in lower complication rates and allow faster and more complete rehabilitation<sup>3,11,12</sup>. Various reconstructive techniques have been described, including implantation of cortical allografts, autografts, and autologous iliac crest grafts<sup>3,11-15</sup>. Allografts have been most commonly used, but there is a lack of studies of large series with such reconstructions.

Most reports on hemicortical resection focused on treatment of low-grade and surface tumors of bone, such as parosteal osteosarcoma, adamantinoma, and peripheral chondrosarcoma<sup>3,11,12,14,15</sup>. More recently, authors have described experiences with limited resection of high-grade lesions<sup>13,16</sup>. The authors of most studies on hemicortical resection of bone tumors reported that no recurrences occurred<sup>3,11-15</sup>. However, they described small case series that mostly lacked long-term follow-up, and low-grade tumors may recur years after surgery<sup>17-20</sup>.

The aims of our study were to evaluate (1) mechanical complications and infection, (2) oncological outcome, and (3) failures and allograft survival after hemicortical resection and subsequent allograft reconstruction in patients treated for a primary tumor of a long bone.



## Materials and Methods

To identify patients who were eligible for this nationwide retrospective study, we searched an electronic database of our national bone bank for massive allografts that had been delivered to all four appointed centers of orthopaedic oncology from 1989 to 2012. We then evaluated the diagnosis and procedure information of the patients who had received the grafts, and all of those who had been treated for a primary tumor of a long bone with hemicortical resection and allograft reconstruction were included. The minimum duration of follow-up was 24 months.

Allografts were harvested under sterile conditions during postmortem tissue donation and stored at  $-80^{\circ}\text{C}$  afterward<sup>21</sup>. Grafts were processed by either Osteotech (Eatontown, New Jersey) or the Musculoskeletal Transplant Foundation (Edison, New Jersey) and either not subjected to additional sterilization or sterilized with low-dose gamma radiation ( $<25$  kGy). In most patients, biopsies were performed to obtain a histological diagnosis and the biopsy track was excised in continuity with the tumor. A wedge resection was performed in all patients — in some cases because of an atypical presentation or unclear diagnosis preoperatively. Resections were planned with use of an array of conventional radiographs, magnetic resonance imaging (MRI) scans, and computed tomography (CT) scans. All patients received prophylactic cephalosporins prior to surgery. Allografts were thawed in saline solution with antibiotics during the resection and subsequently cut to fit the resected defect. Osteosynthesis was performed if the reconstruction was not considered intrinsically stable.

Medical files were evaluated to obtain characteristics of the patients, tumors, surgery, reconstruction, and treatment. Tumor grade was stratified into four groups: benign, low-grade malignant, intermediate-grade malignant, and high-grade malignant. Surgical margins were defined as being adequate (marginal or wide with no tumor cells at the margins)<sup>22</sup>, questionable (the pathologist in doubt about whether there were tumor cells at the margins), or intralesional. The reconstruction length and the percentage of the cortical circumference that was resected were measured on conventional radiographs in two directions and corrected for magnification. The extent of cortical resection was classified as  $<25\%$ ,  $25\%$  to  $50\%$ ,  $51\%$  to  $75\%$ , or  $>75\%$ .

Complications and reasons for failure were classified as mechanical (nonunion or fracture), infection, and oncological according to the system described by Henderson *et al*<sup>23</sup>. A patient was considered to have had a nonunion if a surgical intervention had been performed to facilitate osseous union<sup>7</sup>. Fractures were



diagnosed on images or intraoperatively. A patient was considered to have had an infection if any surgical procedure had been done to treat a deep infectious process around the allograft. Allografts that were partially or completely removed for any reason were defined as failures. The presence of residual or recurrent tumor and metastases was assessed on radiographic images, and on pathology reports if surgery was performed. Before 2006, routine radiographic follow-up was done with conventional radiographs and MRI was performed when recurrence was suspected. From 2006 onward, malignant lesions were followed according to national guidelines that included MRI at one, two, five, and ten years.

Student t tests and Mann-Whitney U tests were used to compare continuous variables between groups. Kaplan-Meier curves were used to estimate construct survival. Logistic and Cox regression analyses were performed to assess factors of influence on the occurrence of complications and time to failure. Outcomes are expressed with the odds ratio and hazard ratio (OR and HR), 95% confidence interval (95% CI), and p-value. A 5% level of significance was used in the analyses.

## Results

We included 111 patients (44 males; 40%) with a median age of 28 years (7 to 73) at surgery (table 1). Ninety (81%) were treated at one center and seven (6%) were treated at each of the other centers. The resected specimen revealed a diagnosis other than a neoplasm in three patients (3%) — reactive bone and cartilage formation in two and bizarre parosteal osteochondromatous proliferation in one — all of whom had been suspected of having parosteal osteosarcoma preoperatively. Eleven patients (10%) had a benign tumor and 97 had a malignant tumor, which was low-grade in 61 (55%), intermediate-grade in 22 (20%), and high-grade in 14 (13%). The predominant diagnoses were adamantinoma ( $n = 37$ ; 33%) and parosteal osteosarcoma ( $n = 18$ ; 16%). Computer-assisted navigation was used in five patients (5%). Twelve patients (11%) received chemotherapy, and six (5%) underwent radiation therapy.

At the time of the review, 104 patients (94%) were alive after a median duration of follow-up of 6.7 years (2 to 23). Seven patients (6%) had died during the follow-up period, at a median of 26 months (7 months to 6.4 years) postoperatively. Six of these deaths were due to disease (two Ewing sarcomas, two grade 2 chondrosarcomas, one osteosarcoma, and one periosteal osteosarcoma).



Most lesions were located in the tibia ( $n = 54$ ; 49%) (figures 1A, 1B, and 1C) or femur ( $n = 48$ ; 43%) (figures 2A, 2B, and 2C). Forty-four (40%) extended from metaphyseal into diaphyseal bone, and 40 (36%) were strictly diaphyseal. The median length of the reconstruction was 8 cm (2 to 20). In most cases, <25% ( $n = 46$ ; 41%) or 25% to 50% ( $n = 46$ ; 41%) of the cortical circumference was resected. The mean surgical duration was 3.0 hours (standard deviation [SD] = 1.7 hours).

Allografts were laid into the defect with cortical contact and fixed under compression, with the use of screws in 78 (70%) of the patients and a plate with or without additional lag screws in 20 (18%), 15 of whom had a femoral reconstruction. Plate fixation was applied significantly more often in reconstructions of the femur ( $p = 0.002$ ). No osteosynthesis was applied to 11 allografts (10%), eight of which were <8 cm in length and all of which comprised <25% of the cortex. Seventy-eight patients (70%) had additional bone grafting, with either allogeneic ( $n = 73$ ; 66%) or autologous ( $n = 5$ ; 5%) bone, to obtain an optimal fit.

**Table 1.** Study data

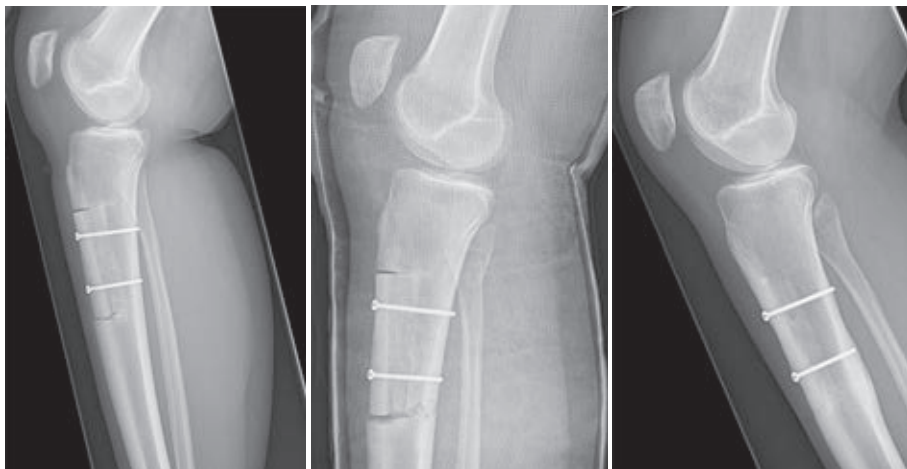
	No.	%
<i>Sex</i>		
Male	44	40
Female	67	60
<i>Diagnosis</i>		
Adamantinoma	37	33
Parosteal osteosarcoma	18	16
Periosteal chondrosarcoma	8	7
Chondrosarcoma, grade 1	7	6
Chondrosarcoma, grade 2	6	5
Osteosarcoma (conventional type)	6	5
Periosteal osteosarcoma	6	5
Chondromyxoid fibroma	2	2
Ewing sarcoma	2	2
Giant cell tumor of bone	2	2
High-grade surface osteosarcoma	2	2
Leiomyosarcoma	2	2
Osteoblastoma	2	2
Reactive bone and cartilage formation	2	2
Aneurysmal bone cyst	1	1
Bizarre parosteal osteochondromatous proliferation	1	1
Hemangioma	1	1
Low-grade osteosarcoma	1	1
Non-ossifying fibroma	1	1
Osteochondroma	1	1
Osteofibrous dysplasia	1	1
Sarcoma not otherwise specified	1	1
Synovial sarcoma	1	1

Table 1. continued

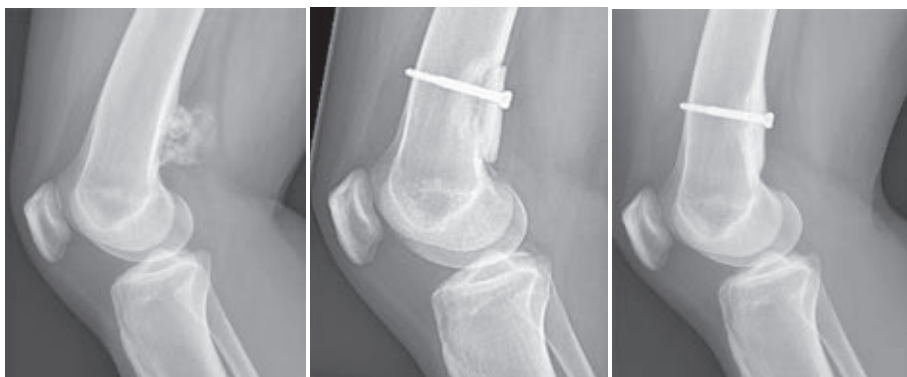	No.	%
<i>Long bone involved by tumor</i>		
Tibia	54	49
Femur	48	43
Humerus	5	5
Radius	2	2
Ulna	2	2
<i>Portion of bone involved by tumor</i>		
Metaphysis-diaphysis	44	40
Diaphysis	40	36
Metaphysis	17	15
Epiphysis-metaphysis	6	5
Epiphysis-diaphysis	4	4
<i>Graft length</i>		
<4 cm	7	6
4 – 7.9 cm	41	37
8 – 12 cm	45	41
>12 cm	18	16
<i>Cortical circumference resected</i>		
<25%	46	41
25%-50%	46	41
51%-75%	13	12
>75%	6	5
<i>Osteosynthesis</i>		
Screws	78	70
Plate	16	14
None (press-fit)	11	10
Plate and screws	4	4
Cerclage wires	2	2
<i>Adjuvant therapy</i>		
Chemotherapy	12	11
Radiation therapy	6	5
<i>Complications of the reconstruction</i>		
Fracture of host bone	20	18
Infection	8	7
Nonunion	8	7
Allograft fracture	3	3
<i>Patients with ≥ 1 reoperation(s)</i>	41	37
<i>Failures</i>		
Mechanical reasons	2	2
Non-mechanical reasons	13	12
<i>Follow-up</i>		
≥5 years	70*	63
≥10 years	31	28

\*Includes the 31 patients with ten or more years of follow-up.





**Figures 1A-C.** Lateral radiographs of a 17-year-old girl diagnosed with an adamantinoma of the tibia. (1A) Radiograph made six weeks after resection of the anterior portion of the tibia and reconstruction with a 9-cm-long inlay allograft fixed to the host bone with two screws. (1B) Two weeks later, the remaining cortex fractured at the level of the distal osteotomy site and was treated conservatively with a cast. (1C) Radiograph of the affected leg made 30 months after the index surgery. The fracture healed uneventfully, and there is sound incorporation at both osteotomy sites.



**Figures 2A-C.** Lateral radiographs of a 24-year-old woman diagnosed with a periosteal chondrosarcoma. (2A) Preoperative radiograph showing a lesion, with alternating osteolytic and sclerotic areas, in close relationship with the dorsal cortex of the distal part of the femur. (2B) Three months after resection of the tumor and fixation of an allograft to the host bone with a single screw, there are no clear signs of allograft incorporation. (2C) Four years after the index procedure, there is sound incorporation of the allograft.

## Mechanical Complications and Infection

Thirty-seven patients (33%) had a mechanical complication or infection (Henderson type 1, 2, 3, or 4 complication<sup>23</sup>). Forty-one patients (37%) required one or more reoperations (1 to 7). Patients experienced their first complication after a median of 11 months (one day to 8.6 years) and their last after a median of 15 months (1 day to 20.0 years).

Non-oncological complication rates were comparable among different tumor locations ( $p = 0.24$ ), between reconstructions with and those without osteosynthesis ( $p = 0.26$ ), among fixation methods ( $p = 0.62$ ), and between procedures that took place before ( $n = 23$ ; 21%) and those that took place after 1995 ( $p = 0.84$ ). Osteosynthesis materials were removed because of pain or irritation in seven patients (6%). Complication rates were higher after reconstructions of  $\geq 8$  cm (OR = 2.0) and increased with the extent of the cortical resection (table 2). The extent of resection retained its significance in multivariable analysis (table 3).

**Table 2.** Univariable analysis for factors of influence on the occurrence of complications.

Complications and covariable(s)	OR	95% CI	p-value
<i>All non-oncological complications (types I-IV) (n = 37; 33%)</i>			
Reconstruction length $\geq 8$ cm	2.9	1.2 - 6.7	0.02
% of cortical circumference resected			
<25% (reference)	(1)		
25%-50%	3.3	1.3 - 8.8	0.01
51%-75%	4.1	1.1 - 15.4	0.04
>75%	9.5	1.5 - 61.1	0.02
<i>Mechanical: fracture of host cortex (n = 20; 18%)</i>			
Reconstruction length $\geq 8$ cm	5.5	1.5 - 20.2	0.01
% of cortical circumference resected			
<25% (reference)	(1)		
25%-50%	6.9	1.4 - 33.3	0.02
51%-75%	9.8	1.5 - 61.7	0.02
>75%	22.0	2.6 - 186.5	0.005
Nonunion of allograft-host junctions	9.8	2.1 - 45.3	0.004
<i>Mechanical: nonunion of allograft-host junctions (n = 8; 7%)</i>			
Reconstruction length $\geq 8$ cm	5.9	0.7 - 49.5	0.10
<i>Non-mechanical: infection (n = 8; 7%)</i>			
Reconstruction of tibial diaphysis	4.2	1.0 - 18.0	0.06
>50% of cortical circumference resected	9.8	2.1 - 45.3	0.004
<i>Non-mechanical: residual or recurrent tumor (n = 15; 15%*)</i>			
Inadequate margins	14.4	4.1 - 50.8	<0.001

\*Of the 97 patients with a malignant lesion.

Host bone fracture was the most frequent complication ( $n = 20$ ; 18%). Three of these fractures (two in the femur and one in the tibia) occurred during the index surgery and 17 (ten in the tibia, six in the femur, and one in the radius) occurred at a median of eight weeks (1 day to 5.8 years) postoperatively. Two patients (2%) had a concomitant allograft fracture. One patient (1%) had an isolated fissure fracture

of the allograft during the primary surgery. Fractures were treated conservatively or with internal ( $n = 9$ ) or external ( $n = 1$ ) fixation; all healed uneventfully. Of the 20 patients with a host bone fracture, 17 had had a reconstruction of  $\geq 8$  cm and four had had plate fixation. In univariable analysis, reconstruction length of  $\geq 8$  cm ( $OR = 5.5$ ), nonunion ( $OR = 9.8$ ), and the extent of cortical resection significantly influenced the risk of host bone fracture (table 2). In multivariable analysis, nonunion and the extent of resection retained significance (table 3).

Nonunion occurred in eight patients (7%). Five (5%) underwent revision of the osteosynthesis, combined with allogeneic bone grafting ( $n = 2$ ), allogeneic and autologous bone grafting ( $n = 2$ ), or tibial autografting ( $n = 1$ ). Nonunion resulted in graft failure in two of the patients, five and 24 months after the index procedure. Of the eight patients with nonunion, two received chemotherapy ( $p = 0.20$ ) and one had radiation therapy ( $p = 0.38$ ). The nonunion risk was higher for reconstructions of  $\geq 8$  cm in length ( $OR = 5.9$ ) but this was not a significant factor (table 2).

Deep infection developed after eight reconstructions (7%), five in the tibia, two in the femur, and one in the radius. Three infections (3%) were eradicated with surgical debridement and antibiotics, and the other five resulted in graft failure (5%): two within the first postoperative month and one each after eight, 33, and 34 months. The mean duration of surgery for the patients with an infection was 3.9 hours ( $SD = 3.6$  hours) compared with 2.9 hours ( $SD = 1.5$  hours) for those without an infection ( $p = 0.10$ ). Reconstructions of the tibial diaphysis ( $OR = 4.2$ ) and those comprising  $>50\%$  of the cortical circumference ( $OR = 9.8$ ) were associated with a significantly higher risk of infection (table 2).

## Oncological Outcome

The margins obtained during excision of the eleven benign lesions were adequate in seven, questionable in two (one patient had additional cryosurgery), and intralesional in two (one patient had cryosurgery and one had phenolization), but clear margins were not the aim in all patients.

Of the 97 patients with a malignant lesion, ten (10%) had questionable margins and ten (10%) had an intralesional resection (table 4). The rates of inadequate margins were comparable among the grades of malignancy ( $p = 0.36$ ). All computer-navigated resections resulted in adequate osseous margins, but there was one contaminated soft-tissue margin. Residual or recurrent tumor was diagnosed in 15 (15%) of the 97 patients with a malignant tumor, after a median of 12 months (1 day to 13 years). Of the 61 patients with a low-grade malignant tumor,

**Table 3.** Multivariable analysis for factors of influence on the occurrence of complications.

Complications and covariable(s)	OR	95% CI	p-value
<i>All non-oncological complications (types I-IV) (n = 37; 33%)</i>			
Reconstruction length ≥8 cm	1.6	0.6 - 4.3	0.33
% of cortical circumference resected			
<25% (reference)	(1)		
25%-50%	2.7	1.0 - 7.4	0.06
51%-75%	3.1	0.7 - 12.5	0.12
>75%	6.1	0.9 - 43.8	0.07
<i>Fracture of host cortex (n = 20; 18%)</i>			
Reconstruction length ≥8 cm	2.4	0.6 - 10.2	0.23
% of cortical circumference resected			
<25% (reference)	(1)		
25%-50%	4.4	0.8 - 23.4	0.08
51%-75%	5.2	0.7 - 38.8	0.11
>75%	15.1	1.5 - 146.5	0.02
Nonunion of allograft-host junctions	7.5	1.5 - 37.9	0.02

16% (n = 10 — five with an adamantinoma, four with a parosteal osteosarcoma, and one with a grade 1 chondrosarcoma) had residual or recurrent tumor during the follow-up period. Of the 22 with an intermediate-grade malignancy, 9% (two — both with grade 2 chondrosarcoma) had residual or recurrent tumor, and the rate was 21% (three — Ewing sarcoma, leiomyosarcoma, and conventional osteosarcoma) in the 14 with a high-grade malignancy. For the 97 patients with a malignant lesion, the risk of experiencing a residual or recurrent tumor was significantly higher if adequate margins had not been obtained during the index procedure (OR = 14.4) (table 2). All patients with residual or recurrent tumor had secondary surgery. In seven (6%) of the 97 patients, the residual or recurrent tumor was resected without violating the reconstruction: four soft-tissue recurrences, two recurrences in the same bone but outside the allograft, and one residual tumor (a parosteal osteosarcoma, diagnosed on imaging one day postoperatively, after resection the allograft was put back in place). In the remaining eight patients (8%), the allograft was removed, after a median of 17 months (7 months to 13 years); four had a secondary reconstruction and four underwent an ablative procedure (figure 3).

Metastasis was diagnosed in six patients (6% of the patients with a malignant lesion), two with grade 2 chondrosarcoma, two with Ewing sarcoma, one with leiomyosarcoma, and one with periosteal osteosarcoma, after a median of 15 months (2 to 47).



**Table 4.** Residual or recurrent malignant tumors and ablative surgery, stratified according to grade of malignancy and surgical margins.

Grade of malignancy and margins obtained	Total		Residual or recurrent malignant tumor		Ablative surgery	
	No.	%	No.	%	No.	%
<b>Low-grade</b>	61	100	10	16	1	2
Adequate	50	82	4	8	1	2
Questionable	4	7	1	25	0	-
Intralesional	7†	11	5	71	0	-
<b>Intermediate-grade</b>	22	100	2	9	1	5
Adequate	16	73	0	-	-	-
Questionable	5	23	1	20	0	-
Intralesional	1	5	1	100	1	100
<b>High-grade</b>	14	100	3	21	3	21
Adequate	11	79	1	9	1‡	9
Questionable	1	7	1	100	1	100
Intralesional	2	14	1	50	1	50

\*The percentage of the corresponding group (with equal tumor grade and surgical margins). †One of these patients underwent secondary surgery due to an infection of the allograft; in the same procedure, an additional piece of bone was removed at the contaminated osteotomy site. ‡No attempt was made to resect the recurrent tumor; a below-the-knee amputation was performed because of a concomitant infection.

## Failures and Allograft Survival

Fifteen allografts (14%) were removed: two (2%) for mechanical reasons (both nonunion), five (5%) because of infection, and eight because of residual or recurrent tumor (8% of the patients with a neoplasm). Fourteen failures occurred within three years postoperatively, and the remaining patient had a recurrence after 13 years. With failure for any reason as the end point, estimated two- and ten-year allograft survival rates were 92% and 87%, respectively (figure 4). Allograft survival was significantly worse for patients with an infection (HR = 10.4, 95% CI = 3.5 to 31.2,  $p < 0.001$ ).

Ablative procedures were performed to treat four residual or recurrent tumors and one infection. The overall limb-salvage rate was 95% ( $n = 106$ ). Ablative procedures were more frequent in patients with a high-grade lesion (OR = 13.0, 95% CI = 1.9 to 86.2,  $p = 0.008$ ); for them, the limb-salvage rate was 79% (11 of 14).



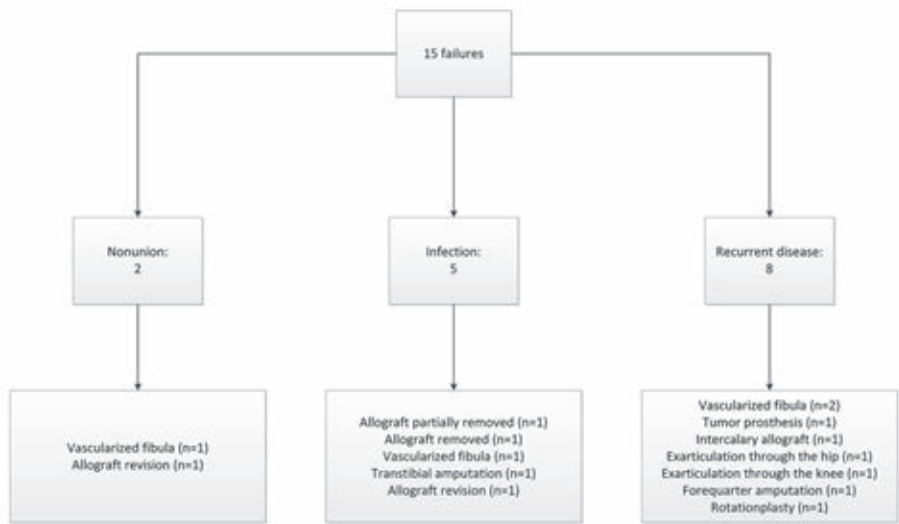


Figure 3. Failed reconstructions, with the reasons for failure and the final outcomes.

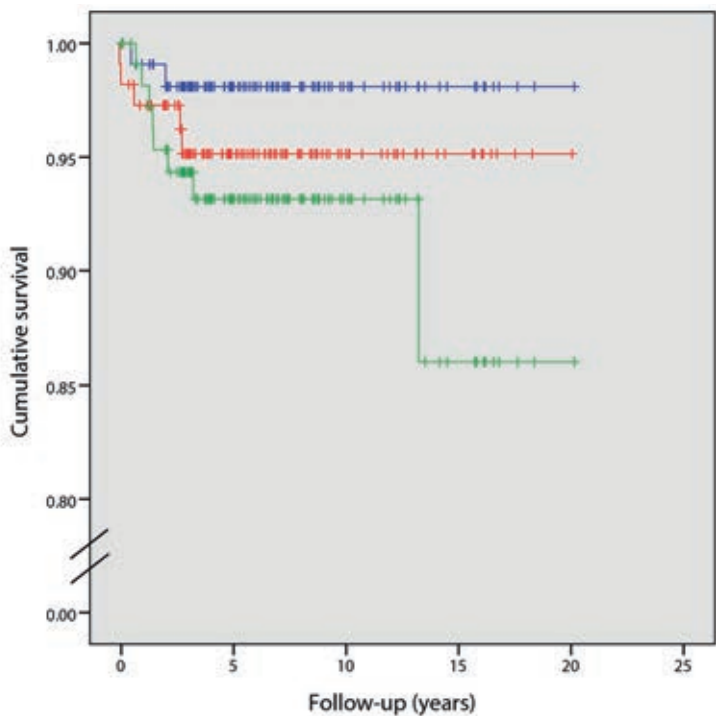


Figure 4. Kaplan-Meier curve for survival of the reconstruction, with failure for mechanical reasons (nonunion or fracture) as the end point (blue line), failure due to infection as the end point (red line), and failure due to locally recurrent or residual tumor as the end point (green line).

## Discussion

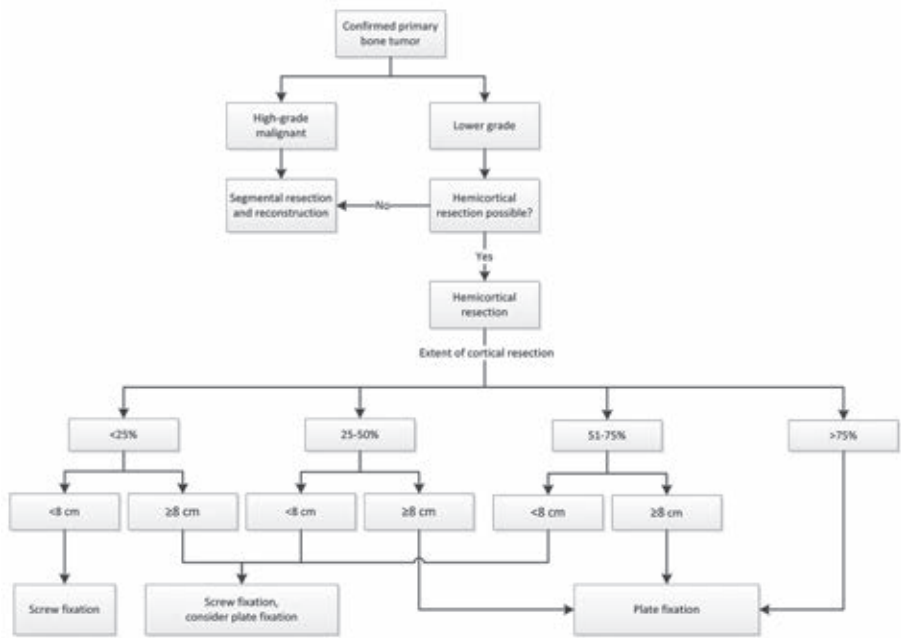
In this nationwide retrospective survey, we evaluated (1) mechanical complications and infection, (2) oncological outcome, and (3) failures and allograft survival following hemicortical allograft reconstructions for the treatment of primary bone tumors. To the best of our knowledge, this study represents the largest series on hemicortical reconstructions to date.

### Mechanical Complications and Infection

The most frequent complication was host bone fracture, the rate of which was 18%, which is in accordance with rates of 10% to 27% found in previous studies on hemicortical resection (table 5)<sup>3,11,15</sup>. Other authors reported no fractures, but they did not describe the extent of cortical resection, which was the most important risk factor in our patients<sup>12-14,24</sup>. The association between fractures and the extent of cortical resection may be explained by greater stresses acting on a smaller portion of remaining cortex<sup>25</sup>. Additional factors should, however, be considered. First, perfect fitting of allografts may reduce fracture rates<sup>26</sup>. Three-dimensional CT scanning of allografts<sup>27</sup> may aid in the selection of better-fitting grafts. Second, osteotomies with sharp angles and screw fixation perpendicular to the bone axis (figures 1A, 1B, and 1C) act as stress-risers and should be avoided<sup>28,29</sup>. We advise surgeons to perform rounded osteotomies ("boat-shaped resections") when possible and to insert screws in an oblique fashion<sup>29,30</sup>. Recommendations for when to use plate fixation are proposed in figure 5.

Nonunion occurred in 7% of our patients, and resulted in failure in 2%. In previous reports, none of the patients required surgery to facilitate union (table 5). Autograft use may improve union rates, but it is not suitable for reconstruction of larger defects. Also, harvesting of autografts has been associated with substantial complication rates, especially prolonged pain at the donor site<sup>31-33</sup>. On the other hand, 24% to 47% of segmental allografts demonstrate nonunion so the rate in the current study may be considered encouraging<sup>7-10</sup>. Various factors may explain these differences, including the fact that hemicortical reconstructions have a larger contact surface between allogeneic and host bone. The extent of soft-tissue dissection is generally limited in hemicortical resections; authors have hypothesized that this provides a superior environment for incorporation<sup>3,28</sup>. Moreover, the number of patients receiving adjuvant radiation or chemotherapy was limited in our study. Adjuvant therapies are known to delay bone-healing<sup>34</sup>.

Our infection rate (7%) compares unfavorably with those in previous studies in which no infections were reported (table 5). On the other hand, infection rates after segmental allograft or endoprosthetic reconstructions typically range around 10%<sup>7,9,35-37</sup>. Infection resulted in graft removal in five patients (four of whom were managed with a new biological reconstruction) in our series. The higher risk of infection following reconstructions of the tibial diaphysis may be explained by limited possibilities for soft-tissue coverage<sup>38</sup>. We did not use muscle flaps; however, muscle transfers may be useful to reduce the risk of infection in these cases<sup>39</sup>. The infection rate was associated with the extent of cortical resection; it is conceivable that extensive resections require more soft-tissue dissection and take longer, thereby increasing the infection risk<sup>40</sup>.



**Figure 5.** Recommendations for treatment of primary bone tumors and fixation of hemicortical allografts.

**Oncological Outcome**

Most recurrences involved adamantinomas and parosteal osteosarcomas. These lesions recur frequently, especially after intralesional or marginal excision<sup>19,41-43</sup>. Until recent years, we routinely performed subperiosteal resections for these

tumors. We no longer employ this technique because we assume that it results in a higher recurrence rate. The advantages of limited resection may outweigh the elevated risk of recurrence for low-grade lesions; however, 21% (three) of the 14 high-grade lesions in our series recurred and all resulted in ablative surgery. Apparently, hemicortical resection does not provide adequate local control of high-grade lesions. We therefore recommend segmental *en bloc* resections for high-grade tumors (figure 5).

Computer-assisted navigation may prove useful for resecting tumors with minimal but adequate margins. All osseous margins obtained with computer-navigated resection were adequate. Several authors have shown that computer navigation is accurate and useful for bone tumor surgery<sup>44,45</sup>. Computer navigation may also be used to obtain precise matching of host and allograft osteotomies and thus superior fit<sup>26,46</sup>.

### Failures and Allograft Survival

Nearly all reconstruction failures occurred in the first three postoperative years. This finding is in accordance with statements in previous reports that allografts offer a reliable and lasting reconstruction if they survive the first critical years<sup>9,47,48</sup>. The ten-year allograft survival rate (87%) in our series compares favorably with ten-year survival rates of 58% to 69% reported in large series on endoprosthetic reconstructions after resections of bone tumors<sup>4,49,50</sup>. In those series, however, the majority of patients had high-grade malignant tumors and thus, presumably, more extensive resections. As those patients would not have been considered eligible for hemicortical resection, the results are difficult to compare.

### Study Limitations

Our study had several limitations. As a result of its retrospective design, it was not possible for us to accurately assess time to union of allograft-host junctions. We were also unable to acquire functional outcome scores. Previous research, however, indicates that postoperative function is generally good after hemicortical reconstruction<sup>3</sup>.

### Overview

In conclusion, we report excellent long-term rates of survival of hemicortical allograft reconstructions. Rates of non-oncological complications were acceptable, especially after reconstructions comprising <25% of the cortical circumference

and those <8 cm in length. Hemicortical resection is not recommended for high-grade lesions. The elevated risk of residual or recurrent tumor may, however, be acceptable for low and intermediate-grade lesions, given the excellent mechanical complication rates and the fact that most failures can be managed with a second (limb-salvaging) procedure. Modern imaging techniques play a pivotal role in ensuring that clear margins are obtained. If the aforementioned requirements are met, hemicortical resection and allograft reconstruction is a safe and reliable alternative to more comprehensive segmental resections.

*Note: the authors gratefully acknowledge Prof. A.H.M. Taminiau, emeritus professor at the Department of Orthopaedic Surgery of the Leiden University Medical Center, for operating on a substantial number of the patients included in this study.*



**Table 5.** Overview of literature on hemicortical resections and reconstructions.

Year	Deijkers et al <sup>3</sup>	Agarwal et al <sup>11</sup>	Liu et al <sup>15</sup>	Funovics et al <sup>12</sup>	Lewis et al <sup>14</sup>	Chen et al <sup>13</sup>	Lindner et al <sup>24</sup>	Current study
No. of patients	22	10	13	8†	6	6	4	111
Diagnoses (%)								
Benign	-	-	-	-	-	-	-	13
Low-grade malignant	100	90	100	100	100	-	100	55
Intermediate-grade malignant	-	-	-	-	-	-	-	20
High-grade malignant	-	10	-	-	-	100	-	13
Long bone involved by tumor (%)								
Humerus	9	10	-	-	-	-	-	5
Ulna	-	-	-	-	-	-	-	2
Radius	-	10	-	-	-	-	-	2
Femur	45	60	100	88	100	17	100	43
Tibia	45	20	-	13	-	83	-	49
Intralesional excisions (%)	-	-	-	25	-	-	25	11
Reconstruction (%)								
Allograft	100	50	-	25	100	33	-	100
Autograft	-	30	100	25	-	67	100	-
Autogenous iliac crest	-	20	-	50	-	-	-	-
Mean follow-up (range) (mo)	64 (27 - 135)	51 (40 - 61)	102 (58 - 142)	107 (14 - 289)	51 (38 - 63)	52 (24 - 96)	88 (20 - 161)	89 (8 - 274)
Mean reconstruction length (range) (cm)	11 (6 - 20)	10 (4-16)	11 (8 - 13)	NR	NR	NR	NR	9 (2 - 20)
Infection (%)	-	-	NR	13	-	-	-	7
Fracture of host bone (%)	27	10	15	-	-	-	-	18
Allograft fracture (%)	-	-	NR	-	-	-	-	3
Nonunion (%)	-	-	-	-	-	-	-	7
Residual / recurrent tumor (%)	-	-	8	13	-	-	-	14
Failure (%)	-	-	-	13	-	-	-	14

\*NR = not reported. †The study population comprised twenty-eight patients, but only eight had hemicortical resection. The results in this table refer to those patients only.

## References

1. Bloem JL, Taminiau AH, Eulderink F, Hermans J, Pauwels EK. Radiologic staging of primary bone sarcoma: MR imaging, scintigraphy, angiography, and CT correlated with pathologic examination. *Radiology*. 1988 Dec;169(3):805-10. Epub 1988/12/01.
2. Enneking WF. An abbreviated history of orthopaedic oncology in North America. *Clinical orthopaedics and related research*. 2000 May(374):115-24. Epub 2000/05/20.
3. Deijkers RL, Bloem RM, Hogendoorn PC, Verlaan JJ, Kroon HM, Taminiau AH. Hemicortical allograft reconstruction after resection of low-grade malignant bone tumours. *The Journal of bone and joint surgery British volume*. 2002 Sep;84(7):1009-14. Epub 2002/10/03.
4. Jeys LM, Kulkarni A, Grimer RJ, Carter SR, Tillman RM, Abudu A. Endoprosthetic reconstruction for the treatment of musculoskeletal tumors of the appendicular skeleton and pelvis. *The Journal of bone and joint surgery American volume*. 2008 Jun;90(6):1265-71. Epub 2008/06/04.
5. Gosheger G, Gebert C, Ahrens H, Streithuenger A, Winkelmann W, Harnes J. Endoprosthetic reconstruction in 250 patients with sarcoma. *Clinical orthopaedics and related research*. 2006 Sep;450:164-71. Epub 2006/05/13.
6. Zaretski A, Amir A, Meller I, Leshem D, Kollender Y, Barnea Y, et al. Free fibula long bone reconstruction in orthopedic oncology: a surgical algorithm for reconstructive options. *Plastic and reconstructive surgery*. 2004 Jun;90(6):1265-71. Epub 2004/07/16.
7. Bus MP, Dijkstra PD, van de Sande MA, Taminiau AH, Schreuder HW, Jutte PC, et al. Intercalary allograft reconstructions following resection of primary bone tumors: a nationwide multicenter study. *The Journal of bone and joint surgery American volume*. 2014 Feb 19;96(4):e26. Epub 2014/02/21.
8. Frisoni T, Cevelani L, Giorgini A, Dozza B, Donati DM. Factors affecting outcome of massive intercalary bone allografts in the treatment of tumours of the femur. *The Journal of bone and joint surgery British volume*. 2012 Jun;94(6):836-41. Epub 2012/05/26.
9. Ortiz-Cruz E, Gebhardt MC, Jennings LC, Springfield DS, Mankin HJ. The results of transplantation of intercalary allografts after resection of tumors. A long-term follow-up study. *The Journal of bone and joint surgery American volume*. 1997 Jan;79(1):97-106. Epub 1997/01/01.
10. Aponte-Tinco L, Farfalli GL, Ritacco LE, Ayerza MA, Muscolo DL. Intercalary femur allografts are an acceptable alternative after tumor resection. *Clinical orthopaedics and related research*. 2012 Mar;470(3):728-34. Epub 2011/06/22.
11. Agarwal M, Puri A, Anchan C, Shah M, Jambhekar N. Hemicortical excision for low-grade selected surface sarcomas of bone. *Clinical orthopaedics and related research*. 2007 Jun;459:161-6. Epub 2007/04/07.
12. Funovics PT, Bucher F, Toma CD, Kotz RJ, Dominkus M. Treatment and outcome of parosteal osteosarcoma: biological versus endoprosthetic reconstruction. *Journal of surgical oncology*. 2011 Jun;103(8):782-9. Epub 2011/01/18.
13. Chen WM, Wu PK, Chen CF, Chung LH, Liu CL, Chen TH. High-grade osteosarcoma treated with hemicortical resection and biological reconstruction. *Journal of surgical oncology*. 2012 Jun 15;105(8):825-9. Epub 2012/01/04.
14. Lewis VO, Gebhardt MC, Springfield DS. Parosteal osteosarcoma of the posterior aspect of the distal part of the femur. Oncological and functional results following a new resection technique. *The Journal of bone and joint surgery American volume*. 2000 Aug;82-a(8):1083-8. Epub 2000/08/23.
15. Liu T, Liu ZY, Zhang Q, Zhang XS. Hemicortical resection and reconstruction using pasteurised autograft for parosteal osteosarcoma of the distal femur. *The bone & joint journal*. 2013 Sep;95-b(9):1275-9. Epub 2013/09/03.
16. Avedian RS, Haydon RC, Peabody TD. Multiplanar osteotomy with limited wide margins: a tissue preserving surgical technique for high-grade bone sarcomas. *Clinical orthopaedics and related research*. 2010 Oct;468(10):2754-64. Epub 2010/04/27.
17. Filippou DK, Papadopoulos V, Kiparidou E, Demertzis NT. Adamantinoma of tibia: a case of late local recurrence along with lung metastases. *Journal of postgraduate medicine*. 2003 Jan-Mar;49(1):75-7. Epub 2003/07/17.
18. Rose PS, Dickey ID, Wenger DE, Unni KK, Sim FH. Periosteal osteosarcoma: long-term outcome and risk of late recurrence. *Clinical orthopaedics and related research*. 2006 Dec;453:314-7. Epub 2006/08/15.

19. Hazelbag HM, Taminiau AH, Fleuren GJ, Hogendoorn PC. Adamantinoma of the long bones. A clinicopathological study of thirty-two patients with emphasis on histological subtype, precursor lesion, and biological behavior. *The Journal of bone and joint surgery American volume*. 1994 Oct;76(10):1482-99. Epub 1994/10/01.
20. Gelderblom H, Hogendoorn PC, Dijkstra SD, van Rijswijk CS, Krol AD, Taminiau AH, et al. The clinical approach towards chondrosarcoma. *The oncologist*. 2008 Mar;13(3):320-9. Epub 2008/04/02.
21. Deijkers RL, Bloem RM, Petit PL, Brand R, Vehmeyer SB, Veen MR. Contamination of bone allografts: analysis of incidence and predisposing factors. *The Journal of bone and joint surgery British volume*. 1997 Jan;79(1):161-6. Epub 1997/01/01.
22. Grimer RJ, Taminiau AM, Cannon SR. Surgical outcomes in osteosarcoma. *The Journal of bone and joint surgery British volume*. 2002 Apr;84(3):395-400. Epub 2002/05/11.
23. Henderson ER, Groundland JS, Pala E, Dennis JA, Wooten R, Cheong D, et al. Failure mode classification for tumor endoprostheses: retrospective review of five institutions and a literature review. *The Journal of bone and joint surgery American volume*. 2011 Mar 2;93(5):418-29. Epub 2011/03/04.
24. Lindner N, Ozaki T, Hillmann A, Blasius S, Winkelmann W. Adjuvant local treatment of parosteal osteosarcoma. *International orthopaedics*. 1996;20(4):233-6. Epub 1996/01/01.
25. Elias JJ, Frassica FJ, Chao EY. The open section effect in a long bone with a longitudinal defect - a theoretical modeling study. *Journal of biomechanics*. 2000 Nov;33(11):1517-22. Epub 2000/08/15.
26. Aponte-Tinao L, Ritacco LE, Ayerza MA, Luis Muscolo D, Albergo JI, Farfall GL. Does Intraoperative Navigation Assistance Improve Bone Tumor Resection and Allograft Reconstruction Results? *Clinical orthopaedics and related research*. 2014 Apr 8. Epub 2014/04/09.
27. Ritacco LE, Farfalli GL, Milano FE, Ayerza MA, Muscolo DL, Aponte-Tinao L. Three-dimensional virtual bone bank system workflow for structural bone allograft selection: a technical report. *Sarcoma*. 2013;2013:524395. Epub 2013/05/22.
28. Cascio BM, Thomas KA, Wilson SC. A mechanical comparison and review of transverse, step-cut, and sigmoid osteotomies. *Clinical orthopaedics and related research*. 2003 Jun(411):296-304. Epub 2003/06/05.
29. Clark CR, Morgan C, Sonstegard DA, Matthews LS. The effect of biopsy-hole shape and size on bone strength. *The Journal of bone and joint surgery American volume*. 1977 Mar;59(2):213-7. Epub 1977/03/01.
30. Stoffel K, Stachowiak G, Forster T, Gachter A, Kuster M. Oblique screws at the plate ends increase the fixation strength in synthetic bone test medium. *Journal of orthopaedic trauma*. 2004 Oct;18(9):611-6. Epub 2004/09/28.
31. Goulet JA, Senunas LE, DeSilva GL, Greenfield ML. Autogenous iliac crest bone graft. Complications and functional assessment. *Clinical orthopaedics and related research*. 1997 Jun(339):76-81. Epub 1997/06/01.
32. Finkemeier CG. Bone-grafting and bone-graft substitutes. *The Journal of bone and joint surgery American volume*. 2002 Mar;84-a(3):454-64. Epub 2002/03/12.
33. Hernigou P, Desroches A, Queinnee S, Flouzat Lachaniette CH, Poignard A, Allain J, et al. Morbidity of graft harvesting versus bone marrow aspiration in cell regenerative therapy. *International orthopaedics*. 2014 Mar 23. Epub 2014/03/25.
34. Hornicek FJ, Gebhardt MC, Tomford WW, Sorger JI, Zavatta M, Menzner JP, et al. Factors affecting nonunion of the allograft-host junction. *Clinical orthopaedics and related research*. 2001 Jan(382):87-98. Epub 2001/01/12.
35. Shehadeh A, Noveau J, Malawer M, Henshaw R. Late complications and survival of endoprosthetic reconstruction after resection of bone tumors. *Clinical orthopaedics and related research*. 2010 Nov;468(11):2885-95. Epub 2010/07/14.
36. Racano A, Pazionis T, Farrokhyar F, Deheshi B, Ghert M. High infection rate outcomes in long-bone tumor surgery with endoprosthetic reconstruction in adults: a systematic review. *Clinical orthopaedics and related research*. 2013 Jun;471(6):2017-27. Epub 2013/02/14.
37. Jeys LM, Grimer RJ, Carter SR, Tillman RM. Periprosthetic infection in patients treated for an orthopaedic oncological condition. *The Journal of bone and joint surgery American volume*. 2005 Apr;87(4):842-9. Epub 2005/04/05.
38. Farfalli GL, Aponte-Tinao L, Lopez-Millan L, Ayerza MA, Muscolo DL. Clinical and functional outcomes of tibial intercalary allografts after tumor resection. *Orthopedics*. 2012 Mar;35(3):e391-6. Epub 2012/03/06.



39. Myers GJ, Abudu AT, Carter SR, Tillman RM, Grimer RJ. The long-term results of endoprosthetic replacement of the proximal tibia for bone tumours. *The Journal of bone and joint surgery British volume*. 2007 Dec;89(12):1632-7. Epub 2007/12/07.
40. Mavrogenis AF, Papagelopoulos PJ, Coll-Mesa L, Pala E, Guerra G, Ruggieri P. Infected tumor prostheses. *Orthopedics*. 2011 Dec;34(12):991-8; quiz 9-1000. Epub 2011/12/08.
41. Han I, Oh JH, Na YG, Moon KC, Kim HS. Clinical outcome of parosteal osteosarcoma. *Journal of surgical oncology*. 2008 Feb 1;97(2):146-9. Epub 2007/12/01.
42. Szendroi M, Antal I, Arato G. Adamantinoma of long bones: a long-term follow-up study of 11 cases. *Pathology oncology research : POR*. 2009 Jun;15(2):209-16. Epub 2008/12/03.
43. Ritschl P, Wurnig C, Lechner G, Roessner A. Parosteal osteosarcoma. 2-23-year follow-up of 33 patients. *Acta orthopaedica Scandinavica*. 1991 Jun;62(3):195-200. Epub 1991/06/01.
44. So TY, Lam YL, Mak KL. Computer-assisted navigation in bone tumor surgery: seamless workflow model and evolution of technique. *Clinical orthopaedics and related research*. 2010 Nov;468(11):2985-91. Epub 2010/07/17.
45. Bird JE. "Advances in the surgical management of bone tumors". *Current oncology reports*. 2014 Jul;16(7):392. Epub 2014/05/24.
46. Gerbers JG, Ooijen PM, Jutte PC. Computer-assisted surgery for allograft shaping in hemicortical resection: a technical note involving 4 cases. *Acta orthopaedica*. 2013 Apr;84(2):224-6. Epub 2013/02/16.
47. Mankin HJ, Gebhardt MC, Jennings LC, Springfield DS, Tomford WW. Long-term results of allograft replacement in the management of bone tumors. *Clinical orthopaedics and related research*. 1996 Mar(324):86-97. Epub 1996/03/01.
48. Mankin HJ, Springfield DS, Gebhardt MC, Tomford WW. Current status of allografting for bone tumors. *Orthopedics*. 1992 Oct;15(10):1147-54. Epub 1992/10/01.
49. Torbert JT, Fox EJ, Hosalkar HS, Ogilvie CM, Lackman RD. Endoprosthetic reconstructions: results of long-term followup of 139 patients. *Clinical orthopaedics and related research*. 2005 Sep;438:51-9. Epub 2005/09/01.
50. Ahlmann ER, Menendez LR, Kermani C, Gotha H. Survivorship and clinical outcome of modular endoprosthetic reconstruction for neoplastic disease of the lower limb. *The Journal of bone and joint surgery British volume*. 2006 Jun;88(6):790-5. Epub 2006/05/25.





# Chapter 7

## **Is there still a role for osteoarticular allograft reconstruction in musculoskeletal tumor surgery?**

*A long-term follow-up study of 38 patients and  
systematic review of the literature*

M.P.A. Bus<sup>1</sup>

M.A.J. van de Sande<sup>1</sup>

A.H.M. Taminiau<sup>1</sup>

P.D.S. Dijkstra<sup>1</sup>

<sup>1</sup>Orthopaedic Surgery, Leiden University Medical Center, Leiden, the Netherlands

*Bone Joint J 2017;99-B:522–30*

## Abstract

**Aims:** To assess complications and failure mechanisms of osteoarticular allograft reconstructions for primary bone tumors.

**Patients and Methods:** We retrospectively evaluated 38 patients (28 men, 74%) who were treated at our institution with osteoarticular allograft reconstruction between 1989 and 2010. Median age was 19 years (interquartile range 14 to 32). Median follow-up was 19.5 years (95% confidence interval [CI] 13.0 to 26.1) when 26 patients (68%) were alive. In addition, we systematically searched the literature for clinical studies on osteoarticular allografts, finding 31 studies suitable for analysis. Results of papers that reported on one site exclusively were pooled for comparison.

**Results:** A total of 20 patients (53%) experienced graft failure, including 15 due to mechanical complications (39%) and three (9%) due to infection. In the systematic review, 514 reconstructions were analyzed (distal femur,  $n = 184$ , 36%; proximal tibia,  $n = 136$ , 26%; distal radius,  $n = 99$ , 19%; proximal humerus,  $n = 95$ , 18%). Overall rates of failure, fracture and infection were 27%, 20%, and 10% respectively. With the distal femur as the reference, fractures were more common in the humerus (odds ratio [OR] 4.1, 95% CI 2.2 to 7.7) and tibia (OR 2.2, 95% CI 1.3 to 4.4); infections occurred more often in the tibia (OR 2.2, 95% CI 1.3 to 4.4) and less often in the radius (OR 0.1, 95% CI 0.0 to 0.8).

**Conclusion:** Osteoarticular allograft reconstructions are associated with high rates of mechanical complications. Although comparative studies with alternative techniques are scarce, the risk of mechanical failure in our opinion does not justify routine employment of osteoarticular allografts for reconstruction of large joints after tumor resection.

## Introduction

Primary malignant bone tumors commonly grow in close proximity to joints<sup>1,2</sup>. Resection with clear margins is the mainstay of surgical treatment and therefore, it is often necessary to resect part of a joint<sup>3,4</sup>. Endoprostheses are generally regarded as the benchmark after such resections<sup>5,6</sup>. However, endoprosthetic joint arthroplasty requires the sacrifice of the corresponding reciprocal side of the joint. Moreover, recent studies describe considerable rates of failure of endoprosthetic reconstruction due to both mechanical (loosening, implant breakage, periprosthetic fractures) and non-mechanical (predominantly infection) complications<sup>6-8</sup>.

Osteoarticular allografts provide an alternative method of reconstruction to endoprostheses. Potential advantages of osteoarticular allografts include the possibility to re-attach tendons and to reconstruct unicondylar or hemi-articular defects<sup>9,10</sup>. On the other hand, allografts have been associated with considerable rates of infection, fracture and nonunion<sup>3,11-14</sup>. Reported overall complication rates typically range from 40% to 70%<sup>9,15-25</sup>. Moreover, studies raised concern about the viability of cryopreserved cartilage and noted that osteoarthritis becomes a major problem approximately six years after transplantation<sup>26,27</sup>. Nevertheless, functional outcome is generally acceptable, with mean Musculoskeletal Tumor Society (MSTS) scoring system scores<sup>28</sup> ranging from 70% to 91%<sup>9,16-18,23-25,29,30</sup>.

To date, there are no studies on large groups of patients with osteoarticular allografts with long-term follow-up. Therefore, there is paucity of solid evidence concerning complications and long-term outcomes. We retrospectively evaluated our experiences with osteoarticular allografts in treatment of primary tumors and systematically reviewed the literature with the aims to assess: long-term complication rates, mechanisms of reconstruction failure, and allograft survival rates.

## Patients and Methods

### Retrospective study

We searched our institutional database to identify all patients who had an osteoarticular allograft reconstruction for a bone tumor between 1989 and 2012. A total of 38 consecutive patients (28 men, 74%) with a median age of 19 years



(interquartile range [IQR] 14 to 32) at surgery were included (table 1). A total of 33 patients (87%) had a malignant tumor (predominantly osteosarcoma,  $n = 20$ , 53%), five patients (13%) were treated for a benign but aggressive lesion, mostly giant cell tumors of bone ( $n = 4$ , 11%). A further 26 patients (68%) were treated with chemotherapy according to appropriate protocols, two (5%) underwent radiotherapy.

Allografts were harvested during post-mortem tissue donation by our national bone bank. Proximal humeral grafts included tendons of the rotator cuff, pectoralis major and latissimus dorsi; allografts of the proximal femur had the tendons of the glutei and iliopsoas attached. Distal femoral and proximal tibial grafts included the knee capsule and all surrounding ligaments. Following retrieval, articular cartilage was covered with gauze soaked in dimethylsulphoxide<sup>31</sup> and allografts were stored at  $-80^{\circ}\text{C}$ <sup>32</sup>. Processing of the allografts was performed at either Osteotech (Eatontown, New Jersey) or the Musculoskeletal Transplant Foundation (Edison, New Jersey). Grafts were either not subjected to additional sterilization or irradiated with low-dose gamma radiation ( $< 25$  kGy).

All patients had a biopsy pre-operatively to obtain a histological diagnosis. Resections were planned on conventional radiographs, CT and/or MRI. All patients received prophylactic cephalosporins pre-operatively. During tumor resection, the allograft was thawed in saline with gentamicin and flucloxacillin. Following resection, the graft was cut to fit the resected defect freehand, and appropriate structures were prepared to attach corresponding host structures. All osteotomies were fashioned transversely. Muscle flap rotations ( $n = 9$ , 23%) were only used where there was poor soft-tissue coverage.

Follow-up routinely included conventional radiographs but if a recurrence was suspected an MRI scan was obtained. Medical files and radiographs of the reconstruction were evaluated to obtain details about patients, tumors, treatment, and reconstructions. Complications and failures were classified into types 1 to 5, according to Henderson *et al*<sup>33, 34</sup> (type 1, soft-tissue failure and instability; type 2, graft-host nonunion; type 3, structural failure; type 4, infection; and type 5, tumor progression). Nonunion was defined as surgical intervention to facilitate union of the allograft-host junction<sup>3</sup>. Fractures were diagnosed on imaging. If the allograft was removed (partially or completely), or if the reconstruction was converted to an allograft-prosthetic composite or arthrodesis, we considered the reconstruction to be a failure.

**Table 1.** Study data

Variable	n (%)
<i>Gender</i>	
Male	28 (74)
Female	10 (26)
<i>Diagnosis</i>	
Osteosarcoma (conventional type)	20 (53)
Giant cell tumor of bone	4 (11)
Ewing sarcoma	3 (8)
Chondrosarcoma grade 3	3 (8)
Chondrosarcoma grade 2	2 (5)
Parosteal osteosarcoma	2 (5)
Pleomorphic undifferentiated sarcoma	2 (5)
Low-grade osteosarcoma	1 (3)
Aneurysmal bone cyst	1 (3)
<i>Location</i>	
Proximal tibia	14 (37)
Proximal humerus	12 (32)
Distal femur	10 (26)
Distal radius	2 (5)
<i>Type of graft</i>	
Segmental	32 (84)
Hemicortical/unicondylar	6 (16)
<i>Osteosynthesis</i>	
Plate(s)	28 (74)
Intramedullary nail	8 (21)
Intramedullary nail and plate	1 (3)
Screws	1 (3)
<i>Graft length</i>	
< 10 cm	6 (16)
10 cm to 15 cm	14 (37)
> 15 cm	18 (47)
<i>Adjuvant therapy</i>	
Chemotherapy	26 (68)
Radiotherapy	2 (5)
<i>Failures</i>	
Mechanical reasons	15 (39)
Non-mechanical reasons	5 (13)
<i>Follow-up</i>	
≥ 5 yrs	28 (74)
≥ 10 yrs	24 (63)
≥ 20 yrs	12 (32)



Reconstructions were located in the proximal tibia (n = 14, 37%), proximal humerus (n = 12, 32%), distal femur (n = 10, 26%) and distal radius (n = 2, 5%). A total of 32 patients (84%) had a segmental, and six (16%) a unicondylar reconstruction (four proximal tibial, two distal femoral). Median allograft length was 14 cm (IQR 10 to 17), and was greater for the proximal humerus (16.5 cm, IQR 13 to 19.5) than for other sites (12 cm, IQR 10 to 17). Allografts were fixed to host bone using either one or more plate(s) (n = 28, 74%), an intramedullary nail (n = 8, 21%), screws only, or an intramedullary nail and plate (each; n = 1, 3%). In seven patients (18%), an allogeneic fibular strut was used to reinforce the construct. A gastrocnemius flap was used in nine proximal tibial reconstructions (64%).

### **Systematic literature review**

We performed a systematic search to identify papers on osteoarticular allograft reconstructions for musculoskeletal tumors. All clinical case series that reported on at least five reconstructions, and were written in English, Dutch, German, French or Italian, were included. With search terms which are detailed in the supplementary material, we identified 244 unique titles in PubMed, EMBASE, Web of Science, CINAHL, Academic Search Premier and Science Direct. The leading author screened all titles and abstracts, extracted relevant data and critically appraised the included studies. The critical appraisal data were based on a previous systematic review on reconstructions for tumor resections<sup>35</sup>. Our review was registered with the international prospective register of systematic reviews (PROSPERO) database<sup>36</sup> (identifier CRD42015026027).

### **Statistical analysis**

Continuous variables were compared with Mann-Whitney U tests. Logistic regression analysis was used to assess the influence of factors on the occurrence of complications in the retrospective study, and to compare the incidence of complications in the systematic review. Allograft survival was estimated with Kaplan-Meier curves with 95% confidence intervals (CI). We used SPSS v.21 software (IBM Corp., Armonk, New York), with the level of significance at a p-value < 0.05.



## Results

### Retrospective study

At review, 26 patients (68%) had no evidence of disease and 12 patients (32%) had died. Median follow-up was 19.5 years (95% CI 13.0 to 26.1). A total of 39 patients (79%) experienced one or more complications. Two patients (5%) required further surgery for joint instability (Henderson type 1 complication); both reconstructions of the distal radius were converted to an arthrodesis. Of 24 patients with a reconstruction around the knee, 15 (63%) had worn a brace for at least one year, or until failure of their graft, because of instability of the reconstructed joint.

Nonunion (Henderson type 2 complication) occurred in six reconstructions (16%). Re-operations took place after a median of 13 months (IQR 9 to 18), in two proximal tibial (14%), two distal femoral (20%) and two proximal humeral reconstructions (17%). One allograft (3%) was removed because of nonunion.

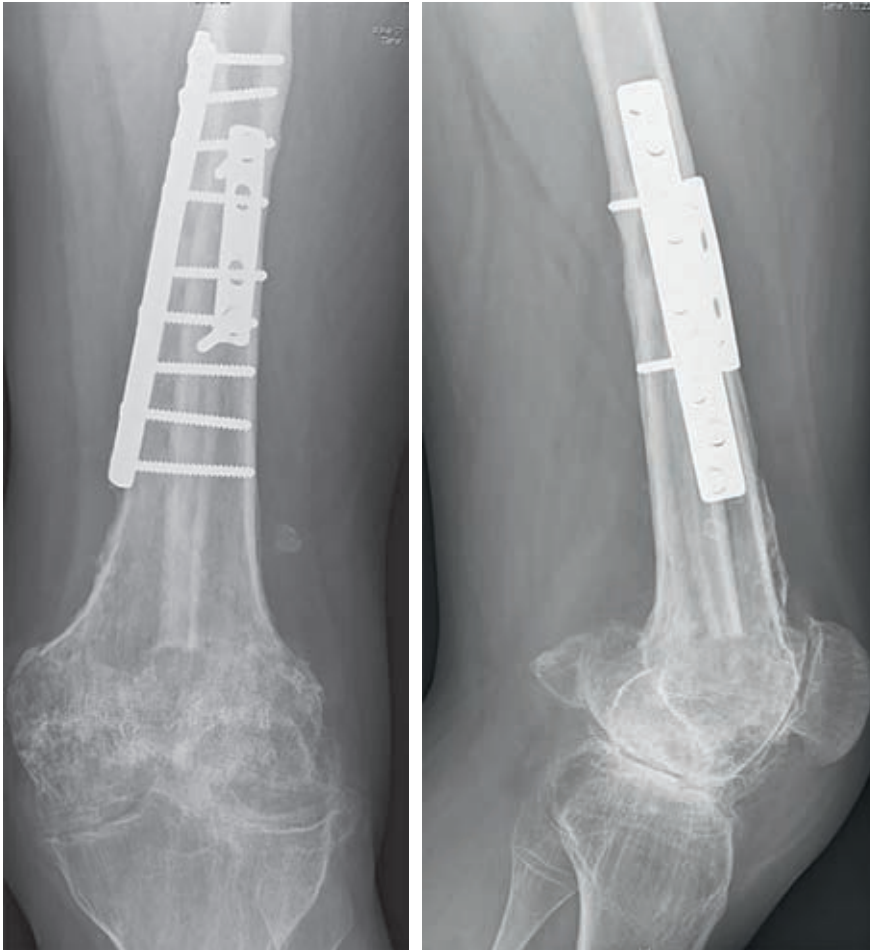Fractures (Henderson type 3 complication) occurred in ten patients (26%), after a median of 49 months (IQR 27 to 74). Fractures occurred in reconstructions of the proximal tibia ( $n = 5$ , 36%), proximal humerus ( $n = 3$ , 25%) and distal femur ( $n = 2$ , 20%). All fractures occurred in reconstructions  $\geq 10$  cm.

Infections (Henderson type 4 complication) occurred in five patients (13%), after two, 14, 17, 37 and 40 months. Two patients had a primary infection (5%), others occurred after operative intervention for other complications. Four infections occurred in the proximal tibia (29%) and one in the distal femur (10%). Allografts involving the tibia were associated with an increased risk of infection (OR 9.2, 95% CI 0.9 to 93.0,  $p = 0.06$ ). Tibial grafts with a muscle flap appeared to have a lower infection risk (two of nine, 22%) than those without (two of five, 40%).

Local recurrences (Henderson type 5 complication) occurred in two patients (5%, one osteosarcoma with wide margins and one parosteal osteosarcoma with an intralesional excision), after six and 13 months, respectively. Metastases developed in eight patients (21%).

In total, 20 reconstructions failed (53%): eight proximal tibial (57%), five distal femoral (50%) and two distal radial (100%) allografts. Reasons for failure were fracture ( $n = 7$ , 18%), degenerative changes or subchondral collapse ( $n = 5$ , 13%, figure 1), infection ( $n = 3$ , 9%), instability ( $n = 2$ , 6%), tumor recurrence ( $n = 2$ , 6%, figure 2) and nonunion ( $n = 1$ , 3%) (table 2).



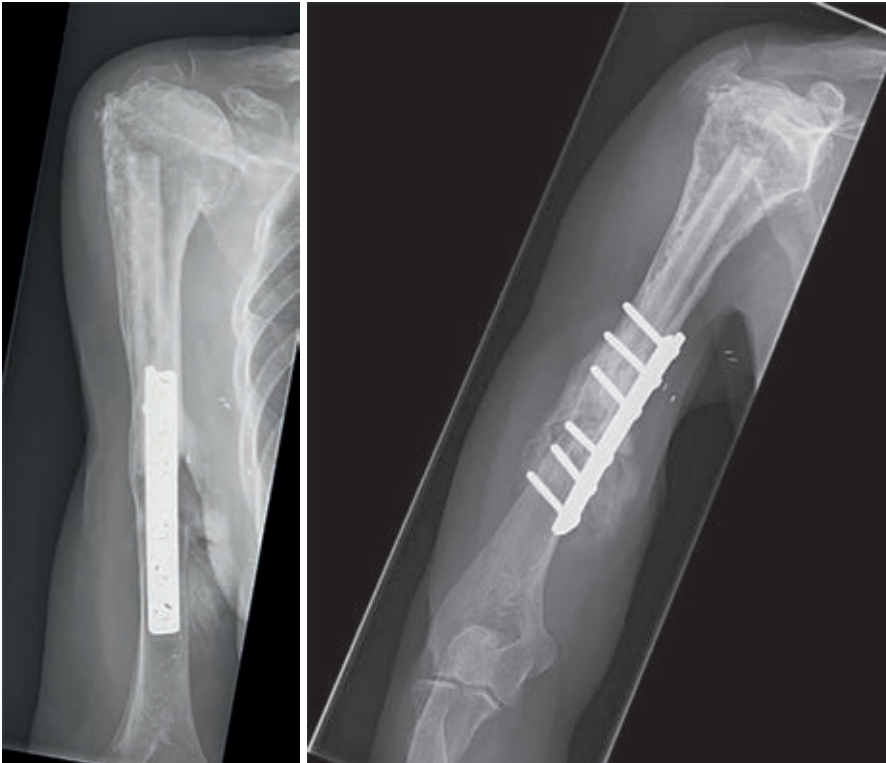

**Figure 1.** Conventional anteroposterior and lateral radiographs, taken 18 years after a transarticular distal femoral resection for an osteosarcoma in a 14-year-old male patient. The allograft was fixed to host bone using two plates. There is sound incorporation of the allograft. Signs of severe secondary osteoarthritis can easily be identified in the tibiofemoral and patellofemoral joints. The patient was free of pain.

**Table 2.** Overview of failure mechanisms

Location (n)	Failure type (Henderson classification)					Total n (%)
	Instability	Nonunion	Structural	Infection	Tumor progression	
Proximal tibia (14)	-	1	4	3	-	8 (57)
Distal femur (10)	-	-	4	-	1	5 (50)
Proximal humerus (12)	-	-	4	-	1	5 (42)
Distal radius (2)	2	-	-	-	-	2 (100)
All (38)	2	1	12	3	2	20 (53)

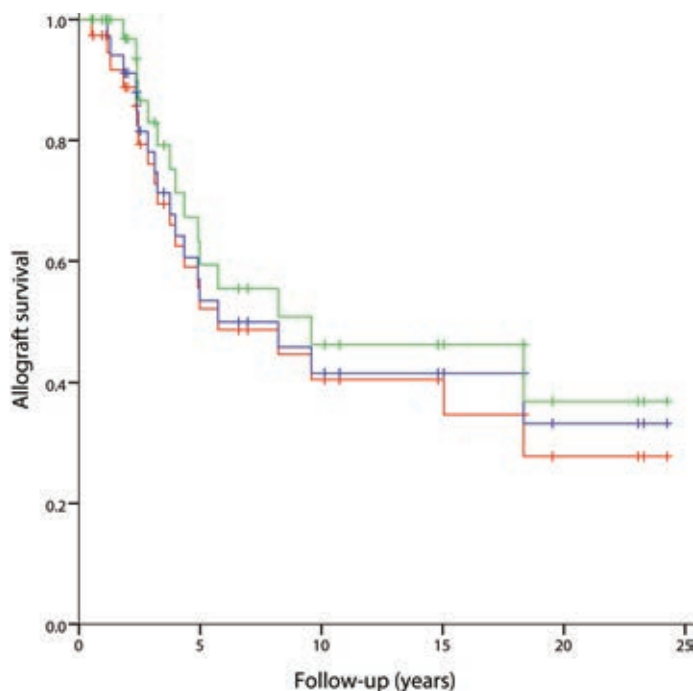
Of the 15 allografts that were followed for more than five years (39%), five (33%) failed after more than five years post-operatively. Failures were salvaged with endoprostheses in 12 patients (32%; eight knee and three shoulder arthroplasties) and with an arthrodesis in two (5%; both at the wrist). Ablative procedures were undertaken in six patients (16%).



**Figure 2.** Conventional anteroposterior and lateral radiographs, taken 15 years after resection of the proximal humerus for a low-grade osteosarcoma in a 46-year-old female patient. The allograft was fixed to host bone using a plate. A fibular strut graft can be identified in the intramedullary canal. Later, a transhumeral amputation was performed for a soft-tissue recurrence.

Estimated median allograft survival was 5.7 years (95% CI 0.4 to 11.1), when 22 patients were at risk for failure. With failure for any reason as the endpoint, survival rates at two, five and ten years were 89% (95% CI 79 to 99, 30 patients at risk), 52% (95% CI 34 to 70, 15 patients at risk) and 41% (95% CI 23 to 59, ten patients at risk). With failure for mechanical reasons as the endpoint, these were 97% (95% CI 91 to

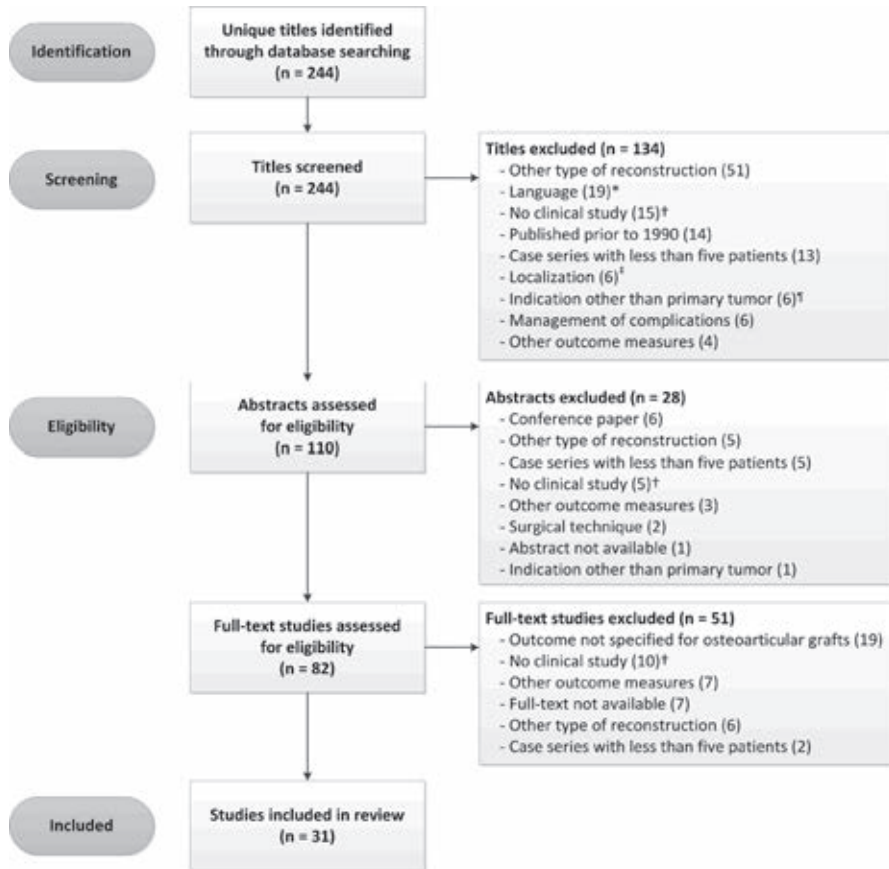
100, 31 patients at risk), 59% (95% CI 41 to 78, 15 patients at risk) and 46% (95% CI 26 to 66, ten patients at risk), respectively (figure 3).



**Figure 3.** Kaplan-Meier curve for survival of the reconstruction, with failure for all reasons as the endpoint (red line), failure for non-oncological reasons (mechanical reasons and infection) as the endpoint (blue line) and failure for mechanical reasons as the endpoint (green line).

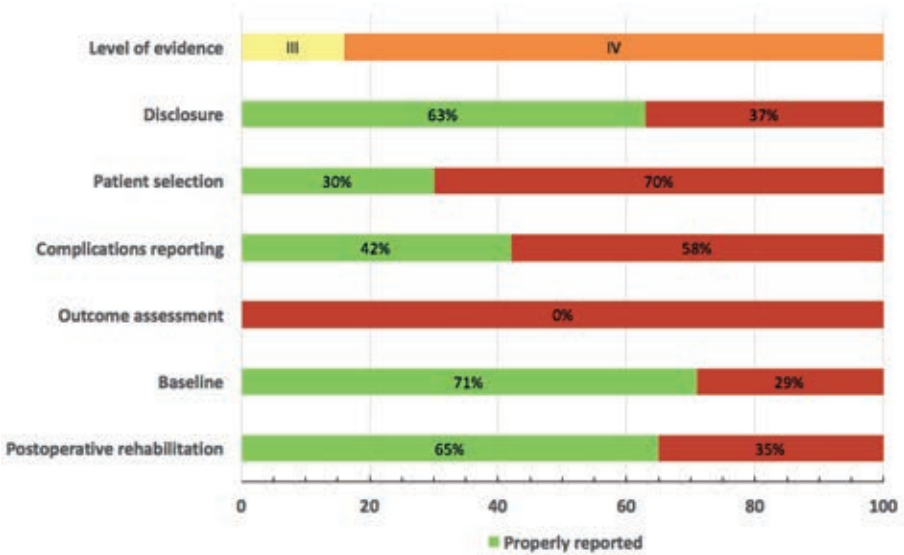
### Systematic literature review

After review of 244 titles, 110 abstracts were screened, of which 82 full-text articles were subsequently assessed. This resulted in further exclusion of 51 papers, leaving 31 studies available for review (figure 4)<sup>9, 14-19, 21-25, 37-55</sup>. Only five studies (16%) were level III evidence; the remainder (26/31, 84%) were level IV (supplementary material). Critical appraisal demonstrated that only nine (30%) of studies properly reported on eligibility criteria and sources and methods of patient selection (figure 5). The 31 included studies reported on a total of 781 reconstructions in 769 patients.



**Figure 4.** Flowchart of the systematic literature search (\*excluded languages were Chinese, Spanish, Russian and Norwegian; †including (but not limited to) basic science studies, animal studies, reviews without new cases, radiological studies, immunological studies and biomechanical studies; ‡excluded sites involving the pelvis, hand and elbow; †excluded indications were traumatic skeletal defects and failed arthroplasty).

Predominant reconstruction sites were the distal femur (n = 333, 43%), proximal tibia (n = 228, 29%), proximal humerus (n = 111, 14%) and distal radius (n = 100, 13%). To ensure that complications could be linked to the site at which they occurred, we selected only those papers that reported on one reconstruction site exclusively. We identified three papers focusing on the distal femur (n = 184)<sup>14, 16, 19</sup>, five on the proximal tibia (n = 136)<sup>15, 17, 43, 47, 53</sup>, seven on the distal radius (n = 99)<sup>22, 38, 40, 41, 48-50</sup> and five on the proximal humerus (n = 95)<sup>21, 23, 24, 45, 46</sup>, leaving 514 reconstructions for analysis. Apart from one study that included 18 unicondylar distal femoral reconstructions<sup>14</sup>, all reconstructions were segmental.



**Figure 5.** Result of the critical appraisal of studies included in the systematic review. Low reporting of selected criteria increases the risk of bias.

Overall reported rates of failure, fracture and infection were 27% (141/514), 20% (100/514) and 10% (52/514), respectively. Mean follow-up ranged from 24 months to 16 years. With the distal femur as the reference, we compared complication rates between different reconstruction sites. The risk of failure was lowest for the distal radius (OR 0.3, 95% CI 0.1 to 0.6). While the risk of fracture was significantly higher for the proximal humerus (OR 4.1, 95% CI 2.2 to 7.7) and proximal tibia (OR 2.2, 95% CI 1.3 to 4.4), the risk of infection was significantly higher for the proximal tibia (OR 2.2, 95% CI 1.1 to 4.3) and significantly lower for the distal radius (OR 0.1, 95% CI 0.0 to 0.8) (table 3). Results of studies that reported on at least 20 reconstructions are detailed in the supplementary material; many studies did not report the length of the graft. As a result of a lack of detailed description, we were not able to comment on an association between the type of osteosynthesis and the occurrence of complications.

## Discussion

Osteoarticular allografts represent an alternative to endoprosthetic reconstruction in musculoskeletal tumor surgery. However, solid evidence on the incidence of complications, failure mechanisms, and survival of the reconstruction is lacking. We therefore systematically reviewed the literature and retrospectively evaluated our single-centre experiences, with the aims to assess long-term rates of complications, mechanisms of failure, and rates of survival of the allograft.

**Table III.** Analysis of reported complication rates by odds ratios (OR) with 95% confidence intervals (CI)

Location (n)	Failure			Infection			Fracture		
	n (%)	OR (95% CI)	p-value	n (%)	OR (95% CI)	p-value	n (%)	OR (95% CI)	p-value
Distal femur (184)	55 (30)	Ref (-)	-	17 (9)	Ref (-)	-	21 (11)	Ref (-)	-
Proximal tibia (104)	47 (35)	1.2 (0.8 – 2.0)	0.38	25 (18)	2.2 (1.1 – 4.3)	0.02	32 (24)	2.2 (1.3 – 4.4)	0.005
Distal radius (99)	11 (11)	0.3 (0.1 – 0.6)	0.001	1 (1)	0.1 (0.0 – 0.8)	0.03	14 (14)	1.3 (0.6 – 2.6)	0.51
Proximal humerus (95)	28 (30)	1.0 (0.6 – 1.7)	0.94	9 (10)	1.0 (0.4 – 2.4)	0.95	33 (35)	4.1 (2.2 – 7.7)	<0.00001

Data in this table are based on results reported in papers focusing on one reconstruction site exclusively. Results are derived from three papers focusing on the distal femur<sup>14, 16, 19</sup>, five on the proximal tibia<sup>15, 17, 43, 47, 53</sup>, seven on the distal radius<sup>22, 38, 40, 41, 48-50</sup> and five on the proximal humerus<sup>21, 23, 24, 45, 46</sup>.

\* logistic regression analysis. Ref, reference value.

The reconstruction failed in 53% of our patients, mostly due to mechanical complications. Previous studies reported failures in 22% to 60% of segmental osteoarticular allografts; however, follow-up varied greatly (see supplementary material). Previous authors have stated that if an intercalary allograft survives the critical three to four years, it is likely to last for many years<sup>12</sup>. It appears that this does not apply to osteoarticular grafts. Of the grafts that were followed for more than five years, 33% failed at a later point in time. One explanation might be that creeping substitution, the process through which the allograft is gradually replaced by living bone<sup>29</sup>, cannot take place at the articular side of the osteoarticular graft and as a result, there is a risk of subchondral collapse<sup>42</sup>. If technically feasible, performing a unicondylar or hemicortical resection may prove useful in reducing this risk; by preserving host subchondral bone and increasing the contact surface between allogenic and host bone, the risk of collapse and nonunion may be reduced. In the

only study focusing on unicondylar osteoarticular allografts to date, Muscolo *et al*<sup>9</sup> reported promising results with an allograft rate of survival of 85% at ten years in 40 reconstructions (38 patients).

Severe instability occurred in two reconstructions of the distal radius, and 63% of our patients with a reconstruction around the knee had to wear a brace for a prolonged period. Previously reported rates of instability range from 5% to 20%. Due to the subjectivity of the outcome, it is difficult to assess adequately the occurrence of joint instability in a retrospective study.

From our review, it appeared that fracture is the most common complication after osteoarticular allograft reconstruction (up to 52%). A total of ten of our patients (26%) sustained a fracture. The risk of fracture was higher after nail fixation; in accordance with previous studies, we recommend plate fixation<sup>3, 11, 56</sup>. One of the problems in osteoarticular reconstructions, however, is the fact that it is not possible to apply bridging osteosynthesis, while it has been noted that this reduces the risk of complications<sup>3, 57</sup>. An explanation for the high risk of fracture might be that considerable torsional forces act on the plate (especially in case of instability of surrounding joints) and the hardware is therefore prone to break at some point in time. We demonstrated that the proximal humerus and tibia have the highest risk of fracturing. The high risk for proximal humeral grafts might be explained by the greater length of these reconstructions. Although we could not demonstrate an association between graft length and the risk of complications, previous studies reported unfavorable results for larger reconstructions<sup>3, 13, 58</sup>. Filling the graft with cement may reduce the fracture rate in high-risk reconstructions<sup>24</sup>. Another strategy is to apply double-plate fixation, thereby increasing the torsional and bending stiffness of the construct<sup>59</sup>. However, this may necessitate additional soft-tissue dissection and thus increase the risk of infection<sup>58</sup>.

A total of three of our patients (8%) underwent revision for symptomatic degenerative joint changes. Previous authors reported degenerative changes in 13% to 31% of reconstructed joints<sup>17, 19, 25</sup>, while others concluded that osteoarthritis occurs in practically all patients<sup>20, 40, 41</sup>. However, follow-up periods differed and authors often either did not provide a clear definition of degeneration<sup>14, 19, 25, 54</sup> or sufficed with a radiographic diagnosis<sup>9, 16, 17, 44</sup>.

The use of massive allografts is presumed to be associated with a high risk of infection<sup>60</sup>. However, through our literature review, we found an overall infection rate of 10% (52/514), which is identical to the rate found by Racano *et al*<sup>61</sup> in their systematic review on endoprosthetic reconstruction in long-bone tumor surgery



(pooled overall infection rate that included 48 studies on a total of 4838 patients). Albergo *et al*<sup>62</sup> on the other hand, reported that the risk of failure due to infection is higher for osteoarticular allografts than for endoprostheses in a direct comparative study of 88 patients with an endoprosthesis and 45 patients with an osteoarticular allograft, although their study was retrospective and compared data from two different units. Both in the literature, and in our series, the risk of infection was highest in the proximal tibia. While the patients who were considered to be at high risk for infection due to poor soft-tissue coverage<sup>63</sup> were the ones who received a muscle flap, the infection rate was lower in reconstructions with a muscle flap. Concurring with previous authors we believe that muscle flaps should be used routinely in these high-risk cases<sup>64</sup>.

Our study has a number of limitations. First, we were hampered by a limited number of patients in our retrospective study, and it was therefore not possible to assess fully the risk factors for complications. Secondly, different definitions of complications have been used in the literature, and this may have affected the results from our pooled analysis. Furthermore, several studies did not clearly describe how they determined whether a complication had occurred, or how they defined nonunion. Thirdly, studies included in the systematic review have inherent heterogeneity with regards to included diagnoses, treatment protocols, use of additional struts and flaps, osteosynthesis and cement. We were unable to adjust for these factors and this may have introduced bias. However, we aimed to provide an overview of current knowledge on osteoarticular allograft reconstructions in musculoskeletal tumor surgery, and this could only be achieved by combining different studies and definitions. Lastly, it should be noted that all studies included in the systematic review were retrospective and observational, and may therefore be graded as a low level of evidence.

An advantage of using an osteoarticular allograft for primary reconstruction is that, in case of degenerative changes, it may be converted to an allograft-prosthetic composite with relative ease. Therefore, an osteoarticular allograft may be used to delay the time for endoprosthetic reconstruction in young patients. Few series have compared the results of allografts with endoprostheses, and most focused on reconstruction of the proximal humerus<sup>30, 39, 45, 53, 65</sup>. The majority of the comparative studies concluded that allografts are associated with unacceptably high complication rates and unpredictable outcomes; reconstruction with either allograft-prosthetic composites or endoprostheses was therefore advocated as the method of choice<sup>39, 45, 53</sup>.



The use of osteoarticular allografts for reconstruction of large joints may have been justifiable in the past, when endoprostheses were associated with high rates of mechanical failure. Due to marked advances in endoprosthetic design, it appears that metallic implants have largely replaced biological implants as the technique of choice for reconstruction of articular defects. Possibly, osteoarticular allografts are a reasonable solution for patients in whom only a small part of the articulating structure has to be resected or, given the unpredictable results of expanding prostheses<sup>66</sup>, joint reconstruction in the growing child or teenagers. Although comparative studies with alternative techniques are scarce, the risk of mechanical failure in our opinion does not justify routine employment of osteoarticular allografts for reconstruction of large joints after tumor resection.

## Appendices

### Appendix 1. Search strategy for the systematic literature review

**PubMed:** ("osteoarticular allograft"[tw] OR "osteoarticular allografting"[tw] OR "osteoarticularallografts"[tw] OR "osteoarticularallograft"[tw] OR "osteoarticularknee allografts"[tw] OR (("osteoarticular"[tw] OR osteoartic\*[tw] OR "osteo articular"[tw]) AND ("allograft"[tw] OR allograft\*[tw] OR "allo graft"[tw] OR allo graft\*[tw] OR "Transplantation, Homologous"[Mesh] OR Homograft\*[tw] OR Homologous Transplant\*[tw] OR Allogeneic Transplant\*[tw] OR Homologous graft\*[tw] OR Allogeneic graft\*[tw])) OR "osteo articular bone grafts"[tw] OR "osteoarticular graft"[tw] OR "osteoarticular grafts"[tw]) AND ("Bone Neoplasms"[Mesh] OR Bone Neoplasm OR Bone Neoplasms OR Bone Cancer OR Cancer of the Bone OR Cancer of Bone OR bone tumor OR bone tumors OR bone tumour OR bone tumours OR bone sarcoma OR bone sarcomas OR Adamantinoma OR Femoral Neoplasms OR "Neoplasms, Bone Tissue"[Mesh] OR Ossifying Fibroma OR Osteoblastoma OR Osteochondroma OR Osteochondromatosis OR Osteoma OR Osteoid Osteoma OR Osteosarcoma OR Osteosarcoma\* OR Ewing Sarcoma OR Multiple Hereditary Exostoses OR Ossifying Fibroma\* OR Osteoblastoma\* OR Osteochondroma\* OR Osteoma\* OR Ewing Sarcoma\*)

**Archivalia:** OR (("osteoarticular"[tw] OR osteoartic\*[tw] OR "osteo articular"[tw]) AND ("graft"[tw] OR graft\*[tw]))

**Embase:** ("osteoarticular allograft".mp OR "osteoarticular allografting".mp OR "osteoarticular allografts".mp OR "osteoarticular allograft".mp OR "osteoarticular knee allografts".mp OR (("osteoarticular".mp OR osteoartic\*.mp OR "osteo articular".mp) AND ("bone allograft"/ OR "allograft".mp OR allograft\*.mp OR "allo graft".mp OR allograft\*.mp OR "allotransplantation"/ OR Homograft\*.mp OR Homologous Transplant\*.mp OR Allogeneic Transplant\*.mp OR Homologous graft\*.mp OR Allogeneic graft\*.mp)) OR "osteo articular bone grafts".mp OR "osteoarticular graft".mp OR "osteoarticular grafts".mp) AND (exp "Bone Tumor"/ OR (Bone Neoplasm OR Bone Neoplasms OR Bone Cancer OR Cancer of the Bone OR Cancer of Bone OR bone tumor OR bone tumors OR bone tumour OR bone tumours OR bone sarcoma OR bone sarcomas OR Adamantinoma OR Femoral Neoplasms OR Ossifying Fibroma OR Osteoblastoma OR Osteochondroma OR Osteochondromatosis OR Osteoma OR Osteoid Osteoma OR Osteosarcoma OR Osteosarcoma\* OR Ewing Sarcoma OR Multiple Hereditary Exostoses OR Ossifying Fibroma\* OR Osteoblastoma\* OR Osteochondroma\* OR Osteoma\* OR Ewing Sarcoma\*).mp OR ((Bone\* AND



Neoplasm) OR (Bone\* AND Neoplasms) OR (Bone\* AND Cancer) OR (bone\* AND tumor\*) OR (bone\* AND tumour\*) OR (bone\* AND sarcoma\*).mp)

**Web of Science:** TS=((("osteoarticular allograft" OR "osteoarticular allografting" OR "osteoarticular allografts" OR "osteo articular allograft" OR "osteoarticular knee allografts" OR (("osteoarticular" OR osteoartic\* OR "osteo articular") AND ("bone allograft" OR "allograft" OR allograft\* OR "allo graft" OR allo graft\* OR "allotransplantation" OR Homograft\* OR Homologous Transplant\* OR Allogeneic Transplant\* OR Homologous graft\* OR Allogeneic graft\*)) OR "osteo articular bone grafts" OR "osteoarticular graft" OR "osteoarticular grafts") AND ("Bone Tumor" OR (Bone Neoplasm OR Bone Neoplasms OR Bone Cancer OR Cancer of the Bone OR Cancer of Bone OR bone tumor OR bone tumors OR bone tumour OR bone tumours OR bone sarcoma OR bone sarcomas OR Adamantinoma OR Femoral Neoplasms OR Ossifying Fibroma OR Osteoblastoma OR Osteochondroma OR Osteochondromatosis OR Osteoma OR Osteoid Osteoma OR Osteosarcoma OR Osteosarcoma\* OR Ewing Sarcoma OR Multiple Hereditary Exostoses OR Ossifying Fibroma\* OR Osteoblastoma\* OR Osteochondroma\* OR Osteoma\* OR Ewing Sarcoma\*) OR ((Bone\* AND Neoplasm) OR (Bone\* AND Neoplasms) OR (Bone\* AND Cancer) OR (bone\* AND tumor\*) OR (bone\* AND tumour\*) OR (bone\* AND sarcoma\*))))))

**Cochrane:** (("osteoarticular allograft" OR "osteoarticular allografting" OR "osteoarticular allografts" OR "osteo articular allograft" OR "osteoarticular knee allografts" OR (("osteoarticular" OR osteoartic\* OR "osteo articular") AND ("bone allograft" OR "allograft" OR allograft\* OR "allo graft" OR allo graft\* OR "allotransplantation" OR Homograft\* OR Homologous Transplant\* OR Allogeneic Transplant\* OR Homologous graft\* OR Allogeneic graft\*)) OR "osteo articular bone grafts" OR "osteoarticular graft" OR "osteoarticular grafts") AND ("Bone Tumor" OR (Bone Neoplasm OR Bone Neoplasms OR Bone Cancer OR Cancer of the Bone OR Cancer of Bone OR bone tumor OR bone tumors OR bone tumour OR bone tumours OR bone sarcoma OR bone sarcomas OR Adamantinoma OR Femoral Neoplasms OR Ossifying Fibroma OR Osteoblastoma OR Osteochondroma OR Osteochondromatosis OR Osteoma OR Osteoid Osteoma OR Osteosarcoma OR Osteosarcoma\* OR Ewing Sarcoma OR Multiple Hereditary Exostoses OR Ossifying Fibroma\* OR Osteoblastoma\* OR Osteochondroma\* OR Osteoma\* OR Ewing Sarcoma\*) OR ((Bone\* AND Neoplasm) OR (Bone\* AND Neoplasms) OR (Bone\* AND Cancer) OR (bone\* AND tumor\*) OR (bone\* AND tumour\*) OR (bone\* AND sarcoma\*))))))

**CINAHL:** ((“osteoarticular allograft” OR “osteoarticular allografting” OR “osteoarticular allografts” OR “osteo articular allograft” OR “osteoarticular knee allografts” OR ((“osteoarticular” OR osteoartic\* OR “osteo articular”) AND (“bone allograft” OR “allograft” OR allograft\* OR “allo graft” OR allo graft\* OR “allotransplantation” OR Homograft\* OR Homologous Transplant\* OR Allogeneic Transplant\* OR Homologous graft\* OR Allogeneic graft\*)) OR “osteo articular bone grafts” OR “osteoarticular graft” OR “osteoarticular grafts”) AND (“Bone Tumor” OR (Bone Neoplasm OR Bone Neoplasms OR Bone Cancer OR Cancer of the Bone OR Cancer of Bone OR bone tumor OR bone tumors OR bone tumour OR bone tumours OR bone sarcoma OR bone sarcomas OR Adamantinoma OR Femoral Neoplasms OR Ossifying Fibroma OR Osteoblastoma OR Osteochondroma OR Osteochondromatosis OR Osteoma OR Osteoid Osteoma OR Osteosarcoma OR Osteosarcoma\* OR Ewing Sarcoma OR Multiple Hereditary Exostoses OR Ossifying Fibroma\* OR Osteoblastoma\* OR Osteochondroma\* OR Osteoma\* OR Ewing Sarcoma\*) OR ((Bone\* AND Neoplasm) OR (Bone\* AND Neoplasms) OR (Bone\* AND Cancer) OR (bone\* AND tumor\*) OR (bone\* AND tumour\*) OR (bone\* AND sarcoma\*))))

**Academic Search Premier [fulltext]:** ti/su/ab/kw ((“osteoarticular allograft” OR “osteoarticular allografting” OR “osteoarticular allografts” OR “osteo articular allograft” OR “osteoarticular knee allografts” OR ((“osteoarticular” OR osteoartic\* OR “osteo articular”) AND (“bone allograft” OR “allograft” OR allograft\* OR “allo graft” OR allo graft\* OR “allotransplantation” OR Homograft\* OR Homologous Transplant\* OR Allogeneic Transplant\* OR Homologous graft\* OR Allogeneic graft\*)) OR “osteo articular bone grafts” OR “osteoarticular graft” OR “osteoarticular grafts”) AND (“Bone Tumor” OR (Bone Neoplasm OR Bone Neoplasms OR Bone Cancer OR Cancer of the Bone OR Cancer of Bone OR bone tumor OR bone tumors OR bone tumour OR bone tumours OR bone sarcoma OR bone sarcomas OR Adamantinoma OR Femoral Neoplasms OR Ossifying Fibroma OR Osteoblastoma OR Osteochondroma OR Osteochondromatosis OR Osteoma OR Osteoid Osteoma OR Osteosarcoma OR Osteosarcoma\* OR Ewing Sarcoma OR Multiple Hereditary Exostoses OR Ossifying Fibroma\* OR Osteoblastoma\* OR Osteochondroma\* OR Osteoma\* OR Ewing Sarcoma\*) OR ((Bone\* AND Neoplasm) OR (Bone\* AND Neoplasms) OR (Bone\* AND Cancer) OR (bone\* AND tumor\*) OR (bone\* AND tumour\*) OR (bone\* AND sarcoma\*))))

**ScienceDirect:** TITLE-ABSTR-KEY(((“osteoarticular allograft” OR “osteoarticular allografting” OR “osteoarticular allografts” OR “osteo articular allograft” OR

"osteoarticular knee allografts" OR (("osteoarticular" OR osteoartic\* OR "osteo articular") AND ("bone allograft" OR "allograft" OR allograft\* OR "allo graft" OR allo graft\* OR "allotransplantation" OR Homograft\* OR Homologous Transplant\* OR Allogeneic Transplant\* OR Homologous graft\* OR Allogeneic graft\*)) OR "osteo articular bone grafts" OR "osteoarticular graft" OR "osteoarticular grafts") AND ("Bone Tumor" OR (Bone Neoplasm OR Bone Neoplasms OR Bone Cancer OR Cancer of the Bone OR Cancer of Bone OR bone tumor OR bone tumors OR bone tumour OR bone tumours OR bone sarcoma OR bone sarcomas OR Adamantinoma OR Femoral Neoplasms OR Ossifying Fibroma OR Osteoblastoma OR Osteochondroma OR Osteochondromatosis OR Osteoma OR Osteoid Osteoma OR Osteosarcoma OR Osteosarcoma\* OR Ewing Sarcoma OR Multiple Hereditary Exostoses OR Ossifying Fibroma\* OR Osteoblastoma\* OR Osteochondroma\* OR Osteoma\* OR Ewing Sarcoma\*) OR ((Bone\* AND Neoplasm) OR (Bone\* AND Neoplasms) OR (Bone\* AND Cancer) OR (bone\* AND tumor\*) OR (bone\* AND tumour\*) OR (bone\* AND sarcoma\*))))))

**Appendix 2.** Overview of literature on osteoarticular allograft reconstruction

Data	Gebhardt	Mnaymneh	Kocher	Hornicek	Musco	DeGroot	Musco	Buecker	Musco	Ogilvie	Musco	Toy	Campanacci	Current study
Year	1990	1994	1998	1998	2000	2004	2005	2006	2007	2009	2010	2010	2010	2015
Patients (n)	20	83	24	38	108	31	71	24	38	20	52	26	25	38
Localisations (%)	PH 100	DF 100	DR 100	PT 100	DF 63 PT 37	PH 100	DF 100	DF 42 PT 25 PH 31 DT 4 DH 4 PU 4	DF 73 PT 28 PH 20 DR 5 PU 5	DF 40 PT 30 PH 20 DR 5 PU 5	PT 100	DF 100	DF 52 PT 48	DF 26 PT 37 PH 32 DR 5
Unicondylar reconstructions (%)	-	19	-	-	-	-	-	-	100	-	-	-	-	16
Mean follow-up in months (range)	64 (15 – 138)	N/R (min. 2 yrs)	131 (25 – 268)	72 (24 – 96)	66 (range) N/R, min. 2 yrs	65 (7 – 148)	82 (1 – 368)	36 (12 – 74)	127 (6 – 250)	192 (120 – 252)	123 (10 – 250)	156 (15 – 283)	124 (6 – 226)	150 (7 – 280)
Fixation method (%)	PLT 100	N/R	N/R	PLT 100	PLT 80 IMN 20	PLT 97 IMN+PLT 3	PLT 80 IMN 20	PLT 100	PLT 70 SCR 30	N/R	PLT 86 IMN 14	IMN 96 IMN+PLT 4	PLT 96 IMN 4	PLT 74 IMN 21 SCR 3 IMN+PLT 3
Mean graft length, cm (range)	N/R	N/R (8 – 37)	N/R	N/R	N/R	12 (7 – 20)	N/R	N/R	N/R	N/R	N/R	19 (13.5 – 28)	15.5 (8.5 – 25)	14.5 (8 – 26)
Complications (%)														
Infection	15	6	-	23	11	3	8	17	5	10	22	23	-	13
Fracture	25	14	25	42	2	37	5	13	3	45	5	19	52	26
Nonunion	5	12	-	12	-	20	-	50	-	20	-	19	12	18
Joint instability	5	7	8	17	-	7	-	-	11	-	-	8	20	-
Overall complication rate (%)	65	-	58	-	-	56	-	79	-	70	-	62	68	79
Failure rate	30	24	33	32	46	22	23	29	15	60	34	58	60	53
Mean MSTs score (range)	-	-	-	-	-	75 (57 – 90)	87 (50 – 100)	-	91 (67 – 100)	77 (40 – 93)	87 (range N/R)	-	85 (65 – 97)	-

MSTS, Musculoskeletal Tumor Society; N/R, not reported; DF, distal femur; PT, proximal tibia; DT, distal tibia; PH, proximal humerus; DH, distal humerus; DR, distal radius; PU, proximal ulna; PLT, plate(s); IMN, intramedullary nail; SCR, screw(s). Table only includes studies that reported on ≥ 20 osteoarticular allograft reconstructions.

## References

1. Bielack SS, Kempf-Bielack B, Delling G, Exner GU, Flege S, Helmke K, et al. Prognostic factors in high-grade osteosarcoma of the extremities or trunk: an analysis of 1,702 patients treated on neoadjuvant cooperative osteosarcoma study group protocols. *Journal of clinical oncology : official journal of the American Society of Clinical Oncology*. 2002 Feb 1;20(3):776-90. Epub 2002/02/01.
2. Arndt CA, Crist WM. Common musculoskeletal tumors of childhood and adolescence. *The New England journal of medicine*. 1999 Jul 29;341(5):342-52. Epub 1999/07/29.
3. Bus MP, Dijkstra PD, van de Sande MA, Taminiau AH, Schreuder HW, Jutte PC, et al. Intercalary allograft reconstructions following resection of primary bone tumors: a nationwide multicenter study. *The Journal of bone and joint surgery American volume*. 2014 Feb 19;96(4):e26. Epub 2014/02/21.
4. Quan GM, Slavin JL, Schlicht SM, Smith PJ, Powell GJ, Choong PF. Osteosarcoma near joints: assessment and implications. *Journal of surgical oncology*. 2005 Sep 1;91(3):159-66. Epub 2005/08/25.
5. Pala E, Trovarelli G, Calabro T, Angelini A, Abati CN, Ruggieri P. Survival of Modern Knee Tumor Megaprotheses: Failures, Functional Results, and a Comparative Statistical Analysis. *Clinical orthopaedics and related research*. 2014 May 30. Epub 2014/05/31.
6. Jeys LM, Kulkarni A, Grimer RJ, Carter SR, Tillman RM, Abudu A. Endoprosthetic reconstruction for the treatment of musculoskeletal tumors of the appendicular skeleton and pelvis. *The Journal of bone and joint surgery American volume*. 2008 Jun;90(6):1265-71. Epub 2008/06/04.
7. Goshager G, Gebert C, Ahrens H, Streithuenger A, Winkelmann W, Harnes J. Endoprosthetic reconstruction in 250 patients with sarcoma. *Clinical orthopaedics and related research*. 2006 Sep;450:164-71. Epub 2006/05/13.
8. Bus MP, van de Sande MA, Fiocco M, Schaap GR, Bramer JA, Dijkstra PD. What Are the Long-term Results of MUTARS® Modular Endoprostheses for Reconstruction of Tumor Resection of the Distal Femur and Proximal Tibia? *Clinical orthopaedics and related research*. 2015 Dec 9.
9. Muscolo DL, Ayerza MA, Aponte-Tinao LA, Abalo E, Farfalli G. Unicondylar osteoarticular allografts of the knee. *The Journal of bone and joint surgery American volume*. 2007 Oct;89(10):2137-42. Epub 2007/10/03.
10. Delloye C, Cornu O, Druetz V, Barbier O. Bone allografts: What they can offer and what they cannot. *The Journal of bone and joint surgery British volume*. 2007 May;89(5):574-9. Epub 2007/06/02.
11. Aponte-Tinao L, Farfalli GL, Ritacco LE, Ayerza MA, Muscolo DL. Intercalary femur allografts are an acceptable alternative after tumor resection. *Clinical orthopaedics and related research*. 2012 Mar;470(3):728-34. Epub 2011/06/22.
12. Ortiz-Cruz E, Gebhardt MC, Jennings LC, Springfield DS, Mankin HJ. The results of transplantation of intercalary allografts after resection of tumors. A long-term follow-up study. *The Journal of bone and joint surgery American volume*. 1997 Jan;79(1):97-106. Epub 1997/01/01.
13. Frisoni T, Cevelani L, Giorgini A, Dozza B, Donati DM. Factors affecting outcome of massive intercalary bone allografts in the treatment of tumours of the femur. *The Journal of bone and joint surgery British volume*. 2012 Jun;94(6):836-41. Epub 2012/05/26.
14. Mnaymneh W, Malinin TI, Lackman RD, Hornicek FJ, Ghandur-Mnaymneh L. Massive distal femoral osteoarticular allografts after resection of bone tumors. *Clinical orthopaedics and related research*. 1994 Jun(303):103-15. Epub 1994/06/01.
15. Clohisy DR, Mankin HJ. Osteoarticular allografts for reconstruction after resection of a musculoskeletal tumor in the proximal end of the tibia. *The Journal of bone and joint surgery American volume*. 1994 Apr;76(4):549-54. Epub 1994/04/01.
16. Muscolo DL, Ayerza MA, Aponte-Tinao LA, Ranalletta M. Use of distal femoral osteoarticular allografts in limb salvage surgery. *The Journal of bone and joint surgery American volume*. 2005 Nov;87(11):2449-55. Epub 2005/11/03.
17. Muscolo DL, Ayerza MA, Farfalli G, Aponte-Tinao LA. Proximal tibia osteoarticular allografts in tumor limb salvage surgery. *Clinical orthopaedics and related research*. 2010 May;468(5):1396-404. Epub 2009/12/19.
18. Rodl RW, Ozaki T, Hoffmann C, Bottner F, Lindner N, Winkelmann W. Osteoarticular allograft in surgery for high-grade malignant tumours of bone. *The Journal of bone and joint surgery British volume*. 2000 Sep;82(7):1006-10. Epub 2000/10/21.



19. Toy PC, White JR, Scarborough MT, Enneking WF, Gibbs CP. Distal femoral osteoarticular allografts: long-term survival, but frequent complications. *Clinical orthopaedics and related research*. 2010 Nov;468(11):2914-23. Epub 2010/07/21.
20. de Santos LA, Murray JA, Parrish FF, Wallace S, Finkelstein B, Spjut HJ, et al. Radiographic aspects of massive bone osteoarticular allograft transplantation. *Radiology*. 1978 Sep;128(3):635-41. Epub 1978/09/01.
21. Gebhardt MC, Roth YF, Mankin HJ. Osteoarticular allografts for reconstruction in the proximal part of the humerus after excision of a musculoskeletal tumor. *The Journal of bone and joint surgery American volume*. 1990 Mar;72(3):334-45. Epub 1990/03/01.
22. Kocher MS, Gebhardt MC, Mankin HJ. Reconstruction of the distal aspect of the radius with use of an osteoarticular allograft after excision of a skeletal tumor. *The Journal of bone and joint surgery American volume*. 1998 Mar;80(3):407-19. Epub 1998/04/08.
23. Getty PJ, Peabody TD. Complications and functional outcomes of reconstruction with an osteoarticular allograft after intra-articular resection of the proximal aspect of the humerus. *The Journal of bone and joint surgery American volume*. 1999 Aug;81(8):1138-46. Epub 1999/08/31.
24. DeGroot H, Donati D, Di Liddo M, Gozzi E, Mercuri M. The use of cement in osteoarticular allografts for proximal humeral bone tumors. *Clinical orthopaedics and related research*. 2004 Oct(427):190-7. Epub 2004/11/24.
25. Ogilvie CM, Crawford EA, Hosalkar HS, King JJ, Lackman RD. Long-term results for limb salvage with osteoarticular allograft reconstruction. *Clinical orthopaedics and related research*. 2009 Oct;467(10):2685-90. Epub 2009/02/14.
26. Mankin HJ, Gebhardt MC, Jennings LC, Springfield DS, Tomford WW. Long-term results of allograft replacement in the management of bone tumors. *Clinical orthopaedics and related research*. 1996 Mar(324):86-97. Epub 1996/03/01.
27. Enneking WF, Campanacci DA. Retrieved human allografts : a clinicopathological study. *The Journal of bone and joint surgery American volume*. 2001 Jul;83-a(7):971-86. Epub 2001/07/14.
28. Enneking WF, Dunham W, Gebhardt MC, Malawar M, Pritchard DJ. A system for the functional evaluation of reconstructive procedures after surgical treatment of tumors of the musculoskeletal system. *Clinical orthopaedics and related research*. 1993 Jan(286):241-6. Epub 1993/01/01.
29. Aho AJ, Ekfors T, Dean PB, Aro HT, Ahonen A, Nikkanen V. Incorporation and clinical results of large allografts of the extremities and pelvis. *Clinical orthopaedics and related research*. 1994 Oct(307):200-13. Epub 1994/10/01.
30. O'Connor MI, Sim FH, Chao EY. Limb salvage for neoplasms of the shoulder girdle. Intermediate reconstructive and functional results. *The Journal of bone and joint surgery American volume*. 1996 Dec;78(12):1872-88. Epub 1996/12/01.
31. Judas F, Rosa S, Teixeira L, Lopes C, Ferreira Mendes A. Chondrocyte viability in fresh and frozen large human osteochondral allografts: effect of cryoprotective agents. *Transplantation proceedings*. 2007 Oct;39(8):2531-4. Epub 2007/10/24.
32. Deijkers RL, Bloem RM, Petit PL, Brand R, Vehmeyer SB, Veen MR. Contamination of bone allografts: analysis of incidence and predisposing factors. *The Journal of bone and joint surgery British volume*. 1997 Jan;79(1):161-6. Epub 1997/01/01.
33. Henderson ER, Groundland JS, Pala E, Dennis JA, Wooten R, Cheong D, et al. Failure mode classification for tumor endoprostheses: retrospective review of five institutions and a literature review. *The Journal of bone and joint surgery American volume*. 2011 Mar 2;93(5):418-29. Epub 2011/03/04.
34. Henderson ER, O'Connor MI, Ruggieri P, Windhager R, Funovics PT, Gibbons CL, et al. Classification of failure of limb salvage after reconstructive surgery for bone tumours : a modified system Including biological and expandable reconstructions. *The bone & joint journal*. 2014 Nov;96-b(11):1436-40. Epub 2014/11/06.
35. Teunis T, Nota SP, Hornicek FJ, Schwab JH, Lozano-Calderon SA. Outcome after reconstruction of the proximal humerus for tumor resection: a systematic review. *Clinical orthopaedics and related research*. 2014 Jul;472(7):2245-53.
36. Booth A. PROSPERO's progress and activities 2012/13. *Syst Rev*. 2013 Dec 11;2:111.
37. Gebhardt MC, Flugstad DI, Springfield DS, Mankin HJ. The use of bone allografts for limb salvage in high-grade extremity osteosarcoma. *Clinical orthopaedics and related research*. 1991 Sep(270):181-96. Epub 1991/09/01.



38. Bianchi G, Donati D, Staals EL, Mercuri M. Osteoarticular allograft reconstruction of the distal radius after bone tumour resection. *Journal of hand surgery (Edinburgh, Scotland)*. 2005 Aug;30(4):369-73. Epub 2005/06/14.
39. van de Sande MA, Dijkstra PD, Taminiau AH. Proximal humerus reconstruction after tumour resection: biological versus endoprosthetic reconstruction. *International orthopaedics*. 2011 Sep;35(9):1375-80. Epub 2010/11/19.
40. Szabo RM, Anderson KA, Chen JL. Functional outcome of en bloc excision and osteoarticular allograft replacement with the Sauve-Kapandji procedure for Campanacci grade 3 giant-cell tumor of the distal radius. *The Journal of hand surgery*. 2006 Oct;31(8):1340-8. Epub 2006/10/10.
41. Scoccianti G, Campanacci DA, Beltrami G, Caldora P, Capanna R. The use of osteo-articular allografts for reconstruction after resection of the distal radius for tumour. *The Journal of bone and joint surgery British volume*. 2010 Dec;92(12):1690-4. Epub 2010/12/02.
42. Campanacci L, Manfrini M, Colangeli M, Ali N, Mercuri M. Long-term results in children with massive bone osteoarticular allografts of the knee for high-grade osteosarcoma. *Journal of pediatric orthopaedics*. 2010 Dec;30(8):919-27. Epub 2010/11/26.
43. Hornicek FJ, Jr., Mnaymneh W, Lackman RD, Exner GU, Malinin TI. Limb salvage with osteoarticular allografts after resection of proximal tibia bone tumors. *Clinical orthopaedics and related research*. 1998 Jul;352:179-86. Epub 1998/07/25.
44. Muscolo DL, Ayerza MA, Aponte-Tinai LA. Survivorship and radiographic analysis of knee osteoarticular allografts. *Clinical orthopaedics and related research*. 2000 Apr(373):73-9. Epub 2000/05/16.
45. Potter BK, Adams SC, Pitcher JD, Jr., Malinin TI, Temple HT. Proximal humerus reconstructions for tumors. *Clinical orthopaedics and related research*. 2009 Apr;467(4):1035-41. Epub 2008/09/30.
46. Probyn LJ, Wunder JS, Bell RS, Griffin AM, Davis AM. A comparison of outcome of osteoarticular allograft reconstruction and shoulder arthrodesis following resection of primary tumours of the proximal humerus. *Sarcoma*. 1998;2(3-4):163-70. Epub 2008/06/04.
47. Ramseier LE, Malinin TI, Temple HT, Mnaymneh WA, Exner GU. Allograft reconstruction for bone sarcoma of the tibia in the growing child. *The Journal of bone and joint surgery British volume*. 2006 Jan;88(1):95-9. Epub 2005/12/21.
48. Li J, Jiao Y, Guo Z, Ji C, Wang Z. Comparison of osteoarticular allograft reconstruction with and without the Sauve-Kapandji procedure following tumour resection in distal radius. *Journal of plastic, reconstructive & aesthetic surgery : JPRAS*. 2015 Apr 20. Epub 2015/05/16.
49. Duan H, Zhang B, Yang HS, Liu YH, Zhang WL, Min L, et al. Functional outcome of en bloc resection and osteoarticular allograft reconstruction with locking compression plate for giant cell tumor of the distal radius. *Journal of orthopaedic science : official journal of the Japanese Orthopaedic Association*. 2013 Jul;18(4):599-604. Epub 2013/05/11.
50. Rabitsch K, Maurer-Ertl W, Pirker-Fruhauf U, Lovse T, Windhager R, Leithner A. Reconstruction of the Distal Radius following Tumour Resection Using an Osteoarticular Allograft. *Sarcoma*. 2013;2013:318767. Epub 2013/05/22.
51. San-Julian M, Dolz R, Garcia-Barrecheguren E, Noain E, Sierrasesumaga L, Canadell J. Limb salvage in bone sarcomas in patients younger than age 10: a 20-year experience. *Journal of pediatric orthopaedics*. 2003 Nov-Dec;23(6):753-62. Epub 2003/10/29.
52. Muscolo DL, Ayerza MA, Aponte-Tinai L, Farfalli G. Allograft reconstruction after sarcoma resection in children younger than 10 years old. *Clinical orthopaedics and related research*. 2008 Aug;466(8):1856-62. Epub 2008/05/29.
53. Brien EW, Terek RM, Healey JH, Lane JM. Allograft reconstruction after proximal tibial resection for bone tumors. An analysis of function and outcome comparing allograft and prosthetic reconstructions. *Clinical orthopaedics and related research*. 1994 Jun(303):116-27. Epub 1994/06/01.
54. Buecker PJ, Berenstein M, Gebhardt MC, Hornicek FJ, Mankin HJ. Locking versus standard plates for allograft fixation after tumor resection in children and adolescents. *Journal of pediatric orthopaedics*. 2006 Sep-Oct;26(5):680-5. Epub 2006/08/26.
55. Asavamongkolkul A, Waikakul S, Phimolsarnti R, Kiatisevi P. Functional outcome following excision of a tumour and reconstruction of the distal radius. *International orthopaedics*. 2009 Feb;33(1):203-9. Epub 2007/08/29.
56. Vander Griend RA. The effect of internal fixation on the healing of large allografts. *The Journal of bone and joint surgery American volume*. 1994 May;76(5):657-63. Epub 1994/05/01.

57. Deijkers RL, Bloem RM, Kroon HM, Van Lent JB, Brand R, Taminiou AH. Epidiaphyseal versus other intercalary allografts for tumors of the lower limb. *Clinical orthopaedics and related research*. 2005 Oct;439:151-60. Epub 2005/10/06.
58. Bus MP, Bramer JA, Schaap GR, Schreuder HW, Jutte PC, van der Geest IC, et al. Hemicortical resection and inlay allograft reconstruction for primary bone tumors: a retrospective evaluation in the Netherlands and review of the literature. *The Journal of bone and joint surgery American volume*. 2015 May 6;97(9):738-50.
59. Saunders MM. *Mechanical Testing for the Biomechanics Engineer: A Practical Guide*: Morgan & Claypool Publishers; 2014.
60. Aponte-Tiniao LA, Ayerza MA, Muscolo DL, Farfalli GL. What Are the Risk Factors and Management Options for Infection After Reconstruction With Massive Bone Allografts? *Clinical orthopaedics and related research*. 2015 May 20. Epub 2015/05/21.
61. Racano A, Pazonis T, Farrokhyar F, Deheshi B, Ghert M. High infection rate outcomes in long-bone tumor surgery with endoprosthetic reconstruction in adults: a systematic review. *Clinical orthopaedics and related research*. 2013 Jun;471(6):2017-27. Epub 2013/02/14.
62. Albergo JI, Gaston CL, Aponte-Tiniao LA, Ayerza MA, Muscolo DL, Farfalli GL, et al. Proximal Tibia Reconstruction After Bone Tumor Resection: Are Survivorship and Outcomes of Endoprosthetic Replacement and Osteoarticular Allograft Similar? *Clinical orthopaedics and related research*. 2016 Apr 21.
63. Farfalli GL, Aponte-Tiniao L, Lopez-Millan L, Ayerza MA, Muscolo DL. Clinical and functional outcomes of tibial intercalary allografts after tumor resection. *Orthopedics*. 2012 Mar;35(3):e391-6. Epub 2012/03/06.
64. Myers GJ, Abudu AT, Carter SR, Tillman RM, Grimer RJ. The long-term results of endoprosthetic replacement of the proximal tibia for bone tumours. *The Journal of bone and joint surgery British volume*. 2007 Dec;89(12):1632-7. Epub 2007/12/07.
65. Wang Z, Guo Z, Li J, Li XD, Sang HX. Functional outcomes and complications of reconstruction of the proximal humerus after intra-articular tumor resection. *Orthopaedic surgery*. 2010 Feb;2(1):19-26. Epub 2010/02/01.
66. Staals EL, Colangeli M, Ali N, Casanova JM, Donati DM, Manfrini M. Are Complications Associated With the Repiphysis Expandable Distal Femoral Prosthesis Acceptable for Its Continued Use? *Clinical orthopaedics and related research*. 2015 May 21. Epub 2015/05/23.





# Chapter 8

## **Factors Affecting Nonunion of Allograft-host Junctions in Intercalary Reconstructions of the Femur and Tibia**

M.P.A. Bus<sup>1</sup>

J.I. Albergo<sup>2</sup>

M.A.J. van de Sande<sup>1</sup>

G.L. Farfalli<sup>2</sup>

M.A. Ayerza<sup>2</sup>

L.E. Ritacco<sup>2</sup>

L.A. Aponte-Tinao<sup>2</sup>

P.D.S. Dijkstra<sup>1</sup>

<sup>1</sup>Leiden University Medical Center, Leiden, the Netherlands

<sup>2</sup>Hospital Italiano de Buenos Aires, Buenos Aires, Argentina

*Accepted for publication (Int Orthop)*

## Abstract

**Purpose:** To assess risk factors for nonunion after intercalary allograft reconstruction, and to evaluate if cortical contact at the allograft-host junction results in a decreased likelihood of nonunion.

**Methods:** We retrospectively evaluated 96 osteotomies in 57 patients (34 males, 60%) with an intercalary allograft reconstruction of the femur or tibia for a primary bone tumor. Median follow-up was 8.6 years (95% CI 6.1-11.2). Only one-plane transverse osteotomies with plate fixation were included. The degree of cortical contact was radiographically classified into grades 1 (full contact over the entire length of the osteotomy), 2A ( $\geq 50\%$  contact), 2B ( $< 50\%$  contact), and 3 (lack of cortical contact).

**Results:** There were a total of 15 non-uniting osteotomies (15/96, 16%). Nonunion was the cause for revision surgery in none of the 23 (0%) grade 1, two of 29 (7%) grade 2A, five of 28 (18%) grade 2B, and 8 of 16 (50%) grade 3 junctions. With grade 3 as the reference, the odds ratio for nonunion was 0.22 for grade 2B lesions ( $p=0.03$ ) and 0.01 ( $p=0.003$ ) for grade 2A lesions. Reconstruction site, patient age  $>16$  years, localization within the bone or chemotherapy use did not significantly influence nonunion risk.

**Conclusion:** Our results suggest that the degree of cortical contact at the allograft-host junction is the most important factor for the risk of developing nonunion. Care should be taken to obtain rigid fixation with firm contact at the junction site.

## Introduction

Primary malignant bone tumors of the metadiaphyseal or diaphyseal region of the long bones may be treated with joint-preserving intercalary resections<sup>1,2</sup>. Many techniques have been described for reconstruction after such resections, of which allografts have been most commonly used. Nevertheless, intercalary allografts have been associated with substantial rates of complications. Nonunion is among the major complications (15-55%)<sup>1,3-10</sup> and failure mechanisms (5-7%) of these reconstructions<sup>1,6</sup>.

Nonunion is assumed to result from a complex interplay between biological and mechanical factors, and its treatment is often problematic because one side of the junction is comprised of nonvascular bone<sup>11</sup>. Factors that have been associated with the risk of nonunion include the site of transplantation, use of chemotherapy, radiotherapy, patient age, localization of the osteotomy, and the use of intramedullary nails instead of plates<sup>1,3,6,8,11</sup>. In addition, it has been reported that failure to achieve stable fixation or bone contact at the junction may result in nonunion<sup>12</sup>. However, most studies included small patient groups with heterogeneous reconstructions, and conflicting results have been reported. Therefore, there is little solid evidence on risk factors for nonunion.

With this study, we aimed to evaluate the incidence of, and risk factors for, nonunion in intercalary allograft reconstructions of weight-bearing bones. Moreover, we aimed to evaluate if cortical contact at the allograft-host junction results in a decreased likelihood of nonunion.

## Patients and Methods

### Patient selection

We present a retrospective case series of all patients with an intercalary (whole-circumference) allograft reconstruction for a primary bone tumor of the femur or tibia, from two tertiary referral centers of orthopaedic oncology. From center one, patients who had their operations between 1989 and 2012 were included. From center two, we only included patients who had their operations between 2008 and 2012 because before that time, digital radiographs were not available, and contact at the allograft-host junction could therefore not be determined in a uniform manner. Our primary end-point was union of the allograft-host junction.

Minimum follow-up was 12 months. We excluded patients in whom the allograft was removed or revised within 12 months for reasons other than nonunion.

Intercalary allografts were the preferred method of reconstruction for any patient with a primary bone tumor in whom we considered it possible to resect the tumor with adequate margins while preserving joints. Alternative treatments included vascularized fibular autografts, hybrid reconstructions, or intercalary (custom-made) implants. Osteoarticular allografts<sup>13,14</sup> or modular endoprostheses<sup>15</sup> were used when (part of) a joint had to be sacrificed. To minimize bias with regard to the influence of contact at the allograft-host junction, we chose to only include transverse one-plane osteotomies in reconstructions with plate fixation (either plates alone, or in combination with an intramedullary nail); whenever technically feasible, this was the preferred method for cutting and fixation of allografts in both centers. A prerequisite for inclusion was the availability of digital radiographs in the anteroposterior and lateral direction taken in the first 30 days after surgery, because these radiographs were used to assess the degree of contact at the allograft-host junction.

During the periods under study, a total of 208 osteotomies were performed in 104 patients for an intercalary allograft reconstruction of the femur or tibia. We excluded 112 osteotomies (54%): 29 (26%) because the osteotomy could not be assessed on postoperative imaging, 26 (23%) because imaging from the first postoperative month was not available, 21 (19%) because it was a step-cut or oblique osteotomy, 16 (14%) because other types of osteosynthesis were used, eight (7%) because the reconstruction failed due to other reasons within 12 months after the index procedure, six (5%) because the patient died within 12 months after the index procedure, and four (4%) because the patient was lost to follow-up. This left 96 osteotomies in 57 patients (34 males, 60%) available for analysis. Thirty-seven patients (65%) were operated on in center one, 20 (35%) in center two. Median follow-up was calculated using the reverse Kaplan-Meier method, and was equal to 8.6 years (95% confidence interval [CI], 6.1-11.2).

### **Surgical technique**

Allografts were harvested and processed according to techniques that have been described previously<sup>1,8,16,17</sup>. The diagnoses were based on preoperative biopsy, and the biopsy tracts were excised in continuity with the tumor. Resections were planned on an array of conventional radiographs, magnetic resonance imaging (MRI), and computed tomography (CT). All patients received prophylactic cephalosporin

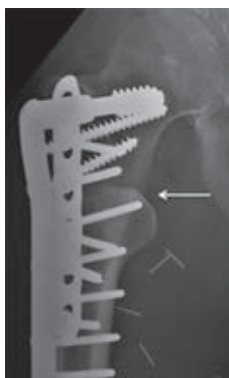


antibiotics. During tumor resections, the allografts were thawed in saline solution. Allografts were cut freehanded<sup>1</sup> or with use of computer navigated techniques<sup>18</sup>. Intraoperatively, the surgeon checked that cortical contact could be obtained. In a subset of our patients, a virtual bone bank system was used to select the allograft that best matched the planned resection<sup>19</sup>. Additional cancellous bone grafting was performed in 11 osteotomies (11%), indications included dissatisfying compression at the osteotomy and suboptimal bone quality at the docking site.

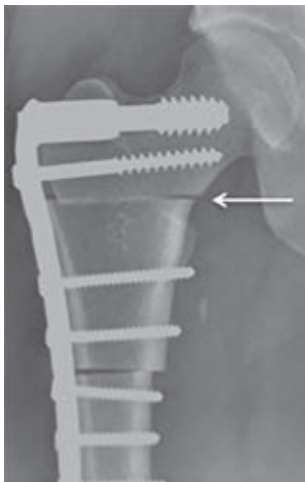
Antibiotics were continued for one to seven days after surgery. Postoperatively, patients were mobilized under supervision of a physical therapist. Routine follow-up included conventional radiographs in two directions. MRI and/or CT scans were obtained in case of (suspected) complications. We recorded patient sex, age at surgery, diagnosis, tumor localization, date of surgery, localization within bone level (diaphyseal or meta-epiphyseal), type of neoadjuvant or adjuvant therapy, total resection length, the use of additional (intramedullary) bone grafts, and muscle flaps.

### Radiographic classification

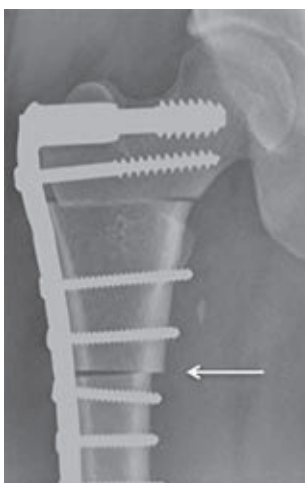
We introduce a novel classification system, in which we classify the degree of contact into grades 1, 2A, 2B, and 3. Grade 1 was defined as full contact over the entire length of the osteotomy in both directions; no radiolucent line was visible. Grade 2 was defined as partial contact and was further divided into grades 2A ( $\geq 50\%$  contact) and 2B ( $< 50\%$  contact). Grade 3 was defined as a lack of cortical contact; a radiolucent line was visible over the entire length of the osteotomy (figures 1-4).



**Figure 1.** Anteroposterior X-ray of a proximal femoral allograft. A radiolucent line cannot be identified; there is full contact (white arrow): grade 1.




**Figure 2:** Anteroposterior X-ray of a proximal femoral allograft. There is  $\geq 50\%$  cortical contact at the proximal osteotomy (white arrow); grade 2A.



**Figure 3:** Anteroposterior X-ray of a proximal femoral allograft. There is  $< 50\%$  cortical contact at the distal osteotomy (white arrow); grade 2B.

All osteotomies were independently assessed and graded by two reviewers (MPAB, JIA) who had not been involved in the care of the patients. In case of disagreement, the reviewers met to reach consensus. The occurrence and time to complications were determined. Nonunion was defined as the lack of consolidation in at least two of the four cortices (anteroposterior and lateral radiographs) at 12 months<sup>1, 6, 11</sup>. Moreover, the junction was considered to be a



**Figure 4:** Lateral X-ray of a tibial allograft. A radiolucent line is visible over the entire length of the osteotomy (white arrow); grade 3.

nonunion if any additional operation had been performed to achieve union or because of problems with the fixation within 12 months after the index procedure – regardless of the eventual outcome<sup>12</sup>.

**Table 1.** Study data

Variable	Number	Percent
<i>Sex</i>		
Male	34	60
Female	23	40
<i>Age</i>		
≤16 years	26	46
>16 years	31	54
<i>Diagnosis</i>		
Osteosarcoma	26	46
Adamantinoma	9	16
Ewing sarcoma	9	16
Chondrosarcoma	7	12
Pleomorphic undifferentiated sarcoma	2	4
Low-grade osteosarcoma	2	4
Sarcoma not otherwise specified	1	2
Synovial sarcoma	1	2
Diffuse-type giant cell tumor	1	2

**Table 1.** continued

Variable	Number	Percent
<i>Reconstruction site</i>		
Femur	39	68
Tibia	18	32
<i>Adjuvant therapies</i>		
Chemotherapy	34	60
None	19	33
Radiotherapy	2	4
Chemo- and radiotherapy	2	4
<i>Osteosynthesis type</i>		
Single plate	31	54
Double plate	23	40
Intramedullary nail + plate	3	5
<i>Status at final follow-up</i>		
No evidence of disease	46	81
Alive with disease	1	2
Died of disease	10	18

## Study data

Median age at surgery was 17 years (range, 2-71 years). Predominant diagnoses were osteosarcoma (n=26, 46%), adamantinoma, and Ewing sarcoma (both; n=9, 16%) (table 1). At follow-up, 46 patients (81%) had no evidence of disease, one patient (2%) was alive with disease, and ten (18%) had died due to disease. Sixty-one osteotomies (64%) were located in the femur, 35 (37%) in the tibia. Sixty-five osteotomies (68%) were diaphyseal, 31 (32%) were meta-epiphyseal. Fifty-six osteotomies (58%) were subjected to (neo)adjuvant chemotherapy, two (2%) to radiotherapy, and two (2%) to both. Osteosynthesis was performed with a single long plate held with cortical screws in 53 osteotomies (55%), with a long plate combined with a separate smaller plate in 39 (41%), and with a plate combined with a nail in four (4%).

## Ethics and statistical analysis

All study procedures were in accordance with the ethical standards of Dutch law (Medical Research involving Human Subjects Act) and with the 1964 Helsinki declaration and its later amendments. For this type of study formal consent is not required.

All data were complete. Logistic regression analyses were used to assess the influence of potential risk factors of the occurrence of nonunion. Outcomes are

expressed in odds ratios (OR), 95% confidence intervals (95% CI) and p-values. SPSS 21.0 (IBM Corp, Armonk, NY, USA) was used for statistical analysis, with the level of significance at  $p < 0.05$ .

## Results

There were a total of 15 non-uniting osteotomies (15/96, 16%). Revision operations for nonunion were performed after a median of 17.5 months (range, 4 months to 9 years) after the index procedure. Twenty-three osteotomies (24%) were classified as grade 1, 29 (30%) as grade 2A, 28 (29%) as grade 2B and 16 (17%) as grade 3, respectfully. The kappa value between the two observers was 0.734 (substantial<sup>20</sup>). The classification of the two observers was identical for 79 osteotomies (82%); further discussion to achieve consensus was needed for 17 osteotomies (18%). Nonunion was the cause for revision surgery in none of the 23 osteotomies that were classified as grade 1, in two of 29 (7%) that were classified as grade 2A, in five of 28 (18%) that were classified as grade 2B, and in 8 of 16 (50%) osteotomies that were classified as grade 3 (Table 2).

**Table 2.** Table showing the number of osteotomies included in each category, the number of osteotomies that were revised for nonunion, and the corresponding odds ratios, 95% confidence intervals and p-values. Because there were zero events in the grade 1 osteotomies, we chose to use grade 3 osteotomies as the reference category. For the same reason, the odds ratio, 95% confidence interval and p-value could not be calculated for grade 1 osteotomies

Classification, category	Total number of osteotomies	Number revised for nonunion	% Non-Union	95% confidence interval		P-value
				Lower	Upper	
Grade 1	23	0	0%	-	-	-
Grade 2A	29	2	7%	0.01	0.42	0.003
Grade 2B	28	5	18%	0.05	0.86	0.03
Grade 3	16	8	50%	Ref.	Ref.	-

Twelve of 61 femoral osteotomies (20%) and three of 35 tibial osteotomies (9%) did not initially heal ( $p=0.149$ ). The risk of nonunion was not significantly associated with patient age, although the risk was slightly lower in patients of 16 years or younger (7/52, 13%) than in patients aged over 16 years (13/60, 22%) ( $p = 0.258$ ). Also, epimetaphyseal junctions appeared to have a slightly lower risk of nonunion (5/40, 13%) than diaphyseal osteotomies (15/72, 21%) ( $p = 0.270$ ).

The risk of nonunion did not differ significantly between patients who received chemotherapy (14/70, 20%) and those who did not (6/42, 14%) ( $p = 0.445$ ).

## Discussion

Nonunion is among the leading causes for failure of intercalary allografts. In this retrospective case series, we evaluated risk factors for nonunion and assessed whether cortical contact at the allograft-host junction results in a decreased likelihood of nonunion.

Our study had a number of limitations. First, we recognize the retrospective design of this study and the selection bias for the patients who were treated in two different countries by two different groups. We were not able to obtain the presence of other potential risk factors, such as smoking status. Second, because digital radiographs were not available before 2008 in one of our centers, we included patients who were treated at different periods in time. However, over the years, little has changed in our perioperative protocols. Third, the number of events was limited and therefore, we could not perform a multivariable analysis. Fourth, the group has some inherent heterogeneity, which could affect the incidence of nonunion. To minimize the risk of bias, we chose to only include one-plane transverse osteotomies that were fixed using one or more plate(s).

Sixteen percent of the osteotomies did not initially heal. Reported rates of nonunion in literature vary from 15 to 50%<sup>1-5, 7, 9, 10, 21, 22</sup>. However, as we noted previously, some studies assessed nonunion per patient, while others scored both osteotomies and therefore score more nonunions, but report a lower percentage of nonunion (table 3)<sup>1</sup>. In addition, previous authors used different definitions of nonunion. Most large studies determined union radiographically<sup>3, 6, 9</sup>. Although some defined nonunion as a lack of progressive healing at six months<sup>23</sup>, most large studies defined nonunion as the lack of cortical continuity in three cortices after 12 months<sup>6, 9</sup>. Apart from that, previously reported incidences may have also included infected nonunions. To avoid bias, we chose to exclude patients with an infection from our study. Nevertheless, in clinical practice, the possibility of infection should always be excluded if a junction does not heal. Clinical workup should include physical examination, laboratory testing (including white blood cell count, C-reactive protein and sedimentation rate), a conventional radiograph or CT-scan and, in case of doubt, leukocyte scintigraphy.

A lack of cortical contact was the most important risk factor for nonunion in our study. None of the osteotomies that demonstrated full contact between the allograft and host bone developed a nonunion. A number of previous studies addressed the influence of gap size on healing of bone defects. Claes *et al*/ showed that primary bone deposition in the metatarsus of sheep occurs in osteotomy gaps of less than 1 mm and that inferior healing occurs in gaps greater than 2 mm<sup>24</sup>. They concluded that treatment of simple diaphyseal fractures is improved when interfragmentary gaps are prevented.

One option to maximize the contact surface between allogeneic and host bone is to use step cut osteotomies, which have been associated with a 74% increase in contact surface as compared with transverse osteotomies<sup>23</sup>. Although step-cut osteotomies may be preferable theoretically, transverse osteotomies are still the technique of choice in our centers, for a number of reasons. First, transverse osteotomies consist of a single cut and are the least technically demanding. Therefore, the chance of obtaining full contact is higher than with more complicated step-cut osteotomies. Second, a transverse osteotomy is the only type of osteotomy in which uniform pressure distribution between can be obtained<sup>23</sup>. Third, in contrast to step cut osteotomies, transverse osteotomies do not require further soft tissue exposure. The limited extent of soft tissue dissection has been described as a factor that contributes to the chance of initial healing of allografts<sup>23, 25</sup>. Fourth, transverse osteotomies are quick and therefore may be associated with a lower risk of infection as compared to more complicated step cut osteotomies.

Frisoni *et al*/analyzed factors affecting outcomes of intercalary femoral allografts<sup>6</sup>. They radiographically reviewed osteotomies to assess contact at the allograft-host junctions, and defined "good contact" as at least two of the four cortices being separated by a radiolucent line of less than 2 mm. They reported that "good" versus "poor" contact did not influence the risk of delayed union. However, it may be questioned how one can reliably or reproducibly measure a gap of 1 to 2 mm on radiographs that have not been taken according to a predefined protocol. In future studies, CT scan images may be used to determine the exact gap size. Because CT images were only available for a small number of patients, we chose to classify the osteotomies in a limited number of categories that could easily and reproducibly be distinguished on conventional radiographs. Indeed, our classification system demonstrated good interrater reliability.

Our results suggest that cortical contact is an important factor for union of allograft-host junctions. The osteoconductive allograft acts as a scaffold for host bone growth; the more contact there is between host bone and the scaffold, and the closer the scaffold is, the quicker incorporation may be expected<sup>26, 27</sup>. Enneking and Campanacci performed a clinicopathological study in 73 retrieved massive allografts. They observed that 'accurate and intimate' contact appeared to promote healing, although they described that incorporation may occur when gaps up to 4 mm are present, as long as the construct is securely immobilized<sup>28</sup>. We concur with Cascio *et al*, stating that attention should be paid to produce rigid, precise contact at the junction<sup>23</sup>. We recommend the use of fluoroscopy in two directions to determine the degree of contact at the osteotomy level, and suggest that a revision of plate fixation or addition of a second plate should be performed in cases in which less than 50% of cortical contact is observed intraoperatively.

In conclusion, the results of this study indicate that the degree of contact at the allograft-host junction is the most important factor for the risk of nonunion. Other factors that may contribute to the risk of nonunion are diaphyseal localization and patient age. Our novel classification system of grading allograft-host contact closely correlated with clinical outcome and demonstrated good interrater reliability. Although future, larger studies will have to confirm our findings, this study suggests that care should be taken to obtain firm cortical contact at the junction.

*Note: we thank Prof. A.H.M. Taminiau, emeritus professor at the Department of Orthopaedic Surgery of the Leiden University Medical Center, and Prof. D.L. Muscolo, professor at the Department of Orthopaedic Surgery of the Italian Hospital of Buenos Aires, for operating on a substantial number of patients included in this study.*



**Table 3.** Overview of literature on allograft reconstructions and reported information on allograft-host nonunions

Data	Aponte-Tiniao (2012)	Ortiz-Cruz (1997)	Bus (2014)	Frisoni (2012)	Muscolo (2004)	Current study
No. of patients	83	100	87	101	59	57
Type of reconstruction	ICA (100)	ICA (100)	ICA (93)	ICA (74)	ICA (100)	ICA (100)
Localizations (%)	FEM (100)	FEM (38), TIB (37), HUM (18), RAD (3), FIB (3), ULN (3)	FEM (51), TIB (39), HUM (8), RAD (2)	HGR (26) FEM (100)	FEM (68), TIB (32)	FEM (68), TIB (32)
Follow-up (range, unless otherwise specified)	Median 61 months (24-182)	Median 67 months (24-220)	Median 84 months (25-262)	Median 112 months (24-238)	Median 60 months (24-262)	Median 103 months (95% CI 73-134)
Fixation method (%)	PLT (65), IMN (19), SCR (16)	S-PLT (80), D-PLT (13), IMN (7)	PLT (71), IMN + PLT (14), IMN (9), SCR (6)	PLT (90), IMN (10)	PLT (52), IMN (33), SCR (16)	S-PLT (55), D-PLT (41), IMN + PLT (5)
Osteotomy type (%)	TRV (100)	N/R	TRV (100)	TRV (80), STC (20)	TRV (100)	TRV (100)
Reconstruction length (range)	N/R	<10 cm: 16%; 10-18 cm: 15%; >18 cm: 28%	Median 14 (5-30)	N/R	N/R	Median 14 (5-30)
Definition of nonunion	N/R	Radiographically; presence of radiolucent line or absence of smooth external continuity of cortical bone at 12 months.	Radiographically; lack of continuity in three cortices after 12 months. Clinically; reoperation for nonunion.	Radiographic; lack of continuity in three cortices after 12 months.	N/R	Radiographically; lack of continuity in two or more cortices after 12 months. Clinically; reoperation for nonunion.
Nonunion - patients (%)	24	30	Radiographic; 26. Clinical; 40.	45	15	27
Nonunion -osteotomies (%)	13	15	N/R	N/R	9	18
Notes regarding nonunion	Higher risk for diaphyseal than for metaphyseal junctions. No influence of fixation type. All nonunions were salvaged with secondary surgery.	Only nonunions that were associated with other complications (infection, fracture) resulted in failure. No significant influence of junction localization or fixation type.	Lower risk in tibial reconstructions. Higher risk after fixation with an intramedullary nail.	Patient age > 18 years; use of postoperative chemotherapy, and osteotomy line distance > 5 cm from the joint line were individual risk factors for nonunion.	Higher risk for diaphyseal than for metaphyseal junctions. Slightly higher risk for diaphyseal junctions fixed with nails than for diaphyseal junctions fixed with plates.	The degree of contact at the junction was the most important factor.

Type of reconstruction: ICA, intercalary allograft; HGR, hybrid graft reconstruction (allograft + vascularized fibular graft). Localizations: FEM, femur; TIB, tibia; HUM, humerus; RAD, radius; FIB, fibula; ULN, ulna. Fixation method: S-PLT, single plate (one long plate); D-PLT, double plates (one long plate combined with a separate smaller plate). Osteotomy type: TRV, transverse; STC, step cut. N/R, not reported.

## References

1. Bus MP, Dijkstra PD, van de Sande MA, Taminiau AH, Schreuder HW, Jutte PC, et al. Intercalary allograft reconstructions following resection of primary bone tumors: a nationwide multicenter study. *The Journal of bone and joint surgery American volume*. 2014 Feb 19;96(4):e26. Epub 2014/02/21.
2. Mankin HJ, Springfield DS, Gebhardt MC, Tomford WW. Current status of allografting for bone tumors. *Orthopedics*. 1992 Oct;15(10):1147-54. Epub 1992/10/01.
3. Aponte-Tiniao L, Farfalli GL, Ritacco LE, Ayerza MA, Muscolo DL. Intercalary femur allografts are an acceptable alternative after tumor resection. *Clinical orthopaedics and related research*. 2012 Mar;470(3):728-34. Epub 2011/06/22.
4. Cara JA, Lacleriga A, Canadell J. Intercalary bone allografts. 23 tumor cases followed for 3 years. *Acta orthopaedica Scandinavica*. 1994 Feb;65(1):42-6. Epub 1994/02/01.
5. Donati D, Di Liddo M, Zavatta M, Manfrini M, Bacci G, Picci P, et al. Massive bone allograft reconstruction in high-grade osteosarcoma. *Clinical orthopaedics and related research*. 2000 Aug(377):186-94. Epub 2000/08/16.
6. Frisoni T, Cevolani L, Giorgini A, Dozza B, Donati DM. Factors affecting outcome of massive intercalary bone allografts in the treatment of tumours of the femur. *The Journal of bone and joint surgery British volume*. 2012 Jun;94(6):836-41. Epub 2012/05/26.
7. Gerrand CH, Griffin AM, Davis AM, Gross AE, Bell RS, Wunder JS. Large segment allograft survival is improved with intramedullary cement. *Journal of surgical oncology*. 2003 Dec;84(4):198-208. Epub 2004/02/06.
8. Muscolo DL, Ayerza MA, Aponte-Tiniao L, Ranalletta M, Abalo E. Intercalary femur and tibia segmental allografts provide an acceptable alternative in reconstructing tumor resections. *Clinical orthopaedics and related research*. 2004 Sep(426):97-102. Epub 2004/09/04.
9. Ortiz-Cruz E, Gebhardt MC, Jennings LC, Springfield DS, Mankin HJ. The results of transplantation of intercalary allografts after resection of tumors. A long-term follow-up study. *The Journal of bone and joint surgery American volume*. 1997 Jan;79(1):97-106. Epub 1997/01/01.
10. Zimel MN, Cizik AM, Rapp TB, Weisstein JS, Conrad EU, 3rd. Megaprosthesis versus Condyle-sparing intercalary allograft: distal femoral sarcoma. *Clinical orthopaedics and related research*. 2009 Nov;467(11):2813-24. Epub 2009/08/08.
11. Hornicek FJ, Gebhardt MC, Tomford WW, Sorger JI, Zavatta M, Menzner JP, et al. Factors affecting nonunion of the allograft-host junction. *Clinical orthopaedics and related research*. 2001 Jan(382):87-98. Epub 2001/01/12.
12. Vander Griend RA. The effect of internal fixation on the healing of large allografts. *The Journal of bone and joint surgery American volume*. 1994 May;76(5):657-63. Epub 1994/05/01.
13. Muscolo DL, Ayerza MA, Aponte-Tiniao LA, Ranalletta M. Use of distal femoral osteoarticular allografts in limb salvage surgery. *The Journal of bone and joint surgery American volume*. 2005 Nov;87(11):2449-55. Epub 2005/11/03.
14. Muscolo DL, Ayerza MA, Farfalli G, Aponte-Tiniao LA. Proximal tibia osteoarticular allografts in tumor limb salvage surgery. *Clinical orthopaedics and related research*. 2010 May;468(5):1396-404. Epub 2009/12/19.
15. Bus MP, van de Sande MA, Fiocco M, Schaap GR, Bramer JA, Dijkstra PD. What Are the Long-term Results of MUTARS® Modular Endoprostheses for Reconstruction of Tumor Resection of the Distal Femur and Proximal Tibia? *Clinical orthopaedics and related research*. 2015 Dec 9.
16. Bus MP, Bramer JA, Schaap GR, Schreuder HW, Jutte PC, van der Geest IC, et al. Hemicortical resection and inlay allograft reconstruction for primary bone tumors: a retrospective evaluation in the Netherlands and review of the literature. *The Journal of bone and joint surgery American volume*. 2015 May 6;97(9):738-50.
17. Ottolenghi C, Muscolo D, Maenza R. Bone defect reconstruction by massive allograft: technique and results of 51 cases followed for 5 to 32 years. *Clinical trends in orthopedics New York: Thieme-Stratton*. 1982;1982:171-83.
18. Ritacco LE, Milano FE, Farfalli GL, Ayerza MA, Muscolo DL, Aponte-Tiniao LA. Accuracy of 3-D planning and navigation in bone tumor resection. *Orthopedics*. 2013 Jul;36(7):e942-50. Epub 2013/07/05.

19. Ritacco LE, Farfalli GL, Milano FE, Ayerza MA, Muscolo DL, Aponte-Tinao L. Three-dimensional virtual bone bank system workflow for structural bone allograft selection: a technical report. *Sarcoma*. 2013;2013:524395. Epub 2013/05/22.
20. Landis JR, Koch GG. The measurement of observer agreement for categorical data. *Biometrics*. 1977 Mar;33(1):159-74.
21. Brunet O, Anract P, Bouabid S, Babinet A, Dumaine V, Tomeno B, et al. Intercalary defects reconstruction of the femur and tibia after primary malignant bone tumour resection. A series of 13 cases. *Orthopaedics & traumatology, surgery & research : OTSR*. 2011 Sep;97(5):512-9. Epub 2011/07/12.
22. Bullens PH, Minderhoud NM, de Waal Malefijt MC, Veth RP, Buma P, Schreuder HW. Survival of massive allografts in segmental oncological bone defect reconstructions. *International orthopaedics*. 2009 Jun;33(3):757-60. Epub 2008/12/04.
23. Cascio BM, Thomas KA, Wilson SC. A mechanical comparison and review of transverse, step-cut, and sigmoid osteotomies. *Clinical orthopaedics and related research*. 2003 Jun(411):296-304. Epub 2003/06/05.
24. Claes L, Augat P, Suger G, Wilke HJ. Influence of size and stability of the osteotomy gap on the success of fracture healing. *Journal of orthopaedic research : official publication of the Orthopaedic Research Society*. 1997 Jul;15(4):577-84.
25. Deijkers RL, Bloem RM, Hogendoorn PC, Verlaan JJ, Kroon HM, Taminiau AH. Hemicortical allograft reconstruction after resection of low-grade malignant bone tumours. *The Journal of bone and joint surgery British volume*. 2002 Sep;84(7):1009-14. Epub 2002/10/03.
26. Greenwald AS, Boden SD, Goldberg VM, Khan Y, Laurencin CT, Rosier RN, et al. Bone-graft substitutes: facts, fictions, and applications. *The Journal of bone and joint surgery American volume*. 2001;83-A Suppl 2 Pt 2:98-103.
27. Zimmermann G, Moghaddam A. Allograft bone matrix versus synthetic bone graft substitutes. *Injury*. 2011 Sep;42 Suppl 2:S16-21.
28. Enneking WF, Campanacci DA. Retrieved human allografts : a clinicopathological study. *The Journal of bone and joint surgery American volume*. 2001 Jul;83-a(7):971-86. Epub 2001/07/14.



# Chapter 9

## **What Are the Long-term Results of MUTARS® Modular Endoprotheses for Reconstruction of Tumor Resection of the Distal Femur and Proximal Tibia?**

M.P.A. Bus<sup>1</sup>

M.A.J. van de Sande<sup>1</sup>

M. Fiocco<sup>2,3</sup>

G.R. Schaap<sup>4</sup>

J.A.M. Bramer<sup>4</sup>

P.D.S. Dijkstra<sup>1</sup>

<sup>1</sup>Orthopaedic Surgery, Leiden University Medical Center, Leiden, the Netherlands

<sup>2</sup>Medical Statistics and Bioinformatics, Leiden University Medical Center, Leiden, the Netherlands

<sup>3</sup>Mathematical Institute, Leiden University, Leiden, The Netherlands

<sup>4</sup>Orthopaedic Surgery, Academic Medical Center, Amsterdam, the Netherlands

*Clin Orthop Relat Res. 2017 Mar; 475(3): 708–718.*

## Abstract

**Background:** Modular endoprostheses are commonly used to reconstruct defects of the distal femur and proximal tibia after bone tumor resection. Because limb salvage surgery for bone sarcomas is relatively new, becoming more frequently used since the 1980s, studies focusing on the long-term results of such prostheses in treatment of primary tumors are scarce.

**Questions / purposes:** (1) What proportion of patients experience a mechanical complication with the MUTARS modular endoprosthesis when used for tumor reconstruction around the knee, and what factors may be associated with mechanical failure? (2) What are the non-mechanical complications? (3) What are the implant failure rates at five, ten, and 15 years? (4) How often is limb salvage achieved using this prosthesis?

**Methods:** Between 1995 and 2010, endoprostheses were the preferred method of reconstruction after resection of the knee in adolescents and adults in our centers. During that period, we performed 114 MUTARS knee replacements in 105 patients; no other endoprosthetic systems were used. Four patients (four of 105 [4%]) were lost to follow-up, leaving 110 reconstructions in 101 patients for review. The reverse Kaplan-Meier method was used to calculate median follow-up, which was equal to 8.9 years (95% confidence interval [CI], 8.0 – 9.7). Mean age at surgery was 36 years (range, 13 – 82 years). Predominant diagnoses were osteosarcoma ( $n = 56$  [55%]), leiomyosarcoma of bone ( $n = 10$  [10%]), and chondrosarcoma ( $n = 9$  [9%]). In the early period of our study, we routinely used uncemented uncoated implants for primary reconstructions. Later, hydroxyapatite (HA)-coated implants were the standard. Eighty-nine reconstructions (89 of 110 [81%]) were distal femoral replacements (78 uncemented [78 of 89 {88%}], 42 of which were HA-coated [42 of 78, 54%]) and 21 (21 of 110 [19%]) were proximal tibial replacements. In 26 reconstructions (26 of 110 [24%]), the reconstruction was performed for a failed previous reconstruction. We used a competing risk model to estimate the cumulative incidence of implant failure.

**Results:** Complications of soft tissue or instability occurred in seven reconstructions (seven of 110 [6%]). With the numbers we had, for uncemented distal femoral replacements, we could not detect a difference in loosening between revision

(five of 17 [29%]) and primary reconstructions (eight of 61 [13%]) (hazard ratio [HR], 1.72; 95% CI, 0.55 – 5.38;  $p = 0.354$ ). Hydroxyapatite-coated uncemented implants had a lower risk of loosening (two of 42 [5%]) than uncoated uncemented implants (11 of 36 [31%]) (HR, 0.23; 95% CI, 0.05 – 1.06;  $p = 0.060$ ). Structural complications occurred in 15 reconstructions (15 of 110 [14%]). Infections occurred in 14 reconstructions (14 of 110 [13%]). Ten patients had a local recurrence (10 of 101 [10%]). With failure for mechanical reasons as the endpoint, the cumulative incidences of implant failure at five, ten, and 15 years were 16.9% (95% CI, 9.6 – 24.2), 20.7% (95% CI, 12.5 – 28.8%), and 37.9% (95% CI, 16.1 – 59.7), respectively. We were able to salvage some of the failures so that at follow-up, 90 patients (90 of 101 [89%]) had a MUTARS *in situ*.

**Conclusions:** Although no system has yet proved ideal to restore normal function and demonstrate long-term retention of the implant, MUTARS modular endoprostheses represent a reliable long-term option for knee replacement after tumor resection, which seems to be comparable to other modular implants available to surgeons. Although the number of patients is relatively small, we could demonstrate that with this prosthesis, an uncemented HA-coated implant is useful in achieving durable fixation.

## Introduction

Various techniques have been described for management of reconstruction of malignant tumors about the knee in adults, including implantation of osteoarticular allografts<sup>1,2</sup>, allograft-prosthetic composites<sup>3,4</sup> and custom-made<sup>5,6</sup> or modular<sup>7,8</sup> endoprostheses. Endoprosthetic reconstruction likely is the most commonly used approach, in part as a result of the ease of use compared with other options and the difficulty of obtaining allografts in some centers in addition to the reported risks of nonunion, fracture, and infection<sup>5,6,9</sup>. Potential advantages of endoprostheses include their relative availability, immediate stability, the possibility of rapid recovery, and early weight-bearing<sup>6</sup>. Compared with custom-made implants, modular endoprostheses provide the ability to adjust the proper length at the time of the reconstruction<sup>10</sup>.

Nevertheless, revisions of endoprosthetic reconstructions occur frequently. Infection, occurring in 6% to 20% of patients, is the leading cause of failure in the early years after surgery<sup>5,6,8,11-14</sup>. In the longer term, mechanical complications are the main concern, most notably aseptic loosening, periprosthetic fractures, and wear<sup>7,15,16</sup>. Because the survival of patients with bone sarcomas has improved, and most patients with primary bone tumors are young and active and place high demands on their implants, improving implant designs and reconstructive techniques are essential to reduce the risk of mechanical complications<sup>6</sup>. The MUTARS system (Modular Universal Tumor And Revision System; implantcast, Buxtehude, Germany; FDA approval pending) was introduced in 1992 and has since been widely used in Europe, Australia, and various Asian countries; results of its use in both orthopaedic oncology and revision surgery have been documented<sup>7,17,18</sup>. To our knowledge, no studies have evaluated the intermediate- to long-term results of the MUTARS knee replacement system in primary tumor reconstructions and revision procedures.

We therefore asked: (1) What proportion of patients experience a mechanical complication with the MUTARS modular endoprosthesis when used for tumor reconstruction around the knee, and what factors may be associated with mechanical failure? (2) What are the non-mechanical complications? (3) What is the cumulative incidence of implant failure at five, ten, and 15 years? (4) How often is limb salvage achieved using this prosthesis?



## Patients and Methods

We present a retrospective case series of all patients with a primary malignant or aggressive benign bone or soft tissue tumor in whom a MUTARS distal femoral or proximal tibial replacement was performed for primary reconstruction or for revision of a failed previous reconstruction. Institutional databases were searched to identify patients who had MUTARS reconstruction between 1995 and 2010 with a minimum follow-up of five years. During the early period under study, we performed a limited number of osteoarticular allograft reconstructions, mainly in young patients. In case it was possible to save adjacent joints, we preferred to perform an intercalary resection and reconstructed the defect with an allograft<sup>9, 19</sup>. Generally speaking, endoprosthetic reconstruction was the preferred method of reconstruction when resection of the knee was deemed inevitable in adolescents and adults. No other endoprosthetic systems have been used in our centers. We performed a total of 114 MUTARS reconstructions about the knee during the period in question in 105 patients. Four patients (four of 105 [4%]) were lost to follow-up, leaving 110 reconstructions in 101 patients for review; of these, 64 (64 of 101 [63%]) were alive at final review. The reverse Kaplan-Meier method was used to calculate the median follow-up, which was equal to 8.9 years (95% confidence interval [CI], 8.0 – 9.7) (table 1).

**Table 1.** Study data

Variable	Number	Percent of relevant group
<i>Sex</i>		
Male	55	55
Female	46	45
<i>Diagnosis</i>		
Osteosarcoma	56	55
Leiomyosarcoma of bone	10	10
Chondrosarcoma	9	9
Giant cell tumor of bone	8	8
Pleomorphic undifferentiated sarcoma	7	7
Ewing sarcoma	5	5
Low-grade osteosarcoma	2	2
Sarcoma not otherwise specified	2	2
Synovial sarcoma	1	1
Diffuse-type giant cell tumor	1	1

**Table 1.** continued

Variable	Number	Percent of relevant group
<i>Reconstruction site</i>		
Distal femur	89	81
Proximal tibia	21	19
<i>Neoadjuvant and adjuvant therapies (around implantation of MUTARS)</i>		
Neoadjuvant chemotherapy	61	60
Adjuvant chemotherapy	64	63
Neoadjuvant radiotherapy	2	2
Adjuvant radiotherapy	4	4
<i>Reconstruction details</i>		
Conventional polyethylene locking mechanism	39	35
PEEK-OPTIMA locking mechanism	71	65
Extensor reconstruction	19	17
MUTARS attachment tube used	16	15
<i>Complications</i>		
Type I (soft tissue, instability)	7	6
Type II (aseptic loosening)	17	16
Type III (structural)	15	14
Type IV (infection)	14	13
Type V (tumor progression)	10	10
<i>Failure</i>		
Any type of revision, including re-fixation	40	36
Major revision / removal entire prosthesis	27	25
<i>Status at final follow-up</i>		
No evidence of disease	64	63
Alive with disease	-	-
Died of disease	34	34
Died of other cause	3	3

All diagnoses were proven histologically before operation. The feasibility of limb-salvaging resection was evaluated on MRI. In the case of suspected joint involvement, an extra-articular resection was performed removing the joint *en bloc* with the patella cut in the coronal plane. Of 84 implants (84 of 110 [76%]) that were implanted for primary reconstruction after tumor resection, 39 (46%) had an extra-articular resection. Twenty-six implants (26 of 110 [24%]) were implanted as a revision of a failed reconstruction, including nine MUTARS and 17 other reconstructions (table 2).

A lateral or medial parapatellar approach was used; this depended on the location of the tumor and biopsy tract, which was excised in continuity with the

tumor. In all cases, we used a rotating hinged MUTARS distal femoral or proximal tibial replacement. A polyethylene locking mechanism connected the femoral and tibial components. Until March 2003, we used the conventional polyethylene lock. From then onward, the PEEK-OPTIMA (Invibio Ltd, Thornton-Cleveleys, UK) lock was used. Extension of the implant was possible in 20-mm increments. All stems and extension pieces were equipped with sawteeth at the junctions to allow rotational adjustment in 5° increments. The hexagonally shaped stems were available for uncemented (TiAl6V4) or cemented (CoCrMo) fixation. Femoral stems were curved to match the natural anterior curvature of the femoral diaphysis. We generally preferred uncemented fixation, unless we were unable to obtain adequate press-fitting or in cases in which bone quality was deemed insufficient for uncemented fixation. In the early period under study, we routinely used uncemented uncoated implants because at that time, the MUTARS system did not come with hydroxyapatite (HA)-coated stems standardly; HA-coated stems were mainly used in cases with a presumed higher risk of loosening such as patients with a failed previous reconstruction. Later, HA-coated implants were the standard for primary reconstruction. The medullary cavity was reamed with a hexagonal rasp to secure optimal contact between the bone and implant. In case of uncemented fixation, the medullary cavity was under-reamed by 1 mm. In case of cemented fixation, we over-reamed the canal for 2 mm and third-generation cementing techniques were used.

**Table 2.** Procedures performed before implantation of the primary MUTARS, subsequent reconstructions, and reasons for failure.

Procedure	Reconstruction	Number	Reason(s) for reconstruction failure
<i>En bloc</i> resection	Allograft prosthetic composite	6	Allograft collapse (n = 2), allograft fracture (n = 2), nonunion (n = 1), infection (n = 1)
	Kotz prosthesis	4	Prosthetic fracture (n = 2), loosening (n = 1), infection (n = 1)
	Intercalary allograft	3	Nonunion (n = 2), allograft fracture (n = 1)
	Osteoarticular allograft	2	Allograft fracture
	Extracorporeally radiated autograft	1	Resorption
	Inlay allograft	1	Recurrence
Curettage	Cancellous bone grafting	5	Recurrence
	Cement	3	Recurrence
Arthroplasty	TKA	1	-

In cases in which an extensor mechanism reconstruction had to be performed, we ran non-absorbable sutures through the designated holes in the tibial component to fix an attachment tube (implantcast) to the implant; the extensor mechanism was later attached to the tube, again using non-absorbable sutures. After assemblage of the prosthesis, a trial reduction was performed. A final check was performed to assess knee motion and soft tissue tension and subsequently, the implant was locked.

All patients received prophylactic intravenous cephalosporins before surgery; these were continued for one to five days. Drains were removed after a maximum of 48 hours. Based on pain, patients were mobilized under supervision of a physical therapist, usually on the first postoperative day. Antithrombotic prophylaxis was given until 6 weeks postoperatively.

Patients were followed during outpatient visits at two and six weeks after discharge, after three and six months, and every six months thereafter. Radiographic follow-up consisted of conventional radiographs and additional imaging (CT/ MRI) if complications or recurrence were suspected.

Complications and failures were recorded and classified according to Henderson *et al*<sup>15, 20</sup>. Aseptic loosening was defined as migration of the prosthesis on imaging (periprosthetic lucency on conventional radiographs or CT scan or halo formation on CT) in the absence of infection. We however chose to report on the clinical rather than radiological loosening, i.e., those that required revision, partly because it can be hard to determine which cases are at risk for future failure/ loosening, and it is therefore difficult to reliably comment on the occurrence and significance of these signs. Radiographic signs alone were not observed as a reason for implant failure. Rates of aseptic loosening were compared between primary and revision reconstructions (arthroscopy, curettage, and conventional TKA were not considered as previous reconstructions). Periprosthetic and prosthetic fractures were diagnosed on imaging or intraoperatively. Infection was defined as any deep (periprosthetic) infectious process diagnosed through physical examination, imaging, laboratory tests (including C-reactive protein, erythrocyte sedimentation rate, and synovial fluid leukocyte count) and microbiologic cultures.

## Statistical Analysis

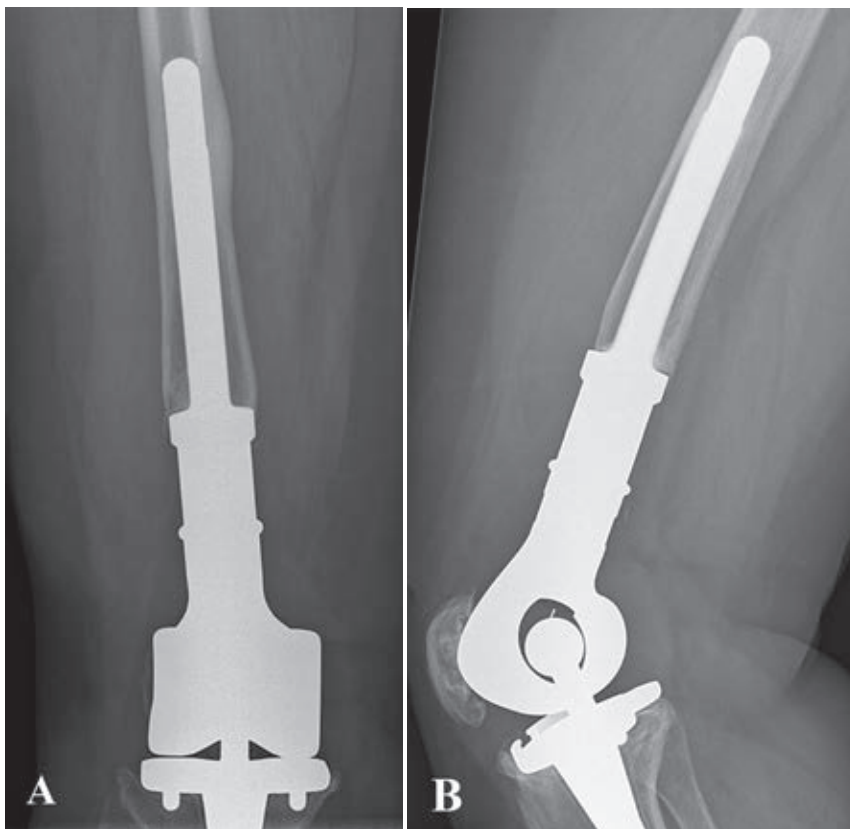
All data were complete. To estimate the cumulative incidence of revision for different types of failure, a competing risks model was used with patient mortality as a competing event<sup>21, 22</sup>. Failures were defined as removal of part of or all of the

implant, major revision (exchange of the femoral component, tibial component, or the locking mechanism), or cemented re-fixation as the endpoint. Failure did not include isolated revision of the bushing. The influence of potential risk factors on the cumulative incidence of revision was determined with Cox regression analyses. SPSS 21.0 (IBM Corp, Armonk, NY, USA) was used for statistical analysis (level of significance,  $p < 0.050$ ). All analyses for the competing risk models have been performed with the *mstate* library<sup>23</sup> in the R software package<sup>24</sup>.

Mean age at surgery was 36 years (range, 13 – 82 years). Predominant diagnoses were osteosarcoma ( $n = 56$  [55%]), leiomyosarcoma of bone ( $n = 10$  [10%]), chondrosarcoma ( $n = 9$  [9%]), giant cell tumor of bone ( $n = 8$  [8%]), and pleomorphic undifferentiated sarcoma ( $n = 7$  [7%]). Sixty-four patients (64 of 101 [63%]) were treated with chemotherapy (according to appropriate protocols) around the period of MUTARS implantation and four (four of 101 [4%]) underwent radiotherapy.

Eighty-nine reconstructions (81%) were distal femoral replacements and 21 (19%) were proximal tibial replacements. Eleven distal femoral replacements (11 of 89 [12%]) had a cemented femoral stem. Of 78 uncemented distal femoral replacements (78 of 89 [88%]), 42 were HA-coated (42 of 78 [54%]). All proximal tibial replacements had an uncemented tibial stem, 12 of which were HA-coated (12 of 19 [57%]) (figures 1A–B); one (one of 21 [5%]) had a cemented femoral stem. Patellar components were used in 37 distal femoral replacements (37 of 89 [42%]) and in three proximal tibial replacements (three of 21 [14%]). Median total resection length was 16 cm (range, 12 – 30 cm) for distal femoral replacements and 14 cm (range, 12 – 26 cm) for proximal tibial replacements. Attachment tubes were used in 14 proximal tibial replacements (14 of 21 [67%]) and in two distal femoral replacements (two of 89 [2%]). An extensor reconstruction was performed in 11 proximal tibial replacements (11 of 21 [58%]) and six distal femoral replacements (six of 89 [7%]). Rotation of a gastrocnemius muscle flap was performed in four proximal tibial replacements (four of 21 [19%], in one case combined with a split skin graft). Allogeneic fascia lata were used in six distal femoral replacements (six of 89 [7%]) and in two proximal tibial replacements (two of 21 [10%]). Three implants (three of 110 [3%]) were silver-coated.

During tumor resection, clear surgical margins were obtained in 95 patients (95 of 101 [94%]). Two patients (two of 101 [2%]) with giant cell tumors had intentional intralesional surgery. Four patients (four of 101 [5%]) had contaminated margins.



**Figures 1A-B.** Conventional AP (A) and lateral (B) radiographs taken 6 years after extra-articular resection for an osteosarcoma of the distal femur in a 46-year-old female patient. The defect was reconstructed with an uncemented HA-coated MUTARS distal femoral replacement with a PEEK-OPTIMA locking mechanism. The postoperative course was uncomplicated and no further procedures were undertaken.

## Results

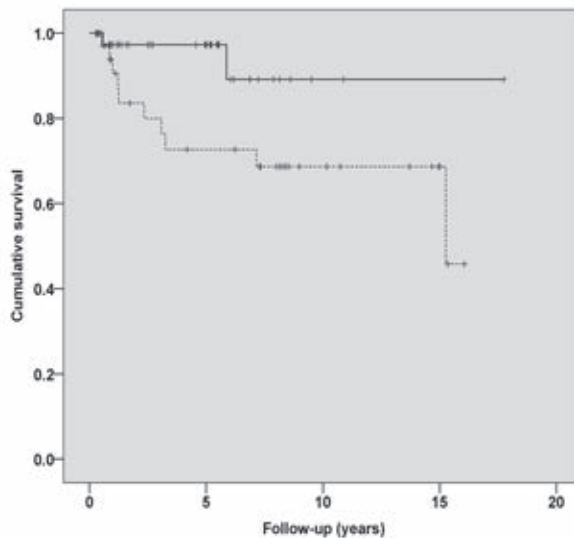
### Mechanical Complications

Complications of soft tissue or instability (Henderson type 1) occurred in seven reconstructions (seven of 110 [6%], six distal femoral replacements, one proximal tibial replacement) after a median of five months (range, 0 – 46 months). These complications included skin necrosis ( $n = 2$  [two of 110, 2%]), flexion contracture ( $n = 2$  [two of 110, 2%]), and patellar dislocation ( $n = 1$  [one of 110, 1%]).

One patient underwent surgery for extensor mechanism insufficiency ( $n = 1$  [one of 110, 1%]). We could not identify factors associated with the occurrence of

type 1 complications. No type 1 complication resulted in removal or revision of the prosthesis.

Aseptic loosening (Henderson type 2) occurred in 15 distal femoral replacements (15 of 89 [17%]) and two proximal tibial replacements (two of 21 [10%]) after a median of 1.2 years (range, 0.5 – 15 years). Both proximal tibial replacements had loosening of the femoral component (both uncemented, one HA-coated), for which cemented re-fixation was undertaken. Of the 15 distal femoral replacements, nine had loosening of the femoral component, three of the tibial component, and three of both components. Treatment consisted of cemented re-fixation ( $n = 6$ ), uncemented revision of the femoral component ( $n = 4$ ), cemented revision ( $n = 4$ ), and a total femoral replacement (as a result of poor remnant host bone) ( $n = 1$ ). With the numbers we had, for uncemented distal femoral replacements, we could not detect an association between reconstruction length and the rate of loosening (hazard ratio [HR], 1.06; 95% CI, 0.93 – 1.21;  $p = 0.393$ ) nor a difference in loosening between revision (five of 17 [29%]) and primary reconstructions (eight of 61 [13%]) (HR, 1.72; 95% CI, 0.55 – 5.38;  $p = 0.354$ ). Uncemented HA-coated distal femoral replacements had a lower risk of loosening (two of 42 [5%]) than uncemented uncoated implants (11 of 36 [31%]) (HR, 0.23; 95% CI, 0.05 – 1.06;  $p = 0.060$ ) (figure 2).



**Figure 2.** Kaplan-Meier curve showing survival to the occurrence of loosening for uncemented uncoated (blue line,  $n = 36$ ) and uncemented HA-coated (green line,  $n = 42$ ) distal femoral replacements.

Structural complications (Henderson type 3) occurred in 15 reconstructions (15 of 110 [14%]) after a mean of three years (range, 0.0 – 13.5 years). These included six complications of the locking mechanism: three fractures, two instances of wear, and one unlocking of the locking mechanism. Four occurred in PEEK-OPTIMA locks. There were four periprosthetic fractures occurring at three weeks, eight months, 20 months, and six years, respectively. There were three fractures of the femoral component, two with a 12-mm core diameter and a defect of 17.5 and 21.5 cm and one with a 16-mm core diameter stem with a defect of 15.5 cm. These stem fractures occurred two, four, and four years, respectively. There was one fractured insert and one implant rotation deformity.

Two prosthetic fractures and one periprosthetic fracture resulted in revision or removal of the entire implant; others were managed either conservatively or with limited revision procedures such as fixation of the periprosthetic fracture with a small plate, relocking of the locking mechanism, or revision of the locking mechanism. In addition, undisplaced fissure fractures occurred during implantation in 11 reconstructions: nine distal femoral replacements and two proximal tibial replacements. All healed uneventfully. Replacement of the bushings was performed in nine reconstructions (nine of 110 [8%]) after a mean of six years (range, 0.1 – 18 years).

### **Non-mechanical Complications**

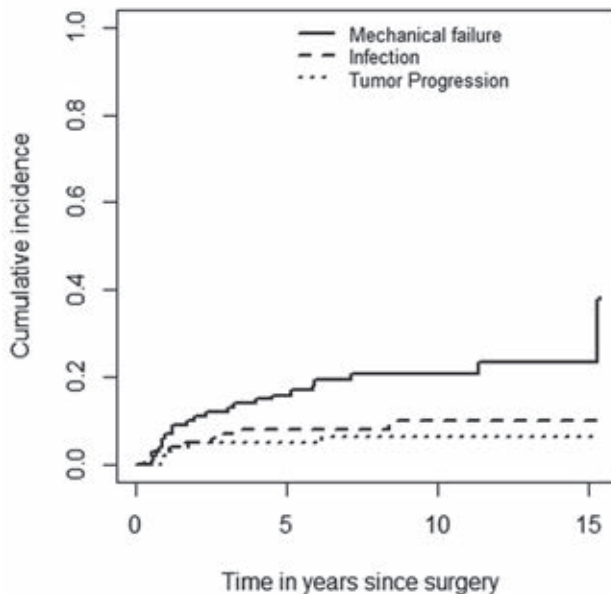
Deep infections (Henderson type 4) occurred in 15 reconstructions (15 of 110 [14%]). According to the Henderson classification, nine infections were early (<2 years after implantation [nine of 110, 8%]) and six were late (six of 110 [5%]). Three early-infected implants were retained. Three late infections occurred after operative intervention for another complication; of these, two were retained.

Local recurrences (Henderson type 5) occurred in ten patients (ten of 101 [10%]) after a mean of two years (range, 0.8 – 6 years). All patients who developed a local recurrence had clear surgical margins during the index resection. Two patients had received radiotherapy (one leiomyosarcoma, one high-grade osteosarcoma of an unusual subtype). Treatment consisted of ablative surgery in seven patients and of a second limb-salvaging resection (without removing the implant) in two. In one patient no further treatment was undertaken as a result of a poor prognosis. Focusing on patients without prior resections, local recurrences occurred in five of 39 patients with an extra-articular resection (13%) and in four of 45 patients with an intra-articular resection (9%) ( $p = 0.561$ ).



### Implant Failure Rates

With failure for mechanical reasons (types 1 – 3) as the endpoint, the cumulative incidences of implant failure at five, ten, and 15 years were 16.9% (95% CI, 9.6 – 24.2), 20.7% (95% CI, 12.5 – 28.8), and 37.9% (95% CI, 16.1 – 59.7), respectively (figure 3). With failure for infection (type 4) as the endpoint, these were 7.9% (95% CI, 2.7 – 13.2), 10.0% (95% CI, 3.5 – 16.4), and 10.0% (95% CI, 3.5 – 16.4), respectively. With failure from tumor progression (type 5) as the endpoint, these were 5.0% (95% CI, 0.7 – 9.2), 6.2% (95% CI, 1.4 – 11.0), and 6.2% (95% CI, 1.4 – 11.0), respectively. None of the assessed variables (extra-articular resection, HA coating of uncemented implants, reconstruction length of > 16 cm, adjuvant therapy, or having a preceding reconstruction) was found to have been associated with differences in implant survival in univariable Cox regression analyses.



**Figure 3.** Competing-risk analyses of implant failure. This plot shows the cumulative incidence of mechanical failure (type 1 – 3), infection (type 4), and tumor progression (type 5). Patient mortality was used as a competing event in these analyses.

### Limb Salvage

Limb salvage was achieved in 91 patients (90%). In total, 64 of 101 patients had their original MUTARS *in situ* without re-fixation, partial revision, or major revision/removal of the implant. Not all failures required a second MUTARS because

some cases of failure were managed while the same implant was in place (for example the cases of loosening that were managed with cemented re-fixation of the implant or failure of the locking mechanism, which was managed with revision of the polyethylene lock). In all, 55 patients (55 of 101 [55%]) required a total of 141 further surgical procedures: 78 (78 of 141 [55%]) for infection and 42 (42 of 141 [30%]) for mechanical reasons. At review, 90 patients (90 of 101 [89%]) had a MUTARS *in situ*. Above-knee amputations were undertaken in seven patients (seven of 101 [7%]; five as a result of a local recurrence, two resulting from infection), rotationplasty in two (two of 101 [2%]; one as a result of local recurrence, one resulting from infection), total femoral replacement in one (one of 101 [1%], as a result of loosening and poor remnant host bone), and knee disarticulation in one (as a result of a periprosthetic fracture).

## Discussion

Modular endoprostheses are frequently used to reconstruct skeletal and knee defects created by resecting a bone neoplasm from the distal femur or proximal tibia. However, they are associated with substantial complication rates on both the short and long term, most notably infection and aseptic loosening<sup>5, 6, 16</sup>. We sought to evaluate the long-term results of knee arthroplasty with MUTARS modular endoprostheses in the treatment of primary tumors, emphasizing on mechanical complications.

Our study has a number of limitations. Preferably, one would report on proximal tibial and distal femoral replacements separately because they may differ in the types of complications by site. However, we were hampered by a limited number of patients and we therefore chose to report on knee arthroplasty as one group. We grouped patients who had a previous reconstruction together with those reconstructions done for a primary resection and these groups are disparate, which might have influenced our overall risk of loosening. However, we feel that the results as now presented best describe our clinical experiences with this implant system during the period under study. Moreover, as a result of the long retrospective period of our study, we were unable to obtain functional outcome scores and quality of life scores. We had no comparison groups so we are unable to determine if this endoprosthesis offers advantages or disadvantages compared with other prostheses or types of reconstruction.

All complications of soft tissue and instability (Henderson type 1) were managed without implant removal. Few studies specified the incidence of complications of soft tissue and instability; however, our results (6%) are comparable with those recently reported by others (7%–9%)<sup>8,25</sup>. Pala *et al*<sup>8</sup> noted that type 1 complications were more frequent in primary than in revision reconstructions (10% versus 4%). Although with the numbers we had we could not demonstrate an association between having a previous reconstruction or an extra-articular resection, it is plausible that soft tissue problems occur more often in previously operated sites and after more extensive resections as a result of scarring and restricted flexibility of surrounding soft tissues. The most common type 1 complication in a large study on KMFTR and HMRS knee replacements (Stryker, Newbury, UK) was patellar tendon rupture with an overall incidence of 5%<sup>14</sup>. We did not observe any patellar tendon ruptures. We attribute this to the use of the attachment tube. The tube allows for ingrowth of the extensor apparatus and apparently ensures reliable, long-lasting fixation<sup>26</sup>.

Aseptic loosening (Henderson type 2) occurred in 12% of the primary reconstructions. This is comparable with most long-term follow-up studies (table 3). The high risk of loosening of megaprotheses around the knee has been ascribed to many factors, including the torque acting on the stems and the long lever arm associated with greater resection length<sup>25,27</sup>. We could not demonstrate an influence of resection length in the current series. HA coating appeared to decrease the risk of loosening of uncemented distal femoral replacements. Pala *et al* reported a comparable rate (6%) for uncemented HA-coated GMRS prostheses (Stryker, Rutherford, NJ, USA), although their follow-up was substantially shorter (table 3). Satisfactory rates of loosening (0%–8%) have also been reported for cemented custom-made implants with HA collars (Stanmore Implants Worldwide, Elstree, UK)<sup>5,6,28</sup>. Although loosening may occur as late as 25 years after cemented fixation<sup>5,6,16</sup>, it is unlikely to occur after bony ingrowth of a HA-coated implant has taken place<sup>29</sup>. A prerequisite for ingrowth is primary stability; relative motion of more than 150  $\mu\text{m}$  between bone and stem is critical for adequate fixation<sup>30</sup>. Blunn *et al*<sup>29</sup> reported on a series of uncemented tumor implants (Stanmore Implants Worldwide) and noted that subperiosteal cortical bone loss occurred at the mid-stem level. This process, however, stabilized, and none of their implants was revised as a result. We did not observe this as a reason for revision.

Like most modern tumor prostheses, the implants used in our study had a rotating hinge (table 3). Authors postulated that rotating hinges reduce the risk

of bushing wear and of loosening, the latter by reducing torsional stresses at the implant-bone interface<sup>5,7,8</sup>. Myers *et al*<sup>6</sup> reported a reduction in loosening rates after the introduction of rotating hinges, although it is unclear whether this reduction should be ascribed to the rotating hinge, the HA-coated collar, or a combination of both<sup>6</sup>. We are of the opinion that uncemented HA-coated implants with a rotating hinge offer the best possibility to achieve stable fixation and therefore durable results, although we cannot definitively support this contention from our results. Loosening appeared to be a particular problem in those implants that were used as a revision of a previously failed reconstruction. Foo *et al*<sup>31</sup> discussed the difficulties encountered with the use of uncemented MUTARS prostheses after failed allograft reconstructions. We concur with their conclusion that cemented fixation is preferred in case of poor remnant bone quality as may be the case after allograft reconstruction or loosened endoprotheses.

Structural complications (Henderson type 3) occurred in 15%. Introduction of the PEEK-OPTIMA lock has not resulted in a reduction of long-term structural complication rates. Since 2010, we routinely use the MUTARS metal-on-metal locking mechanism because we believe this mechanism should be able to better withstand the high mechanical stresses. Our prosthetic fracture rate (3%) is comparable with the rate reported by Myers *et al* (2%)<sup>6</sup> and compares favorably with other studies (5% – 7%)<sup>11, 12, 32</sup>, whereas our follow-up is among the longest reported in the literature (table 3). All three fractured implants had a total resection length of  $\geq 15.5$  cm and two had 12-mm stems. Previously, Gosheger *et al*<sup>7</sup> reported stem fractures in four MUTARS reconstructions, all with a stem diameter of 12 mm or less. We believe that careful reaming and implantation of the largest possible stem diameter are advisable to reduce the risk of stem fractures and recommend using stems of at least 12 mm.

Infection (Henderson type 4) occurred in 13% and resulted in removal of the implant in 9%, which is comparable with most previous studies (6% – 20%)<sup>5, 6, 8, 11, 12, 14</sup>. We could not demonstrate a difference among early and late infections with regard to the possibility of implant retention. However, three late infections occurred after operative intervention for another complication; such infections may be treated as an acute infection as opposed to late-occurring low-grade infections. Currently, we routinely use silver-coated implants, which may reduce the risk of infection and increase the likelihood of being able to retain the implant in case it gets infected<sup>7, 27</sup>. Others previously reported a reduction in the frequency of infection since the routine use of muscle flaps<sup>5</sup>.

Failure as a result of local recurrence (type 5 complication) occurred in 7%. Other long-term follow-up studies reported comparable rates (5%–6%)<sup>5, 6, 12, 33</sup>. Kinkel *et al*<sup>13</sup> noted that the rate of extra-articular resection was substantially higher in their population (40%) compared with other series (0% – 13%; table 3). With the numbers we had, we found no difference in relapse or complication risks between intra- and extra-articular resections. On the other hand, others reported that extra-articular resection is associated with an increased risk of infection and loosening<sup>7, 18</sup>. One may therefore question whether the high rate of extra-articular resection (46% of the primary reconstructions in our study) is truly justified. Careful evaluation of joint involvement with use of modern imaging techniques (PET-CT, gadolinium-enhanced MRI) may aid to avoid unnecessary extra-articular resections.

As a result of the fact that nearly all studies have used Kaplan-Meier survival analyses to compute implant survival rates, and because different classifications and definitions of failures have been used, it is difficult to adequately compare implant failure rates. Nevertheless, our long-term cumulative incidence rates of failure appear to be comparable to those reported by others<sup>8, 25, 32</sup> and compare favorably with others<sup>5, 6, 11, 13</sup> (table 3).

Despite needing more operative procedures for complications, we were able to achieve limb salvage in 90% of our patients. The majority of our patients had a MUTARS (but not necessarily the original MUTARS implant) *in situ* at latest follow-up, indicating that most complications could be adequately managed.

Although no system has yet proved ideal to restore normal function and demonstrate long-term retention of the implant, MUTARS modular endoprostheses represent a reliable long-term option for knee replacement after tumor resection, which seems to be comparable to other modular implants available to surgeons. The cumulative incidence of implant failure was 20.7% at 10 years with mechanical failure as the endpoint. Aseptic loosening was the most important mechanical complication. HA coating of uncemented implants may reduce the risk of loosening, and we currently use uncemented HA-coated implants believing that it is optimal for durable fixation. We conclude that MUTARS represents a reliable system with long-term results comparable to other prostheses and types of reconstructions for tumor resections about the knee.

*Note: we thank Prof A.H.M. Taminiau, emeritus professor at the Department of Orthopaedic Surgery of the Leiden University Medical Center, for operating on a substantial number of the patients included in this study.*

**Table 3.** Overview of literature on knee replacement in bone tumor surgery.

Study	Number	Year of surgery	Implant type*	Follow-up (years)	Site (%)	Diagnoses (%)	Hinge type (%)	Fixation method (%)	Extra-articular resection (%)	Aseptic loosening	Implant survival / cumulative incidence of failure
Pala	247	2003-2010	GMRS (Stryker)	4 (2-8)	DF 76; PT 25	Prim. 98 Mets. 2	RH	Unc-HA coated 90; cem 9	-	6%	70 and 58% at 4 and 8 years (survival, all failure modes)
Myers	335	1973-2000	Custom (Stanmore)	Survivors: 12 (5-30) Deceased: N/R	DF	Prim. 94 Mets. 6	FH 48 RH 52	Unc-HA collar 4; cem-HA collar 43; cem 53	Rarely	FH: 35% at 10 years; RH: -	83%, 67%, and 51% at 5, 10, and 15 years, respectively (survival, as a result of aseptic loosening, fracture of the implant, infection, breakage, etc)
Myers	194	1977-2002	Custom (Stanmore)	Survivors: 14.7 (5-29) Deceased: N/R	PT	Prim. 94 Mets. 6%	FH 49 RH 51	Cem/ Cem-HA collar (N/R)	Rarely	FH: 46% at 10 years; RH 3%	79%, 58%, and 45% at 5, 10, and 15 years, respectively (survival, as a result of aseptic loosening, breakage, infection, etc)
Kinkel	77	1995-2005	MUTARS (implantcast)	3.8 (0.3-10.7)	DF 64; PT 36	Prim. 90 Mets. 10	RH	Unc 78; cem 22	40	17	57% at 5 years (survival, reasons N/R)
Griffin	99	1989-2000	KMFTR (Stryker)	Med. 6.1 (0.3-13.2)	DF 75; PT 25	Prim.	FH	Unc	13	2	N/R for overall population
Biau	91	1972-1994	Custom (Stryker)	Med. 5.2 (0.0-28.6)	DF 62; PT 38	Prim. 98 Mets. 2	FH	Cem	3	20	76%, 45%, and 29% at 5, 10, and 15 years, respectively (survival, revision for any reason)
Bickels	110	1990-1998	Modular 66%, custom 25%* (Howmedica)	Med. 7.8 (2-16.5)	DF	Prim. 98 Non-tum. 2	FH 7 RH 93	Cem	2	5	93% and 88% at 5 and 10 years, respectively, overall survival
Morgan	105	1985-2004	Modular (different manufacturers)	Med. 4.8 (0.1-19.6)	DF 72; PT 28	N/R	RH	Cem	-	17	73% and 59% at 5 and 10 years, respectively (survival, failure modes 1-4)

Plotz	60	1976-1996	Custom (different manufacturers)	4.9 (0.1-19.1)	DF 75; PT 25	Prim. 83 Mets. 17	N/R	Hybrid 5; unc-Pc 45; Cem 50	N/R	5	34% and 25% at 5 and 10 years, respectively (survival of the prostheses without revision surgery)
Ruggieri	669	1983-2006	KMFTR/HMRS (Stryker)	1.1 (2-25)	DF 71; PT 24; TF 3; EAK 1	Prim. 97 Mets. 3	FH	Unc 91; cem 9	1	6	80% and 55% at 10 and 20 years, respectively (survival, breakage, aseptic loosening, or infection)
Coathup	61	1992-2001	Custom (Stanmore)	8.5 (2-18)	DF	Prim.	RH	Cem-HA collar	N/R	8	75%, 84%, and 89% at 5, 10, and 15 years, respectively (survival, all failure modes)
Batta	69	1994-2006	Custom (Stanmore)	10.4 (0.3-17.7)	DF	Prim.	RH	Unc-HA collar	N/R	13	73%, 65%, and 55% at 5, 10, and 15 years, respectively (survival, all failure modes)
Schwartz	186	1980-2008	Custom 54%, GMRS 46% (different manufacturers)	8.0 (0.1-28.0)	DF	Prim. 98 Mets. 2	RH	Cem/ Cem-Pc collar (N/R)	N/R	12	77% at 10 years (survival, revision of stemmed components for all failure modes)
Current study	110	1995-2010	MUTARS (implantcast)	Overall: 7.2 (0.4-18.0) Survivors: 9.5 (5.0-18.0) Deceased: 3.1 (0.4-14.1)	DF 81; PT 19	Prim.	RH	Unc- uncoated 41; unc-HA coated 49; cem 10	46**	Primary rec. 12; overall 15	Cumulative incidence of failure for mechanical reasons (Types 1-3): 17%, 21%, and 38% at 5, 10, and 15 years. Further details can be found in results section.

\* Implant type: GMRS = Global Modular Replacement System (Stryker, Rutherford, NJ, USA); Custom = custom-made, different manufacturers; MUTARS = Modular Universal Tumor and Revision System (Implantcast, Buxtehude, Germany); KMFTR = Kotz Modular Femur Tibia Reconstruction (Stryker, Rutherford, NJ, USA); Mod. = modular, different manufacturers; HMRS = Howmedica Modular Reconstruction System (Stryker, Rutherford, NJ, USA). Mean followup, unless otherwise stated (med. = median) with the range in parentheses; DF = distal femur, PT = proximal tibia, TF = total femur, EAK = extraarticular knee; prim. = primary tumor, mets. = metastatic disease, non-tum. = nontumorous; RH = rotating hinge, FH = fixed hinge; unc = uncemented, cem = cemented, Pc = porous-coated; \*\* of the patients in whom the MUTARS was implanted during primary surgery, N/R = not reported.

## References

1. Muscolo DL, Ayerza MA, Farfalli G, Aponte-Tinao LA. Proximal tibia osteoarticular allografts in tumor limb salvage surgery. *Clinical orthopaedics and related research*. 2010 May;468(5):1396-404. Epub 2009/12/19.
2. Toy PC, White JR, Scarborough MT, Enneking WF, Gibbs CP. Distal femoral osteoarticular allografts: long-term survival, but frequent complications. *Clinical orthopaedics and related research*. 2010 Nov;468(11):2914-23. Epub 2010/07/21.
3. Donati D, Colangeli M, Colangeli S, Di Bella C, Mercuri M. Allograft-prosthetic composite in the proximal tibia after bone tumor resection. *Clinical orthopaedics and related research*. 2008 Feb;466(2):459-65. Epub 2008/01/16.
4. Mo S, Ding ZQ, Kang LQ, Zhai WL, Liu H. Modified technique using allograft-prosthetic composite in the distal femur after bone tumor resection. *The Journal of surgical research*. 2013 Jun 1;182(1):68-74. Epub 2012/09/11.
5. Myers GJ, Abudu AT, Carter SR, Tillman RM, Grimer RJ. The long-term results of endoprosthetic replacement of the proximal tibia for bone tumours. *The Journal of bone and joint surgery British volume*. 2007 Dec;89(12):1632-7. Epub 2007/12/07.
6. Myers GJ, Abudu AT, Carter SR, Tillman RM, Grimer RJ. Endoprosthetic replacement of the distal femur for bone tumours: long-term results. *The Journal of bone and joint surgery British volume*. 2007 Apr;89(4):521-6. Epub 2007/04/28.
7. Goshager G, Gebert C, Ahrens H, Streitbuerger A, Winkelmann W, Harnes J. Endoprosthetic reconstruction in 250 patients with sarcoma. *Clinical orthopaedics and related research*. 2006 Sep;450:164-71. Epub 2006/05/13.
8. Pala E, Trovarelli G, Calabro T, Angelini A, Abati CN, Ruggieri P. Survival of Modern Knee Tumor Megaprotheses: Failures, Functional Results, and a Comparative Statistical Analysis. *Clinical orthopaedics and related research*. 2014 May 30. Epub 2014/05/31.
9. Bus MP, Dijkstra PD, van de Sande MA, Taminiau AH, Schreuder HW, Jutte PC, et al. Intercalary allograft reconstructions following resection of primary bone tumors: a nationwide multicenter study. *The Journal of bone and joint surgery American volume*. 2014 Feb 19;96(4):e26. Epub 2014/02/21.
10. Chandrasekar CR, Grimer RJ, Carter SR, Tillman RM, Abudu A, Buckley L. Modular endoprosthetic replacement for tumours of the proximal femur. *The Journal of bone and joint surgery British volume*. 2009 Jan;91(1):108-12. Epub 2008/12/19.
11. Biau D, Faure F, Katsahian S, Jeanrot C, Tomeno B, Anract P. Survival of total knee replacement with a megaprosthesis after bone tumor resection. *The Journal of bone and joint surgery American volume*. 2006 Jun;88(6):1285-93. Epub 2006/06/08.
12. Griffin AM, Parsons JA, Davis AM, Bell RS, Wunder JS. Uncemented tumor endoprostheses at the knee: root causes of failure. *Clinical orthopaedics and related research*. 2005 Sep;438:71-9. Epub 2005/09/01.
13. Kinkel S, Lehner B, Kleinhans JA, Jakubowitz E, Ewerbeck V, Heisel C. Medium to long-term results after reconstruction of bone defects at the knee with tumor endoprostheses. *Journal of surgical oncology*. 2010 Feb 1;101(2):166-9. Epub 2009/11/20.
14. Ruggieri P, Mavrogenis AF, Pala E, Abdel-Mota'al M, Mercuri M. Long term results of fixed-hinge megaprotheses in limb salvage for malignancy. *The Knee*. 2012 Oct;19(5):543-9. Epub 2011/09/14.
15. Henderson ER, Groundland JS, Pala E, Dennis JA, Wooten R, Cheong D, et al. Failure mode classification for tumor endoprostheses: retrospective review of five institutions and a literature review. *The Journal of bone and joint surgery American volume*. 2011 Mar 2;93(5):418-29. Epub 2011/03/04.
16. Jeys LM, Kulkarni A, Grimer RJ, Carter SR, Tillman RM, Abudu A. Endoprosthetic reconstruction for the treatment of musculoskeletal tumors of the appendicular skeleton and pelvis. *The Journal of bone and joint surgery American volume*. 2008 Jun;90(6):1265-71. Epub 2008/06/04.
17. Gebert C, Wessling M, Gotze C, Goshager G, Harnes J. The Modular Universal Tumour And Revision System (MUTARS®) in endoprosthetic revision surgery. *International orthopaedics*. 2010 Dec;34(8):1261-5. Epub 2010/04/10.
18. Harnes J, Henrichs MP, Goshager G, Gebert C, Holl S, Dieckmann R, et al. Endoprosthetic replacement after extra-articular resection of bone and soft-tissue tumours around the knee. *The bone & joint journal*. 2013 Oct;95-b(10):1425-31. Epub 2013/10/01.



19. Bus MP, Bramer JA, Schaap GR, Schreuder HW, Jutte PC, van der Geest IC, et al. Hemicortical resection and inlay allograft reconstruction for primary bone tumors: a retrospective evaluation in the Netherlands and review of the literature. *The Journal of bone and joint surgery American volume*. 2015 May 6;97(9):738-50.
20. Henderson ER, O'Connor MI, Ruggieri P, Windhager R, Funovics PT, Gibbons CL, et al. Classification of failure of limb salvage after reconstructive surgery for bone tumours : a modified system Including biological and expandable reconstructions. *The bone & joint journal*. 2014 Nov;96-b(11):1436-40. Epub 2014/11/06.
21. Keurentjes JC, Fiocco M, Schreurs BW, Pijls BG, Nouta KA, Nelissen RG. Revision surgery is overestimated in hip replacement. *Bone & joint research*. 2012 Oct;1(10):258-62. Epub 2013/04/24.
22. Putter H, Fiocco M, Geskus RB. Tutorial in biostatistics: competing risks and multi-state models. *Statistics in medicine*. 2007 May 20;26(11):2389-430. Epub 2006/10/13.
23. de Wreede LC, Fiocco M, Putter H. The mstate package for estimation and prediction in non- and semi-parametric multi-state and competing risks models. *Computer methods and programs in biomedicine*. 2010 Sep;99(3):261-74. Epub 2010/03/17.
24. Team RC. R: A Language and Environment for Statistical Computing. 2008.
25. Batta V, Coathup MJ, Parratt MT, Pollock RC, Aston WJ, Cannon SR, et al. Uncemented, custom-made, hydroxyapatite-coated collared distal femoral endoprotheses: up to 18 years' follow-up. *The bone & joint journal*. 2014 Feb;96-B(2):263-9. Epub 2014/02/05.
26. Gosheger G, Hillmann A, Lindner N, Rodl R, Hoffmann C, Burger H, et al. Soft tissue reconstruction of megaprotheses using a trevira tube. *Clinical orthopaedics and related research*. 2001 Dec(393):264-71. Epub 2002/01/05.
27. Wafa H, Grimer RJ, Reddy K, Jeys L, Abudu A, Carter SR, et al. Retrospective evaluation of the incidence of early periprosthetic infection with silver-treated endoprotheses in high-risk patients: case-control study. *The bone & joint journal*. 2015 Feb;97-B(2):252-7. Epub 2015/01/30.
28. Coathup MJ, Batta V, Pollock RC, Aston WJ, Cannon SR, Skinner JA, et al. Long-term survival of cemented distal femoral endoprotheses with a hydroxyapatite-coated collar: a histological study and a radiographic follow-up. *The Journal of bone and joint surgery American volume*. 2013 Sep 4;95(17):1569-75. Epub 2013/09/06.
29. Blunn GW, Briggs TW, Cannon SR, Walker PS, Unwin PS, Culligan S, et al. Cementless fixation for primary segmental bone tumor endoprotheses. *Clinical orthopaedics and related research*. 2000 Mar(372):223-30. Epub 2000/03/30.
30. Kinkel S, Graage JD, Kretzer JP, Jakubowitz E, Nadorf J. Influence of stem design on the primary stability of megaprotheses of the proximal femur. *International orthopaedics*. 2013 Oct;37(10):1877-83. Epub 2013/08/21.
31. Foo LS, Harges J, Henrichs M, Ahrens H, Gosheger G, Streitburger A. Surgical difficulties encountered with use of modular endoprosthesis for limb preserving salvage of failed allograft reconstruction after malignant tumor resection. *The Journal of arthroplasty*. 2011 Aug;26(5):744-50. Epub 2010/08/10.
32. Morgan HD, Cizik AM, Leopold SS, Hawkins DS, Conrad EU, 3rd. Survival of tumor megaprotheses replacements about the knee. *Clinical orthopaedics and related research*. 2006 Sep;450:39-45. Epub 2006/08/15.
33. Bickels J, Wittig JC, Kollender Y, Henshaw RM, Kellar-Graney KL, Meller I, et al. Distal femur resection with endoprosthetic reconstruction: a long-term followup study. *Clinical orthopaedics and related research*. 2002 Jul(400):225-35. Epub 2002/06/20.





# Chapter 10

## **General Summary**

## General Summary

Reconstructions for tumor resections in the pelvis and appendicular skeleton are among the most challenging procedures in modern orthopaedics. This thesis aimed to evaluate the outcomes of various reconstructive techniques, and to identify risk factors for complications or impaired outcome following reconstruction. Part I focused on the management of pelvic bone tumors; it discussed the management and outcome of conventional primary central chondrosarcoma of the pelvis, and two techniques for periacetabular reconstruction. Part II focused on different types of allograft reconstructions, as well as reconstructions with modular endoprostheses.

### Part I – Management of Pelvic Bone Tumors

Chondrosarcoma is the most common pelvic bone tumor in adults, and poses specific challenges to orthopaedic surgeons because of the lack of effective adjuvant treatment modalities and the high rates of local relapse. **Chapter 2** contained a retrospective evaluation of 162 patients who were treated for a conventional primary central chondrosarcoma of the pelvis in five European centers of musculoskeletal oncology. Thirty-eight percent of our patients experienced a local recurrence, 30% had metastases. Tumor grade, resection margins and maximal tumor size were found to be independent factors of influence on disease-specific survival. Deep infection (19%) was the predominant complication, and the risk of infection was higher for patients with an endoprosthetic reconstruction. Our study included the largest series to date focusing on patients with a conventional primary central chondrosarcoma of pelvic bone. Because of the inability to reliably distinguish low- and high-grade tumors preoperatively, we concluded that any central pelvic chondrosarcoma should be treated with aggressive primary resection with the aim of obtaining wide resection margins.

Periacetabular tumor resections and their subsequent reconstruction are among the most challenging procedures in orthopaedic oncology. In **chapter 3**, we retrospectively evaluated the mid- to long-term clinical outcome of periacetabular reconstruction with the pedestal cup endoprosthesis. Between 2003 and 2009, a total of 19 patients underwent reconstruction with this implant in the two contributing centers. Complications occurred in 15 patients. Three (16%) had recurrent dislocations and three experienced aseptic loosening. There were

no mechanical failures of the implant itself. Infection occurred in nine patients (47%), six of whom required removal of the prosthesis. The implant survival rate at five years was 50% for all reasons, and 61% for non-oncological reasons. The mean MSTS score at final follow-up was 49% (13 to 87). We concluded that we no longer used this implant and advised caution if using it for reconstruction after periacetabular tumor resection.

Despite the poor results obtained with periacetabular reconstruction using the pedestal cup endoprosthesis, we considered the basic idea behind the implant suitable for pelvic reconstruction. Our experiences were incorporated in the design of the LUMiC. **Chapter 4** reflects on a retrospective European multicenter evaluation of clinical outcome in 47 patients who underwent reconstruction with the LUMiC after resection of a periacetabular tumor. The aim was to evaluate the short- to mid-term results of this novel implant. We demonstrated that the risk of dislocation was significantly lower in reconstructions with a dual-mobility cup than in those without (HR 0.11, i.e. an 89% reduction in dislocation risk in favor of the dual mobility cup). Loosening occurred in two uncemented reconstructions with poor initial fixation; both were revised. Infections occurred in 28%. We showed that the duration of surgery and amount of blood loss were associated with the risk of infection. The cumulative incidences of implant failure at 2 and 5 years were 2.1% and 17.3% for mechanical reasons and 6.4% and 9.2% for infection, respectively. Mean MSTS functional outcome score at follow-up was 70% (30 to 93). We concluded that, at short-term follow-up, the LUMiC prosthesis demonstrated a low frequency of mechanical complications and failure when used to reconstruct the acetabulum in patients who underwent major pelvic tumor resections. Moreover, we stated that dual-mobility articulation should be used after any internal hemipelvectomy to reduce the risk of dislocation.

## Part II – Management of Extremity Bone Tumors

Intercalary allografts have long been the most important reconstructive option for the reconstruction of large segmental (diaphyseal) defects. **Chapter 5** described a retrospective evaluation of all intercalary allograft reconstructions in the treatment of primary bone tumors in all four centers of orthopaedic oncology in the Netherlands between 1989 and 2009. The incidence of and risk factors for failure and complications, time to full weight bearing, and optimal fixation methods were evaluated in a total of 87 reconstructions. Complications occurred

in 76% of patients. The major complications were nonunion (40%), fracture (29%), and infection (14%). The median time to full weight bearing was nine months. Fifteen grafts failed, twelve of which failed in the first four years. None of the tibial reconstructions failed. Reconstruction site, patient age, allograft length, nail-only fixation, and non-bridging osteosynthesis were the most important risk factors for complications. To reduce the number of failures, we recommended to reconsider the use of allografts for reconstructions of large defects, especially in older patients, and to apply bridging osteosynthesis with use of plate fixation.

It has been hypothesized that primary bone tumors can be adequately treated with hemicortical resection. Potential advantages of hemicortical resection include the preservation of joints, bone stock and cortical continuity. In **chapter 6**, we evaluated all hemicortical resections and subsequent inlay allograft reconstructions for primary bone tumors in a nationwide retrospective study. A total of 111 patients were evaluated for mechanical complications, infection, oncological outcome, and allograft survival. Thirty-three percent had non-oncological complications, with host bone fracture being the most common (18%). Other complications included nonunion (7%), infection (7%), and allograft fracture (3%). Of ninety-seven patients with a malignant tumor, 15% had a residual or recurrent tumor and 6% had metastasis. The risk of complications and fractures increased with the extent of cortical resection. We concluded that hemicortical resection is not recommended for high-grade lesions; however, it may be superior to segmental resection for treatment of carefully selected tumors, provided that it is possible to obtain adequate margins.

Osteoarticular allografts were commonly used to reconstruct articular defects following tumor resection in the Leiden University Medical Center after the Leiden Bone Bank was founded in December 1988. However, solid evidence on the long-term outcome of osteoarticular allograft reconstructions was lacking. In **chapter 7**, we presented a systematic review of the literature on osteoarticular allograft reconstructions in musculoskeletal tumor surgery, and evaluated our single-center experiences with this reconstructive technique. We included 31 studies in our systematic review. A total of 514 segmental reconstructions were analyzed. With distal femoral reconstructions as the reference, we demonstrated that reconstruction failure was less common in reconstructions of the distal radius (OR 0.3). Fractures were more common in the proximal humerus (OR 4.1) and

proximal tibia (OR 2.2). Infections occurred more often in the proximal tibia (OR 2.2) and less often in the distal radius (OR 0.1). In our retrospective study, we included 38 patients. With allograft-related failure as the end-point, graft survival rates at two, five and ten years were 91%, 54% and 42%. We concluded that osteoarticular allograft reconstruction of major joints is associated with an unacceptably high rate of complications, and cautioned others against the routine employment of segmental osteoarticular allografts for reconstructions around the knee or shoulder.

In the studies on allograft reconstructions, nonunion has been identified as one of the major complications and failure mechanisms. In **chapter 8**, we present an evaluation on risk factors for nonunion of allograft-host junctions in intercalary allograft reconstructions of the femur and tibia, and assessed the influence of cortical contact. To that end, we assessed the degree of contact in 96 transverse osteotomies that were fixed using plates, on two orthogonal views. We introduced a novel classification system, in which we classified the degree of cortical contact into grades 1 (full contact over the entire length of the osteotomy), 2A ( $\geq 50\%$  contact), 2B ( $< 50\%$  contact), and 3 (lack of cortical contact). We found that nonunion did not occur in grade 1 osteotomies. The risk of nonunion was 7% for grade 2A, 18% for grade 2B, and 50% for grade 3 junctions. Reconstruction site, patient age  $> 16$  years, localization within the bone or chemotherapy use did not significantly influence nonunion risk. We concluded that, although future, larger studies will have to confirm our findings, care should be taken to obtain rigid fixation with firm contact at the junction site to minimize or even eliminate the risk of allograft-host nonunion.

Modular endoprostheses have largely replaced allografts as the method of choice for reconstruction of joints after tumor resection. In **chapter 9**, we reported the long-term results of knee replacement with MUTARS modular endoprostheses from two centers. A total of 110 consecutive reconstructions in 101 patients were evaluated with a minimum follow-up of five years. Eighty-nine reconstructions (81%) were distal femoral replacements (78 uncemented, 87%; 42 of which hydroxyapatite-coated, 54%), 21 (19%) were reconstructions of the proximal tibia. In 26 reconstructions (24%), surgery was preceded by a failed previous reconstruction. Complications of soft-tissue or instability occurred in 6%. Loosening occurred in 28% of the implants used for revision of a failed reconstruction and

in 12% of the primary reconstructions (HR 1.87). Uncemented HA-coated distal femoral replacements had a five-fold lower risk of loosening than uncemented uncoated distal femoral replacements (HR 0.21). Structural complications occurred in 15 reconstructions (14%), infections in 14 (13%). With failure for mechanical reasons as the endpoint, the cumulative incidences of implant failure at 5, 10, and 15 years were 16.9%, 20.7%, and 37.9%, respectively. We concluded that MUTARS modular endoprostheses represent a reliable long-term option for knee replacement after tumor resection, and recommended the use of uncemented hydroxyapatite-coated implants.







# Chapter 11

## **General Discussion**

## General Discussion

During recent decades, limb-salvage surgery has replaced amputation as the treatment of choice for musculoskeletal tumors of the appendicular skeleton and pelvis<sup>1,2</sup>. This transition is largely attributable to the advent of effective adjuvant treatment and concomitant sophistication of imaging and surgical techniques<sup>1,3,4</sup>. Simultaneously, five-year survival rates increased from less than 20% before the 1970s, to approximately 55 to 70% nowadays<sup>1,4-8</sup>. The preponderance of limb salvage surgery and increased patient survival resulted in an increased demand for durable reconstructions with favorable and predictable clinical results and functional outcome.

In this thesis, we evaluated the clinical outcomes of various reconstructive techniques in musculoskeletal tumor surgery. This thesis aimed to assess clinical outcome in terms of complications and reconstruction survival rates, and to identify risk factors for complications and impaired survival. Therewith, we ultimately aim to improve outcomes for patients with bone tumors. Part I of the thesis focused on management of pelvic bone tumors, part II focused on reconstructions of the appendicular skeleton.

In 2011, Henderson *et al* proposed a failure mode classification for tumor endoprostheses, with the aim to facilitate understanding of endoprosthetic failures and to stimulate uniform reporting<sup>9</sup>. They classified five different modes of failure: soft-tissue failure (type 1), aseptic loosening (type 2), structural failure (type 3), infection (type 4) and tumor progression (type 5). Throughout the majority of the studies in this thesis, we have used this system to classify failures. In addition, we have attempted to classify complications that did not result in reconstruction failure. Therewith, we aimed to stimulate more uniform reporting on clinical results, in order to gain further insight in the outcomes of these complex reconstructions. Below, we will systematically discuss current concepts, complications and surgical strategies in management of pelvic (part I) and extremity (part II) bone tumors. Additionally, we will propose a number of modifications to the Henderson classification system, with the aim to further improve registration and comparability of complication and failure rates.

### Part I - Management of Pelvic Bone Tumors

Tumors of innominate bone are some of the most challenging conditions to treat for orthopaedic oncologists<sup>10-12</sup>. Pelvic tumors may present with vague

abdominal complaints and, because they are located deep in the body, are often large at the time of diagnosis<sup>13</sup>. As a result, they are difficult to access surgically and often demonstrate close proximity to major neurovascular, urinary, and intestinal and reproductive organ structures. Therefore, it can be challenging to obtain an adequate resection margin<sup>14</sup>. Nevertheless, limb-salvaging internal hemipelvectomies are nowadays the standard of care for patients with a pelvic bone tumor, if a clear margin can be achieved<sup>2</sup>.

Internal hemipelvectomy gained favor over hindquarter amputation because of obvious cosmetic, psychological and functional advantages<sup>2, 15, 16</sup>. According to Enneking's classification of pelvic resections<sup>12</sup>, a type 1 or type 3 internal hemipelvectomy (i.e., isolated resection of the ilium or pubis) does not compromise the anatomic weight-bearing axis and therefore, these resections generally do not necessitate reconstruction<sup>17, 18</sup>. However, if the periacetabular bone has to be resected (type 2 internal hemipelvectomy) and femorosacral continuity is disrupted, a particular reconstructive challenge arises<sup>19</sup>.

After a type 2 internal hemipelvectomy, one strategy is to leave the defect alone, producing a flail hip ("super Girdlestone")<sup>20, 21</sup>. This however results in instability of the iliofemoral joint and severe shortening of the affected side. Others prefer to perform an iliofemoral arthrodesis or pseudarthrosis, either to obtain solid fusion or as primary pseudarthrosis<sup>19, 22</sup>. These procedures may provide moderate but durable long-term functional results<sup>22</sup>. On the other hand, failure to obtain fusion occurs in up to 50% of primary pseudarthroses, potentially resulting in a painful reconstruction with poor function<sup>19</sup>. Another alternative is transposition of the hip, a procedure which serves to produce a neo-joint at the level of iliac resection rather than reconstruct the weight-bearing axis or acetabulum<sup>23</sup>. Although transposition of the hip generally results in reasonable and predictable functional outcome<sup>21, 23, 24</sup>, it may cause significant shortening of the affected limb<sup>10</sup>. This may be corrected during a secondary lengthening procedure; however, these operations are associated with a significant risk of major complications, especially in inexperienced hands<sup>25</sup>.

Other techniques aim to restore the native situation as much as possible. Allografts, either as a structural pelvic allograft or as part of an allograft-prosthetic composite reconstruction, have been commonly used<sup>15, 26-30</sup>. Acceptable long-term results have been reported<sup>29, 30</sup>, although many surgeons prefer to avoid the use of allografts because they are considered to be associated with high rates of infection and mechanical complications, including graft fracture, nonunion of allograft-host



junctions, and allograft resorption on the long term<sup>28, 31</sup>. Furthermore, structural allograft reconstructions are technically demanding as it is often difficult to obtain an adequate fit between the allograft and host bone<sup>32, 33</sup>. In addition, in some countries, widespread use of allografts might be restricted by limited availability and concerns about transmission of infectious diseases<sup>33</sup>.

Endoprosthetic devices, on the other hand, allow for relatively easy, quick and durable reconstruction<sup>10</sup>. The first endoprosthesis that was commonly used for reconstruction of pelvic tumor defects was the saddle prosthesis<sup>17, 34, 35</sup>. This implant requires the surgeon to create a notch in the remnant iliac wing, to match the curved shape of the saddle prosthesis<sup>36</sup>. The saddle prosthesis lacks modularity and may require additional resection of the iliac wing to be implanted<sup>37, 38</sup>.

Various authors consider stemmed implants the state of the art for periacetabular reconstruction<sup>39-41</sup>. Others prefer to use custom-made or hemipelvic prostheses<sup>42-44</sup>. Although comparative studies between stemmed and hemipelvic implants are lacking, hemipelvic implants have a number of inherent disadvantages. Most importantly, they lack the possibility of intraoperative adjustment. This may cause problems when greater resection is needed than was anticipated preoperatively<sup>45</sup>. In addition, custom-made implants may cause delay in treatment and are costly to manufacture<sup>46, 47</sup>.

Although recent developments have greatly increased the possibilities and clinical outcome after treatment for pelvic bone sarcoma, these large reconstructions are still fraught with complications.

### ***1.1 Soft-tissue failure and instability***

Resections of pelvic bone tumors often require extensive surgical approaches, and frequently leave large dead spaces and poorly vascularized soft-tissue flaps, resulting in a substantial risk of wound dehiscence and deep infection<sup>14, 48-50</sup>. The true incidence of wound dehiscence is however uncertain because many authors fail to mention superficial wound problems<sup>21, 39, 51</sup>. Apart from the risk of wound problems and deep infection, the extensive soft tissue resections also lead to poor muscular support around the neo-joint, and thus contribute to the high risk of prosthetic dislocation, especially for saddle prostheses<sup>34, 38, 50</sup>. In our retrospective study on periacetabular reconstruction with the (monobloc) pedestal cup endoprosthesis, we found that 16% of patients had experienced recurrent dislocations during follow-up<sup>10</sup>.

A number of factors should be considered. During pelvic resection, patients are positioned in the lateral decubitus position, allowing them to be rotated to nearly prone or supine positions. As a result, during reconstruction, it can be hard for the surgeon to adequately assess how the implant should be inserted. It was hypothesized that modularity of the implant would resolve part of these difficulties, because it would allow for adjustment of acetabular cup orientation – even after the stem has been implanted. With the LUMiC prosthesis, modularity was introduced in the field of pelvic reconstruction. In our study on the short-term clinical results of LUMiC endoprosthetic reconstructions, we found that recurrent dislocations occurred in four out of 47 patients (9%), one of whom had a first dislocation after resection of an extensive recurrence<sup>40</sup>. Although results are difficult to compare because of inherent heterogeneity in terms of the extent of resection and surgical approach, modularity in our experience made it easier to adequately position the cup. Cup position has been reported as an important factor for prosthetic dislocation risk, functional outcome and polyethylene wear in studies on total hip arthroplasty<sup>52, 53</sup>.

Additional factors may help to further improve cup positioning in pelvic tumor reconstructions. First, computer-assisted surgical techniques can be used for adequate intraoperative visualization of prosthetic orientation. Second, modification of prosthetic design may allow for further intraoperative adjustment: although the acetabular cup can be rotated with reference to the stem, the acetabular cup-stem angle is fixed in the LUMiC. The exact influence of acetabular cup positioning on outcome of pelvic reconstructions should be determined in future studies.

In an attempt to further reduce the risk of dislocation, the possibility of dual-mobility articulation was introduced for the LUMiC prosthesis. Previously, it was reported that dual-mobility cups can be effective in treatment of recurrent instability in total hip replacements or instability encountered during hip revision arthroplasty<sup>54</sup>. Interposition of a mobile polyethylene component increases the effective head diameter and allows greater movement of the femoral head before subluxating or dislocating<sup>55, 56</sup>. Indeed, we found that the risk of dislocation was significantly lower in reconstructions with a dual-mobility cup, as compared with conventional acetabular cups. We are of the opinion that any internal hemipelvectomy for a primary tumor should be reconstructed with a dual-mobility cup to reduce the risk of dislocation.



## 1.2 Aseptic loosening

Aseptic loosening is one of the major modes of failure for endoprosthetic reconstructions in orthopaedic oncology, especially for reconstructions around the knee<sup>57, 58</sup>. The high risk of loosening for knee replacements has been ascribed to several factors, including the torque acting on the stem-bone interfaces<sup>59, 60</sup>. As opposed to knee replacements, reconstructions of polyaxial joints allow for a certain degree of movement between prosthetic parts and therefore, less torque acts on these stem-bone interfaces. Irrespective of the limited torque acting on pelvic implants, we found that three of 19 patients (16%) had aseptic loosening of their uncemented porous-coated pedestal cup endoprosthesis<sup>10</sup>. Although the reported incidence of loosening is closely correlated with duration of follow-up, and results are therefore difficult to compare, previous authors reported comparable rates of loosening for saddle (12%) and hemipelvic prostheses (16%)<sup>17, 61</sup>. Factors that contribute to the risk of loosening of pelvic implants include the high mechanical stresses as a result of great resection length and extensive soft tissue dissection. Moreover, because of the flat morphology of the ilium, there is limited initial contact between the implant and cortical bone.

In keeping with results reported for reconstructions of the appendicular skeleton, it was hypothesized that hydroxyapatite (HA) coating of the iliac stem would stimulate bony ingrowth and thus reduce the risk of loosening<sup>62</sup>. In our study on reconstructions with the LUMiC prosthesis, we found that two patients with uncemented HA-coated iliac stem (2/45, 4%) experienced loosening. Further analysis showed that both patients had inadequate primary fixation of the stem (one due to an intraoperative fracture, one due to fixation in a previous structural allograft), while primary stability is a prerequisite for ingrowth of HA-coated implants<sup>63</sup>. An alternative modern pelvic implant, the “ice-cream cone prosthesis” (Stanmore Implants Worldwide, United Kingdom), relies on a combination of HA-coating and bone cement for stem fixation<sup>39</sup>. Cement may be useful to obtain adequate primary stability and thus allow for bony ingrowth in the HA-coating. On the other hand, cement fragmentation and foreign body reaction to wear debris may result in late periprosthetic osteolysis and loosening<sup>64</sup>. Excellent results have been reported for tumor implants with hybrid fixation, although the number of patients included and follow-up were limited in the studies on pelvic reconstructions<sup>39, 65-68</sup>.

Other advantages of cementing are that it allows for immediate weight-bearing, especially in case of extensive bony destruction, and the possibility to add



local antibiotics. Therefore, cemented implants may be preferable for patients with radiotherapy or those at high risk of developing postoperative deep infection<sup>39</sup>. We prefer uncemented fixation with HA-coated stems for patients with a reasonable prognosis and sufficient bone quality, mainly because these implants are at a lower risk of loosening once bony ongrowth has taken place<sup>58, 69</sup>.

### 1.3 Structural failure

Structural failure is common for pelvic allograft reconstruction, either due to primary fracture or due to graft resorption<sup>15, 70</sup>. Saddle prostheses also frequently fail due to structural complications, including prosthetic dissociation and fractures of the remnant ilium<sup>38</sup>. With modern endoprosthetic production quality and design, implant fractures are rare; no structural implant failures were reported in recent studies on the pedestal cup, LUMiC and ice-cream cone endoprostheses<sup>10, 39, 40</sup>. Periprosthetic iliac fractures, however, still occur. Two types of iliac fractures should be distinguished. First, intraoperative crack fractures, which cause minimal displacement and generally heal without major interventions<sup>10, 40</sup>. Obvious risk factors for intraoperative fractures include the use of uncemented press-fit iliac stems, poor bone quality, and revision procedures; in these cases, extra caution is warranted<sup>71</sup>. And second, postoperative fractures of the iliac wing. The saddle prosthesis has been associated with a substantial risk of fracture of the remnant iliac wing, in addition to the risk of cranial migration of the saddle component (up to 7%)<sup>17, 22, 34, 72, 73</sup>. A possible explanation for these structural failures lies in the fact that the saddle prosthesis anchors laterally from the natural femorosacral weight-bearing axis, where the anteroposterior dimension of the ilium is limited and the iliac cortices are thin; therefore, adequate supportive bone stock is lacking<sup>17, 34, 35, 38, 74, 75</sup>. Consequently, more cranial migration has been reported when larger resection of the iliac wing is required<sup>17, 35</sup>. Cranial migration of the implant in turn causes limb length discrepancy and recurrent dislocations, compromising function of the affected side<sup>34</sup>. Moreover, the eccentric position of the artificial hip center allows only limited range of motion<sup>76</sup>. Several more modern implants, including the Mark II saddle (Link, Hamburg, Germany) and the PAR prosthesis (Stryker Howmedica, NJ, USA), still have these unfavorable features<sup>37, 72</sup>.

Conversely, so-called “stemmed acetabular” or “inverted ice-cream cone” prostheses anchor in the medial ilium, adjacent to the sacroiliac joint<sup>10, 39, 40</sup>. There, a thick bar of bone extends from the sacroiliac joint down to the acetabulum, along the natural weight-bearing axis. This allows the implant to be seated well



between the anterior and posterior cortices<sup>10,74,77</sup>. In a number of these stemmed implants, the stem is tapered, which causes the implant to anchor itself as a result of axial loading along the weight-bearing axis<sup>10,40</sup>. Theoretically, this type of fixation should not only reduce the risk of iliac fractures and cranial migration, but also of aseptic loosening<sup>40</sup>.

It is for these reasons that additively manufactured (3D-printed) pelvic prostheses, in our opinion, should be met with caution. Although these hemipelvic implants are superior for restoring iliac crest anatomy, they typically lack adequate fixation in the weight-bearing axis. Mechanical complications, including loosening, cranial migration and component breakage, can therefore be expected; in that regard, custom hemipelvic implants are much like hemipelvic allografts.

### **1.4 Infection**

Pelvic tumor resections are notorious for the high risk of postoperative infection (18-32%), irrespective of the reconstructive technique used<sup>14, 23, 50, 75, 78, 79</sup>. Deep infections can be devastating, necessitating multiple surgical debridements, removal of implants or even – although rarely – hindquarter amputation<sup>14</sup>. The high risk of infection can be attributed to the length and complexity of the surgical procedure, creating a large dead space and leaving large soft tissue defects, and the immunocompromised status of patients, due to co-treatment with chemotherapy<sup>38, 80-82</sup>. A validated deep infection risk score for endoprosthetic reconstructions is currently lacking, and should be developed in future research to allow surgeons to better identify patients at risk for developing surgical site infection. Given the influence of operative time on the risk of infection, we feel that further centralization of care for patients with pelvic bone tumors should be considered.

Numerous precautions have been taken in an attempt to reduce the rate of infection, including the administration of prophylactic antibiotics – which are given for a duration of up to five days postoperatively<sup>82</sup>. To date, solid evidence to support the use of a specific antibiotic protocol is lacking. Currently, there is an international randomized controlled study (the PARITY trial) ongoing to determine the optimal antibiotic regimen (one or five days) following endoprosthetic reconstruction for bone tumor resection<sup>83</sup>.

Other strategies to reduce the risk of deep infection focus on implant surface modifications to minimize adhesion of bacteria, inhibit the formation of a biofilm, and provide bactericidal action<sup>84</sup>. In recent years, silver coating of endoprostheses

has been one of the most discussed techniques<sup>85-87</sup>. Silver coating of various medical materials, such as cardiac and urinary catheters, previously proved to reduce the risk of infection<sup>85</sup>. Studies demonstrated that silver coating of MUTARS endoprostheses (implantcast, Buxtehude, Germany) effectively reduced the risk of infection in a rabbit model, and that the use of silver coating is free of side-effects<sup>85,86</sup>. Furthermore, two retrospective clinical studies showed that silver coating may increase the likelihood of successful revision surgery in case of endoprosthetic infection, and of being able to retain an implant in case it gets infected<sup>87,88</sup>. It should be noted, however, that the number of patients included in these studies were limited, while other studies were not able to detect a significant difference<sup>40,58</sup>. Furthermore, comparative studies between coated and uncoated implants are lacking and thus, there is currently no solid evidence to support the idea that silver coating reduces the risk of infection of primary endoprosthetic reconstructions for bone tumors. One may therefore question whether coated implants should be used routinely. A cost-benefit analysis will have to be conducted to answer this question.

More recently, researchers from Japan reported excellent results for iodine coating of titanium endoprostheses for preventing and treating periprosthetic infection<sup>89,90</sup>. Future studies are needed to assess the beneficial effect and potential complications of the use of different coatings in endoprosthetic reconstructions<sup>84</sup>. This should include analysis of a potential effect on implant fixation. Meanwhile, patients with coated implants should be followed on a regular basis and surgeons should be alert for side effects, such as clinical evidence of argyria in patients with silver coated implants<sup>84</sup>.

The use of myocutaneous flaps, to cover implants with well-vascularized soft tissue and to eliminate dead space, also gained attention during recent years. Some centers use a rectus abdominis myocutaneous flap as a standard of treatment for patients with a pelvic reconstruction<sup>68,91</sup>. These techniques however necessitate large contralateral dissection, usually take long and often require extensive blood transfusion<sup>91</sup>. Regardless of the use of such extensive flaps, the risk of wound problems remained high in a study on pelvic reconstructions<sup>68</sup>. In addition, the use of extensive flaps undermines the integrity of the abdominal wall and has a risk of herniation<sup>92</sup>. Therefore, we are of the opinion that surgeons should be hesitant to perform a myocutaneous flap rotation during the primary procedure in treatment of pelvic tumors. Omentoplasty is an alternative technique that may be used to cover pelvic reconstructions, although there are currently no studies to



support the idea that this reduces the risk of deep infection. It has, however, been shown that omentoplasty can be used to successfully fill a large cavity and cover an infected structure (bronchopleural fistula)<sup>93</sup>.

Filling the dead space with large amounts of antibiotic-loaded bone cement is another technique to reduce the risk of deep infection<sup>39</sup>. On the other hand, the exothermic reaction of polymethylmethacrylate (PMMA) bone cement may cause further damage to surrounding soft tissues<sup>94</sup>. Furthermore, multi-resistant microorganisms may evolve. Alternatives for delivering large amounts of antibiotics locally include Garacol® (EUSA Pharma, Hemel Hempstead, United Kingdom) and Septopal® (Zimmer Biomet, Warsaw, IN, United States), although there is no evidence to support the use of these agents in large tumor defects. Future research should be directed at developing and evaluating the efficacy of bactericidal materials that can be used to fill the dead space after tumor resection.

## Part II: Management of Extremity Bone Tumors

Primary bone tumors of the appendicular skeleton most commonly affect the epimetaphyseal regions of the distal femur, proximal tibia, proximal humerus and proximal femur<sup>95,96</sup>. Many studies therefore focused on reconstructions of the knee, hip, and shoulder. Three techniques can be used to reconstruct a functional joint following articular tumor resection: transplantation of an osteoarticular allograft, implantation of an endoprosthesis, or a combination of the two (allograft-prosthetic composite, APC)<sup>97-100</sup>. Although these techniques have greatly improved possibilities and functional outcomes for sarcoma patients, joint replacements for bone tumors are still associated with relatively high complication and revision rates<sup>57</sup>. Intercalary reconstructions salvage the native joint, lack moving components, are easier to perform, and are generally associated with a lower risk of late mechanical failure<sup>33, 101</sup>. Therefore, we prefer these joint-sparing resections whenever oncologically safe. In an attempt to further improve mechanical results of intercalary reconstructions, our center pioneered with hemicortical resection of tumors with limited cortical and intramedullary involvement<sup>102</sup>.

Below, complications and failure modes of different biological and endoprosthetic techniques will be discussed, based on the Henderson classification<sup>9</sup>. Furthermore, comments will be made on controversies in surgical strategies for reconstructions after lower-extremity bone tumor resection.

## 2.1 *Soft-tissue failure*

Two types of soft-tissue failures can be distinguished: either related to function ("limited function owing to insufficient musculo-ligamentous attachment"), or related to coverage (aseptic wound dehiscence). Few studies explicitly mentioned soft tissue problems as a cause of failure for reconstructions of the extremities, presumably because most soft-tissue complications ultimately either result in infection, or can be managed with a skin graft or myocutaneous flap.

Adequate soft-tissues are of essential importance for optimal functioning of reconstructions of polyaxial joints; a lack of support results in subluxation or recurrent dislocation<sup>103</sup>. It is, however, difficult to assess the influence of the extent of soft tissue resection on functional outcome of intercalary reconstructions or knee replacements. On the other hand, we know that muscular support reduces the loads on the adjacent joint<sup>104</sup>, and extensive soft tissue resection therefore may result in an increased risk of mechanical failure<sup>105</sup>. The TLEMsafe project, which is currently ongoing, aims to combine a computerized model of the musculoskeletal system and innovative imaging techniques to predict functional effects of a specific resection<sup>106</sup>. Although this model is not able to account for compensatory function of salvaged muscles and it may be questioned whether such a prediction would actually affect clinical practice, it would be interesting to use such models to calculate mechanical stresses on implants, to predict mechanical failure and, ultimately, to manufacture implants that are optimized to withstand the relevant mechanical stresses.

Loss of extensor mechanism function is a particular concern after tumor resections around the knee<sup>105</sup>. Osteoarticular allografts have a theoretical advantage over endoprostheses because they offer the possibility to reconstruct the extensor mechanism and may thus result in a less severe extension lag<sup>107, 108</sup>. On the other hand, synthetic materials may be used to reconstruct the extensor mechanism when using an endoprosthesis. Early synthetic (Terylene) ligaments were abrasive to local tissues and eventually ruptured<sup>109</sup>. Modern synthetic materials, such as the MUTARS trevira tube<sup>58</sup> and LARS tube<sup>110</sup> (LARS, Arc-Sur-Tille, France), however demonstrated satisfactory results in the first clinical studies<sup>58, 110, 111</sup>. Future studies will have to show whether there is a difference in outcomes between biological and modern synthetic materials for reconstructions of the extensor mechanism.



## ***2.2 Aseptic loosening and graft-host nonunion***

As discussed in paragraph 1.2, endoprostheses around the knee were notorious for the risk of aseptic loosening. With the introduction of hydroxyapatite (HA) coating for uncemented implants and HA collars for cemented implants, the risk of failure due to aseptic loosening decreased from 25-40% to approximately 5% at 10 years follow-up for primary implants<sup>58, 65, 66</sup>. The risk of loosening has been ascribed to a number of factors, including the torque acting on the stems<sup>59, 60</sup>. Endoprostheses of the knee originally had a fixed hinge without rotational freedom, which resulted in excessive stress transfer at the implant-bone or cement-bone interface<sup>112</sup>. Modern hinges allow for a certain degree of axial rotation, thereby theoretically reducing mechanical stress at the interface and thus lowering the risk of loosening. Clinical studies that compared outcomes of fixed and rotating hinges concluded that rotating hinges appeared to reduce the risk of loosening<sup>65, 66</sup>, although results may have been biased by concomitant modifications in endoprosthetic design (including the introduction of HA coating and collars) and increasing surgical experience.

Whereas the incidence of type 2 failure of endoprostheses has greatly been reduced during recent decades, graft-host nonunion is still among the main complications for allograft reconstructions. Even though the risk of reconstruction failure is limited (5-7%), up to 40% of patients require operative intervention to facilitate union<sup>33, 113</sup>. We demonstrated that plate fixation and cortical contact at the junction are important prognostic factors in union of allograft-host junctions. Although the number of patients included in our study on allograft-host junctions was limited, we found that all junctions with plate fixation and radiographic cortical continuity on the first postoperative radiograph united without further surgical intervention. These results shine new light on the dilemma whether to use an allograft or a vascularized fibular graft (VFG) for reconstruction of intercalary defects.

The superior biological potential of VFGs is one of the reasons why some surgeons prefer to use a VFG<sup>114</sup>. However, if the risk of nonunion of allograft-host junctions can be eliminated, there presumably is no advantage of using a VFG over an allograft for defects with a length of less than eight to 10 centimeters. A virtual bone bank system and computer-assisted surgery may prove useful to obtain superior fit between host bone and the allograft<sup>115, 116</sup>. For larger defects, VFGs may be preferable because of the increased risk of complications in large allograft reconstructions<sup>113</sup>. Reconstruction length was not associated with complication

rates in one study on VFGs<sup>114</sup>. Nevertheless, initial stability is an important concern in VFG reconstructions, especially when reconstructing large defects in heavy adults. VFGs however have the potential of hypertrophic growth; although patients will have to accept a long period of partial weight-bearing, gradual increase in weight-bearing may result in a durable construct of living bone. Interposition of a joint-sparing implant is another promising technique for reconstruction of intercalary long-bone defects, and allows for early weight-bearing<sup>117</sup>. Modern additive manufacturing techniques may be used to produce patient-specific joint-sparing implants with optimal three-dimensional fit. Future comparative studies are needed to definitively determine what is the best technique for reconstruction of (large) intercalary defects.

### 2.3 Structural failure

For endoprostheses, structural complications can be divided into (1) implant breakage or wear, and (2) periprosthetic osseous fractures. Breakage of stems is rare, occurring in approximately 2% of knee endoprostheses<sup>57, 118</sup>. Obvious risk factors for stem fractures include greater resection length and the use of small-diameter stems<sup>58, 118</sup>. Failure of the polyethylene and PEEK-OPTIMA (Invia Ltd, Thornton-Cleveleys, United Kingdom) locking mechanisms has been a particular concern for the MUTARS system<sup>119</sup>. With the introduction of a metal-on-metal locking mechanism, the risk of structural failure has been eradicated. In vitro studies and close follow-up of patients are indicated to assess the amount of wear debris released, the risk of adverse reactions, and thus the long-term safety of these locking mechanisms.

Periprosthetic fractures can be divided into intraoperative crack fractures without displacement and 'true' (or late) periprosthetic fractures. The occurrence of intraoperative crack fractures is associated with the use of uncemented press-fit stems<sup>120</sup>. As they generally require little or no further surgical treatment and mostly heal uneventfully<sup>58, 121</sup>, we do not consider this a contraindication for the use of uncemented stems. Management of late periprosthetic fractures, on the other hand, is problematic, but their incidence is low<sup>69</sup>. These fractures are presumably associated with periprosthetic osteolysis (bone resorption) and aseptic loosening of implants<sup>122</sup>. The occurrence of resorption has been ascribed to stress shielding; if osseointegration of the stem occurs over a longer trajectory, stresses in the outer cortex are reduced, and resorption may occur<sup>69</sup>. To reduce the low-stress region in the outer cortex, Blunn *et al* suggested that the region of HA-coating should



be reduced to one-third of the stem length. MUTARS stems are coated for more than one third. Although resorption of the outer cortex is often evident following uncemented fixation, particularly in the zone nearest to the reconstructed joint, we did not observe this as a reason for implant failure in our long-term follow-up study<sup>58</sup>. This supports our idea that this process stabilizes over time, and therefore, the clinical relevance of the phenomenon remains unclear.

For biological reconstructions, structural complications can be divided into (1) osteosynthesis material breakage leading to construct instability, and (2) fractures through the graft. The most common cause of osteosynthesis material breakage is metal fatigue. The occurrence of fatigue fractures is likely associated with diastasis at the osteotomy junction and delayed or nonunion; repetitive mechanical stresses on the osteosynthesis materials will eventually lead to failure. Fractures are a serious complication of segmental allograft reconstructions, occurring in 16-29% of patients<sup>33, 101, 113, 123</sup>. Its treatment is problematic because the fracture site is generally composed of non-vascular bone tissue. Several techniques have been described for treatment of allograft fractures, including the addition of a vascularized fibular graft or new allograft at the fracture site, or the application of recombinant bone morphogenetic protein-2<sup>124-126</sup>. The chance of successful healing is limited and most surgeons therefore prefer to revise the entire allograft. Vascularized grafts offer an obvious advantage over allografts in this regard.

## **2.4 Infection**

Strategies to reduce the risk of infection after endoprosthetic reconstruction are discussed in paragraph 1.4; most of these also apply to reconstructions in the appendicular skeleton. The overall rate of deep infection after endoprosthetic or allograft reconstruction for extremity bone tumors is approximately 10%<sup>82, 127</sup>. Reconstructions of the proximal tibia are associated with a higher rate of infection (up to 36% in early series on endoprostheses)<sup>109</sup>. Some surgeons started to routinely perform a gastrocnemius muscle flap rotation, and reported that the risk of infection had reduced to 12% by doing so<sup>109</sup>. Later studies demonstrated that the effect was less profound than was initially believed<sup>65</sup>. Moreover, dissection of the medial gastrocnemius muscle may impair functional outcome. We therefore prefer to perform a gastrocnemius muscle flap only in high-risk cases, when soft-tissue coverage is poor. Further follow-up will have to prove if this approach is equally effective.



## General conclusions

During recent decades, there has been a tremendous improvement in treatment possibilities for bone tumors of the pelvis and extremities. Nevertheless, functional outcomes vary greatly between patients, in part owing to the frequent occurrence of complications. We therefore set out to assess complications of various reconstructive techniques and to identify risk factors for those complications, with the ultimate aim to improve outcomes for patients with musculoskeletal tumors.

Treatment of pelvic bone tumors is associated with a high risk of complications, regardless of the reconstructive technique used. The design principle of modern stemmed acetabular implants for reconstruction after periacetabular resections is comparable to those of decades ago. However, due to improvements in production processes and modifications in implant design, including the introduction of modularity, coatings, and dual-mobility articulation, their reliability and durability has improved dramatically. At present, they can be used for the vast majority of pelvic tumor reconstructions and the reconstruction itself has become less technically demanding. The main issues that remain to be solved are the high risk of instability and infection, and it appears that the occurrence of these complications is closely tied to the extent of surgery. Future research should be directed at prevention and adequate treatment of these complications.

Fortunately, complications are less frequent in treatment of extremity bone tumors. During the early years of limb-salvage surgery, allografts were the preferred method of reconstruction in many large European sarcoma centers. As with any surgical procedure, the outcome is dependent on the right indication. It however appears that this especially holds true for allografts: they offer a reliable, durable and elegant option when they are being used for meticulous reconstruction of defects of limited size in younger patients. On the other hand, when they are being used for reconstruction of extensive osseous defects in older patients with poor healing potential and their fitting is suboptimal, the risk of complications is extremely high and the reconstruction is likely to fail. During the last few decades, endoprostheses have largely replaced allografts as the technique of choice for reconstruction of extremity bone tumor defects. Again, improvements in production and design of these implants have caused an enormous increase in reliability and long-term stability. The challenge for the orthopaedic oncologist is to choose the right technique for the specific patient and tumor type. Apart from introducing new techniques, it is extremely important to be aware of risk factors for complications of existing techniques. In the end, the outcome of any



surgical procedure is dependent on the right indication and a precise technique of execution.

### General considerations

The vast majority of clinical articles in orthopaedic journals are single center observational case series on a surgical technique<sup>128</sup>, leading to a substantial risk of selection bias and heterogeneity. A systematic review demonstrated that 92% of studies published on surgical management of lower extremity bone tumors are level IV or V studies<sup>129</sup>. The overall quality of reporting is generally poor, and studies are therefore prone to confounding bias, sampling bias and recall bias<sup>129</sup>. Furthermore, studies on surgical techniques often report single-center results from a highly specialized center – commonly one that was involved in the development of the technique – and thus may overestimate clinical outcome. Reasons for the lack of higher level of evidence studies include the rareness of diseases, heterogeneity in presentation and surgical approaches, loss of follow-up due to patient mortality, and ethical considerations. International cooperation is key to obtaining sufficient patient numbers, although differences in expertise, treatment protocols and surgeon preferences may introduce other types of bias. In that regard, it is essential that uniform definitions are employed and that standard reporting guidelines, such as the STROBE statement, are applied as much as possible<sup>130</sup>.

The classification of failure modes as described by Henderson *et al* was one of the first widely supported classification systems that aimed to stimulate uniform reporting<sup>9</sup>. Although the authors must be applauded for their initiative, there are a number of flaws in the classification. First, the system only classifies failures, not complications. As a result, isolated revision of the bushing is counted as a failure – while many authors consider this routine maintenance<sup>57, 58</sup>. On the other hand, servicing procedures result in secondary deep infection in approximately 5% of cases<sup>58</sup> and we therefore encourage striving for an implant system that is free of the need of maintenance. Second, to distinguish early from late infections, the Henderson classification system uses a cutoff point of two years for endoprostheses, and six months for biological reconstructions. Rather than the time from primary surgery to the onset of symptoms, a classification system should distinguish infections with an acute onset from delayed or chronic infections; this dictates the treatment strategy and the probability of being able to retain the implant<sup>40, 131</sup>. Third, the Henderson classification did not include massive bone resorption

around endoprostheses, nor resorption of grafts, while this is an important issue in larger biological reconstructions<sup>98, 127</sup>. Fourth, the classification system did not distinguish breakage of implants from breakage of supportive hardware (i.e., a supportive screw), while the clinical implications of the two are materially different. We present a modified version of the Henderson classification (tables 1 and 2), aiming to further improve reporting of complications and failures and comparability of different surgical strategies and reconstructive techniques. Future collaborative studies are indicated to optimize the classification system based on factors that are relevant for clinical outcome.

Careful evaluation of functional outcome, not just complications and failures, should be included in future studies to offer further insight in clinical outcome of various reconstructive techniques. Currently, two systems are widely accepted for assessment of functional outcome. The MSTS (MusculoSkeletal Tumor Society) score was developed in the 1980s and is currently the most commonly used<sup>132</sup>. The system is a physician-reported outcome that assigns numerical values (0-5) for six domains, producing an overall numerical score that can be used to calculate a percentage rating. The TESS (Toronto Extremity Salvage Score), on the other hand, is a patient-reported questionnaire that was developed in the 1990s<sup>133</sup>. The TESS questionnaire assigns numerical values (1-5) for 30 activities of daily living. Although the questionnaires demonstrate reasonable agreement, the subjective satisfaction and acceptance of physical impairment are generally higher than the objective score<sup>134</sup>. In addition, we are of the opinion that the scoring systems offer little discriminative value. Data of large cohort studies should be used to develop a novel, easy-to-use system for assessment of functional outcome. A recent study concluded that the vast majority of functional improvement can be expected during the first two years after surgery, suggesting that long-term follow-up studies are not necessarily needed to assess functional outcome<sup>135</sup>.

Apart from evaluating functional outcomes, we are of the opinion that innovative surgical techniques should be introduced in a regulated manner, ensuring the safety and effectiveness of novel techniques. The IDEAL consortium proposed a five-stage model that was based on the phased approach for drug development<sup>136</sup>. It should be taken into account, however, that well-regulated introduction of novel treatment strategies and implants in orthopaedic oncology is complicated. Because of the rarity of disease, combined with the heterogeneity in localizations, disease extent, use of co-treatments, and patient characteristics, it is extremely difficult to adequately compare the outcomes of different techniques.



To some extent, however, roentgen stereophotogrammetric analysis (RSA) may be used to compare implants<sup>137</sup>. This technique is able to accurately measure three-dimensional implant migration (up to 0.1mm for translations and 0.1 degree for rotations). RSA has been shown to have early predictive properties for implant failure, and may be used in the process of adequate phased introduction of new implants<sup>137</sup>.

Although there have been tremendous improvements over the years, challenges remain in effective treatment of musculoskeletal tumors and in optimization of reconstructive techniques. Again, (inter-)national collaborative studies are needed, aiming for a golden era of cancer therapy, when, in the words of Gordon-Taylor, "gross mechanical destruction of disease and cruel mutilation of tissue shall be no more"<sup>138</sup>.

**Table 1.** Classification of complications for endoprosthetic reconstructions in orthopaedic oncology.

Category	Type	Subtype	Description	Time of diagnosis <sup>1</sup>	No. of patients affected <sup>2</sup>	No. of patients needing a re-intervention	No. of implants removed as a result
Mechanical	Type 1: Soft tissue	1A. Functional	Instability or dislocations (including dislocations treated with closed or open reduction)				
		1B. Coverage	Superficial wound problems, including aseptic wound dehiscence and superficial necrosis				
	Type 2: Aseptic loosening	N/A	Radiographic or clinical signs of loosening in the absence of infection				
	Type 3: Structural failure	3A. Periprosthetic fracture	Fracture of periprosthetic bone				
		3B. Structural hardware breakage	Breakage of stem or locking mechanism				
Non-mechanical		3C. Supporting hardware breakage or wear	Breakage of liner or screw				
		3D. Wear	Wear of liner or insert				
		3E. Bone resorption	Massive periprosthetic bone resorption				
		4A. Acute	<6 weeks after implantation				
		4B. Late or chronic	>6 weeks after implantation				
	Type 4: Infection <sup>3</sup>	4C. Secondary acute	<6 weeks after secondary procedure				
		5. Local tumor relapse	Recurrence or progression of tumor				
	Type 5: Tumor progression						

<sup>1</sup> Report the median time (and range) from surgery to diagnosis of the complication, in months. Does not apply for type 3D (wear of liner or insert) and 3E (bone resorption) complications

<sup>2</sup> Report the total number of patients who were affected by the complication, also those who did not need surgical re-intervention

<sup>3</sup> All deep infections, including those treated with implant retention



**Table 2.** Classification of complications for biological reconstructions (allograft, autograft) in orthopaedic oncology

Category	Type	Subtype	Description	Time of diagnosis <sup>1</sup>	No. of patients affected <sup>2</sup>	No. of patients needing a re-intervention	No. of grafts removed as a result
Mechanical	Type 1: Soft tissue	1A. Functional	Instability or dislocations (including dislocations treated with closed or open reduction)				
		1B. Coverage	Superficial wound problems, including aseptic wound dehiscence and superficial necrosis				
	Type 2: Nonunion	2A. Hypertrophic	Hypertrophic nonunion of the allograft-host junction, defined as the lack of continuity in three cortices at the junction one year after surgery				
		2B. Atrophic	Atrophic nonunion of the allograft-host junction, defined as the lack of continuity in three cortices at the junction one year after surgery				
	Type 3: Structural failure	3A. Fracture	Fracture of graft or fracture through graft-host junction				
Non-mechanical	Type 4: Infection <sup>3</sup>	3B. Hardware breakage	Breakage of osteosynthesis material				
		3C. Graft collapse or massive resorption	Collapse of the graft, of massive resorption of the graft				
		4A. Acute	<6 weeks after implantation				
		4B. Late or chronic	>6 weeks after implantation				
		4C. Secondary acute	<6 weeks after secondary procedure				
	Type 5: Tumor progression	5. Local tumor relapse	Recurrence or progression of tumor				

<sup>1</sup> Report the median time (and range) from surgery to diagnosis of the complication, in months. Does not apply for a type 2 complication (nonunion)

<sup>2</sup> Report the total number of patients who were affected by the complication, also those who did not need surgical re-intervention

<sup>3</sup> All deep infections, including those treated with graft retention

## References

1. Enneking WF. An abbreviated history of orthopaedic oncology in North America. *Clinical orthopaedics and related research*. 2000 May(374):115-24. Epub 2000/05/20.
2. Grimer RJ, Chandrasekar CR, Carter SR, Abudu A, Tillman RM, Jeys L. Hindquarter amputation: is it still needed and what are the outcomes? *The bone & joint journal*. 2013 Jan;95-b(1):127-31. Epub 2013/01/12.
3. Link MP, Goorin AM, Miser AW, Green AA, Pratt CB, Belasco JB, et al. The effect of adjuvant chemotherapy on relapse-free survival in patients with osteosarcoma of the extremity. *The New England journal of medicine*. 1986 Jun 19;314(25):1600-6. Epub 1986/06/19.
4. Nesbit ME, Jr, Gehan EA, Burgert EO, Jr, Vietti TJ, Cangir A, Tefft M, et al. Multimodal therapy for the management of primary, nonmetastatic Ewing's sarcoma of bone: a long-term follow-up of the First Intergroup study. *Journal of clinical oncology : official journal of the American Society of Clinical Oncology*. 1990 Oct;8(10):1664-74. Epub 1990/10/01.
5. Bielack SS, Kempf-Bielack B, Delling G, Exner GU, Flege S, Helmke K, et al. Prognostic factors in high-grade osteosarcoma of the extremities or trunk: an analysis of 1,702 patients treated on neoadjuvant cooperative osteosarcoma study group protocols. *Journal of clinical oncology : official journal of the American Society of Clinical Oncology*. 2002 Feb 1;20(3):776-90. Epub 2002/02/01.
6. Bernstein M, Kovar H, Paulussen M, Randall RL, Schuck A, Teot LA, et al. Ewing's sarcoma family of tumors: current management. *The oncologist*. 2006 May;11(5):503-19. Epub 2006/05/25.
7. Rosen G. Preoperative (neoadjuvant) chemotherapy for osteogenic sarcoma: a ten year experience. *Orthopedics*. 1985 May;8(5):659-64. Epub 1985/05/01.
8. Bacci G, Picci P, Pignatti G, De Cristofaro R, Dallari D, Avella M, et al. Neoadjuvant chemotherapy for nonmetastatic osteosarcoma of the extremities. *Clinical orthopaedics and related research*. 1991 Sep(270):87-98. Epub 1991/09/01.
9. Henderson ER, Groundland JS, Pala E, Dennis JA, Wooten R, Cheong D, et al. Failure mode classification for tumor endoprostheses: retrospective review of five institutions and a literature review. *The Journal of bone and joint surgery American volume*. 2011 Mar 2;93(5):418-29. Epub 2011/03/04.
10. Bus MP, Boerhout EJ, Bramer JA, Dijkstra PD. Clinical outcome of pedestal cup endoprosthetic reconstruction after resection of a peri-acetabular tumour. *The bone & joint journal*. 2014 Dec;96-b(12):1706-12. Epub 2014/12/03.
11. Ozaki T, Hillmann A, Lindner N, Blasius S, Winkelmann W. Chondrosarcoma of the pelvis. *Clinical orthopaedics and related research*. 1997 Apr(337):226-39. Epub 1997/04/01.
12. Enneking WF, Dunham WK. Resection and reconstruction for primary neoplasms involving the innominate bone. *The Journal of bone and joint surgery American volume*. 1978 Sep;60(6):731-46. Epub 1978/09/01.
13. Bloem JL, Reidsma II. Bone and soft tissue tumors of hip and pelvis. *Eur J Radiol*. 2012 Dec;81(12):3793-801.
14. Angelini A, Drago G, Trovarelli G, Calabro T, Ruggieri P. Infection after surgical resection for pelvic bone tumors: an analysis of 270 patients from one institution. *Clinical orthopaedics and related research*. 2014 Jan;472(1):349-59. Epub 2013/08/27.
15. Harrington KD. The use of hemipelvic allografts or autoclaved grafts for reconstruction after wide resections of malignant tumors of the pelvis. *The Journal of bone and joint surgery American volume*. 1992 Mar;74(3):331-41. Epub 1992/03/01.
16. Apffelstaedt JP, Driscoll DL, Spellman JE, Velez AF, Gibbs JF, Karakousis CP. Complications and outcome of external hemipelvectomy in the management of pelvic tumors. *Annals of surgical oncology*. 1996 May;3(3):304-9. Epub 1996/05/01.
17. Aboulafia AJ, Buch R, Mathews J, Li W, Malawer MM. Reconstruction using the saddle prosthesis following excision of primary and metastatic periacetabular tumors. *Clinical orthopaedics and related research*. 1995 May(314):203-13. Epub 1995/05/01.
18. Satcher Jr RL, O'Donnell RJ, Johnston JO. Reconstruction of the pelvis after resection of tumors about the acetabulum. *Clinical orthopaedics and related research*. 2003 Apr(409):209-17. Epub 2003/04/03.



19. O'Connor MI, Sim FH. Salvage of the limb in the treatment of malignant pelvic tumors. *The Journal of bone and joint surgery American volume*. 1989 Apr;71(4):481-94. Epub 1989/04/01.
20. Uchida A, Myoui A, Araki N, Yoshikawa H, Ueda T, Aoki Y. Prosthetic reconstruction for periacetabular malignant tumors. *Clinical orthopaedics and related research*. 1996 May(326):238-45. Epub 1996/05/01.
21. Gebert C, Gosheger G, Winkelmann W. Hip transposition as a universal surgical procedure for periacetabular tumors of the pelvis. *Journal of surgical oncology*. 2009 Mar 1;99(3):169-72.
22. Fuchs B, O'Connor MI, Kaufman KR, Padgett DJ, Sim FH. Iliofemoral arthrodesis and pseudarthrosis: a long-term functional outcome evaluation. *Clinical orthopaedics and related research*. 2002 Apr(397):29-35. Epub 2002/04/16.
23. Gebert C, Wessling M, Hoffmann C, Roedl R, Winkelmann W, Gosheger G, et al. Hip transposition as a limb salvage procedure following the resection of periacetabular tumors. *Journal of surgical oncology*. 2011 Mar 1;103(3):269-75. Epub 2011/02/22.
24. Hoffmann C, Gosheger G, Gebert C, Jurgens H, Winkelmann W. Functional results and quality of life after treatment of pelvic sarcomas involving the acetabulum. *The Journal of bone and joint surgery American volume*. 2006 Mar;88(3):575-82. Epub 2006/03/03.
25. Dahl MT, Gulli B, Berg T. Complications of limb lengthening. A learning curve. *Clinical orthopaedics and related research*. 1994 Apr(301):10-8.
26. Delloye C, Banse X, Brichard B, Docquier PL, Cornu O. Pelvic reconstruction with a structural pelvic allograft after resection of a malignant bone tumor. *The Journal of bone and joint surgery American volume*. 2007 Mar;89(3):579-87. Epub 2007/03/03.
27. Beadel GP, McLaughlin CE, Wunder JS, Griffin AM, Ferguson PC, Bell RS. Outcome in two groups of patients with allograft-prosthetic reconstruction of pelvic tumor defects. *Clinical orthopaedics and related research*. 2005 Sep;438:30-5. Epub 2005/09/01.
28. Ozaki T, Hillmann A, Bettin D, Wuisman P, Winkelmann W. High complication rates with pelvic allografts. Experience of 22 sarcoma resections. *Acta orthopaedica Scandinavica*. 1996 Aug;67(4):333-8. Epub 1996/08/01.
29. Langlais F, Lambotte JC, Thomazeau H. Long-term results of hemipelvis reconstruction with allografts. *Clinical orthopaedics and related research*. 2001 Jul(388):178-86. Epub 2001/07/14.
30. Donati D, Di Bella C, Frisoni T, Cevolani L, DeGroot H. Alloprosthetic composite is a suitable reconstruction after periacetabular tumor resection. *Clinical orthopaedics and related research*. 2011 May;469(5):1450-8. Epub 2011/02/12.
31. Capanna R, van Horn JR, Guernelli N, Briccoli A, Ruggieri P, Biagini R, et al. Complications of pelvic resections. *Archives of orthopaedic and trauma surgery*. 1987;106(2):71-7. Epub 1987/01/01.
32. Cartiaux O, Docquier PL, Paul L, Francq BG, Cornu OH, Delloye C, et al. Surgical inaccuracy of tumor resection and reconstruction within the pelvis: an experimental study. *Acta orthopaedica*. 2008 Oct;79(5):695-702. Epub 2008/10/08.
33. Bus MP, Dijkstra PD, van de Sande MA, Taminiau AH, Schreuder HW, Jutte PC, et al. Intercalary allograft reconstructions following resection of primary bone tumors: a nationwide multicenter study. *The Journal of bone and joint surgery American volume*. 2014 Feb 19;96(4):e26. Epub 2014/02/21.
34. Jansen JA, van de Sande MA, Dijkstra PD. Poor long-term clinical results of saddle prosthesis after resection of periacetabular tumors. *Clinical orthopaedics and related research*. 2013 Jan;471(1):324-31. Epub 2012/10/12.
35. Renard AJ, Veth RP, Schreuder HW, Pruszczyński M, Keller A, van Hoesel Q, et al. The saddle prosthesis in pelvic primary and secondary musculoskeletal tumors: functional results at several postoperative intervals. *Archives of orthopaedic and trauma surgery*. 2000;120(3-4):188-94. Epub 2000/03/30.
36. Nieder E, Elson RA, Engelbrecht E, Kasselt MR, Keller A, Steinbrink K. The saddle prosthesis for salvage of the destroyed acetabulum. *The Journal of bone and joint surgery British volume*. 1990 Nov;72(6):1014-22. Epub 1990/11/01.
37. Menendez LR, Ahlmann ER, Falkinstein Y, Allison DC. Periacetabular reconstruction with a new endoprosthesis. *Clinical orthopaedics and related research*. 2009 Nov;467(11):2831-7. Epub 2009/08/21.
38. Aljassir F, Beadel GP, Turcotte RE, Griffin AM, Bell RS, Wunder JS, et al. Outcome after pelvic sarcoma resection reconstructed with saddle prosthesis. *Clinical orthopaedics and related research*. 2005 Sep;438:36-41. Epub 2005/09/01.



39. Fisher NE, Patton JT, Grimer RJ, Porter D, Jeys L, Tillman RM, et al. Ice-cream cone reconstruction of the pelvis: a new type of pelvic replacement: early results. *The Journal of bone and joint surgery British volume*. 2011 May;93(5):684-8. Epub 2011/04/23.
40. Bus MP, Szafranski A, Sellevold S, Goryn T, Jutte PC, Bramer JA, et al. LUMiC® Endoprosthetic Reconstruction After Periacetabular Tumor Resection: Short-term Results. *Clinical orthopaedics and related research*. 2016 Mar 28.
41. Shahid M, Saunders T, Jeys L, Grimer R. The outcome of surgical treatment for peri-acetabular metastases. *The bone & joint journal*. 2014 Jan;96-B(1):132-6.
42. Muller PE, Durr HR, Wegener B, Pellengahr C, Refior HJ, Jansson V. Internal hemipelvectomy and reconstruction with a megaprosthesis. *International orthopaedics*. 2002;26(2):76-9. Epub 2002/06/25.
43. Guo W, Li D, Tang X, Yang Y, Ji T. Reconstruction with modular hemipelvic prostheses for periacetabular tumor. *Clinical orthopaedics and related research*. 2007 Aug;461:180-8. Epub 2007/04/25.
44. Bruns J, Luessenhop SL, Dahmen G, Sr. Internal hemipelvectomy and endoprosthetic pelvic replacement: long-term follow-up results. *Archives of orthopaedic and trauma surgery*. 1997;116(1-2):27-31. Epub 1997/01/01.
45. Menendez LR, Ahlmann ER, Kermani C, Gotha H. Endoprosthetic reconstruction for neoplasms of the proximal femur. *Clinical orthopaedics and related research*. 2006 Sep;450:46-51. Epub 2006/08/15.
46. Chandrasekar CR, Grimer RJ, Carter SR, Tillman RM, Abudu A, Buckley L. Modular endoprosthetic replacement for tumours of the proximal femur. *The Journal of bone and joint surgery British volume*. 2009 Jan;91(1):108-12. Epub 2008/12/19.
47. Ahlmann ER, Menendez LR, Kermani C, Gotha H. Survivorship and clinical outcome of modular endoprosthetic reconstruction for neoplastic disease of the lower limb. *The Journal of bone and joint surgery British volume*. 2006 Jun;88(6):790-5. Epub 2006/05/25.
48. Kulaylat MN, Froix A, Karakousis CP. Blood supply of hemipelvectomy flaps: the anterior flap hemipelvectomy. *Arch Surg*. 2001 Jul;136(7):828-31.
49. Temple WJ, Mnaymneh W, Ketcham AS. The total thigh and rectus abdominis myocutaneous flap for closure of extensive hemipelvectomy defects. *Cancer*. 1982 Dec 1;50(11):2524-8.
50. Jaiswal PK, Aston WJ, Grimer RJ, Abudu A, Carter S, Blunn G, et al. Peri-acetabular resection and endoprosthetic reconstruction for tumours of the acetabulum. *The Journal of bone and joint surgery British volume*. 2008 Sep;90(9):1222-7. Epub 2008/09/02.
51. Abudu A, Grimer RJ, Cannon SR, Carter SR, Sneath RS. Reconstruction of the hemipelvis after the excision of malignant tumours. Complications and functional outcome of prostheses. *The Journal of bone and joint surgery British volume*. 1997 Sep;79(5):773-9. Epub 1997/10/23.
52. Nogler M, Kessler O, Prassl A, Donnelly B, Streicher R, Sledge JB, et al. Reduced variability of acetabular cup positioning with use of an imageless navigation system. *Clinical orthopaedics and related research*. 2004 Sep(426):159-63. Epub 2004/09/04.
53. Durand-Hill M, Henckel J, Satchithananda K, Sabah S, Hua J, Hothi H, et al. Calculating the hip center of rotation using contralateral pelvic anatomy. *Journal of orthopaedic research : official publication of the Orthopaedic Research Society*. 2016 Jun;34(6):1077-83. Epub 2015/12/03.
54. Levine BR, Della Valle CJ, Deirmengian CA, Breien KM, Weeden SH, Sporer SM, et al. The use of a tripolar articulation in revision total hip arthroplasty: a minimum of 24 months' follow-up. *The Journal of arthroplasty*. 2008 Dec;23(8):1182-8. Epub 2008/06/07.
55. Guyen O, Pibarot V, Vaz G, Chevillotte C, Bejui-Hugues J. Use of a dual mobility socket to manage total hip arthroplasty instability. *Clinical orthopaedics and related research*. 2009 Feb;467(2):465-72. Epub 2008/09/10.
56. Guyen O, Chen QS, Bejui-Hugues J, Berry DJ, An KN. Unconstrained tripolar hip implants: effect on hip stability. *Clinical orthopaedics and related research*. 2007 Feb;455:202-8. Epub 2007/02/07.
57. Jeys LM, Kulkarni A, Grimer RJ, Carter SR, Tillman RM, Abudu A. Endoprosthetic reconstruction for the treatment of musculoskeletal tumors of the appendicular skeleton and pelvis. *The Journal of bone and joint surgery American volume*. 2008 Jun;90(6):1265-71. Epub 2008/06/04.
58. Bus MP, van de Sande MA, Fiocco M, Schaap GR, Bramer JA, Dijkstra PD. What Are the Long-term Results of MUTARS® Modular Endoprostheses for Reconstruction of Tumor Resection of the Distal Femur and Proximal Tibia? *Clinical orthopaedics and related research*. 2015 Dec 9.



59. Batta V, Coathup MJ, Parratt MT, Pollock RC, Aston WJ, Cannon SR, et al. Uncemented, custom-made, hydroxyapatite-coated collared distal femoral endoprosthesis: up to 18 years' follow-up. *The bone & joint journal*. 2014 Feb;96-B(2):263-9. Epub 2014/02/05.
60. Unwin PS, Cannon SR, Grimer RJ, Kemp HB, Sneath RS, Walker PS. Aseptic loosening in cemented custom-made prosthetic replacements for bone tumours of the lower limb. *The Journal of bone and joint surgery British volume*. 1996 Jan;78(1):5-13. Epub 1996/01/01.
61. Witte D, Bernd L, Bruns J, Gosheger G, Harges J, Hartwig E, et al. Limb-salvage reconstruction with MUTARS® hemipelvic endoprosthesis: a prospective multicenter study. *European journal of surgical oncology : the journal of the European Society of Surgical Oncology and the British Association of Surgical Oncology*. 2009 Dec;35(12):1318-25. Epub 2009/05/30.
62. Kelly SJ, Incavo SJ, Beynon B. The use of a hydroxyapatite-coated primary stem in revision total hip arthroplasty. *The Journal of arthroplasty*. 2006 Jan;21(1):64-71. Epub 2006/02/01.
63. Kinkel S, Graage JD, Kretzer JP, Jakubowitz E, Nadorf J. Influence of stem design on the primary stability of megaprotheses of the proximal femur. *International orthopaedics*. 2013 Oct;37(10):1877-83. Epub 2013/08/21.
64. van der Voort P, Valstar ER, Kaptein BL, Fiocco M, van der Heide HJ, Nelissen RG. Comparison of femoral component migration between Refobacin bone cement R and Palacos R + G in cemented total hip arthroplasty: A randomised controlled roentgen stereophotogrammetric analysis and clinical study. *The bone & joint journal*. 2016 Oct;98-b(10):1333-41. Epub 2016/10/04.
65. Myers GJ, Abudu AT, Carter SR, Tillman RM, Grimer RJ. The long-term results of endoprosthetic replacement of the proximal tibia for bone tumours. *The Journal of bone and joint surgery British volume*. 2007 Dec;89(12):1632-7. Epub 2007/12/07.
66. Myers GJ, Abudu AT, Carter SR, Tillman RM, Grimer RJ. Endoprosthetic replacement of the distal femur for bone tumours: long-term results. *The Journal of bone and joint surgery British volume*. 2007 Apr;89(4):521-6. Epub 2007/04/28.
67. Grimer RJ, Aydin BK, Wafa H, Carter SR, Jeys L, Abudu A, et al. Very long-term outcomes after endoprosthetic replacement for malignant tumours of bone. *The bone & joint journal*. 2016 Jun;98-B(6):857-64.
68. Barrientos-Ruiz I, Ortiz-Cruz EJ, Peleteiro-Pensado M. Reconstruction After Hemipelvectomy With the Ice-Cream Cone Prosthesis: What Are the Short-term Clinical Results? *Clinical orthopaedics and related research*. 2016 Feb 16. Epub 2016/02/18.
69. Blunn GW, Briggs TW, Cannon SR, Walker PS, Unwin PS, Culligan S, et al. Cementless fixation for primary segmental bone tumor endoprosthesis. *Clinical orthopaedics and related research*. 2000 Mar(372):223-30. Epub 2000/03/30.
70. Regis D, Sandri A, Bonetti I, Bortolami O, Bartolozzi P. A minimum of 10-year follow-up of the Burch-Schneider cage and bulk allografts for the revision of pelvic discontinuity. *The Journal of arthroplasty*. 2012 Jun;27(6):1057-63.e1. Epub 2012/03/09.
71. Davidson D, Pike J, Garbuz D, Duncan CP, Masri BA. Intraoperative periprosthetic fractures during total hip arthroplasty. Evaluation and management. *The Journal of bone and joint surgery American volume*. 2008 Sep;90(9):2000-12. Epub 2008/09/03.
72. Cottias P, Jeanrot C, Vinh TS, Tomeno B, Anract P. Complications and functional evaluation of 17 saddle prostheses for resection of periacetabular tumors. *Journal of surgical oncology*. 2001 Oct;78(2):90-100. Epub 2001/10/02.
73. Kitagawa Y, Ek ET, Choong PF. Pelvic reconstruction using saddle prosthesis following limb salvage operation for periacetabular tumour. *Journal of orthopaedic surgery (Hong Kong)*. 2006 Aug;14(2):155-62. Epub 2006/08/18.
74. Antoniadis J, Pellegrini VD, Jr. Cross-sectional anatomy of the ilium: implications for acetabular component placement in total hip arthroplasty. *Clinical orthopaedics and related research*. 2012 Dec;470(12):3537-41.
75. Mavrogenis AF, Soultanis K, Patapis P, Guerra G, Fabbri N, Ruggieri P, et al. Pelvic resections. *Orthopedics*. 2012 Feb;35(2):e232-43. Epub 2012/02/09.
76. Windhager R, Karner J, Kutschera HP, Polterauer P, Salzer-Kuntschik M, Kotz R. Limb salvage in periacetabular sarcomas: review of 21 consecutive cases. *Clinical orthopaedics and related research*. 1996 Oct(331):265-76. Epub 1996/10/01.

77. Ring PA. Complete replacement arthroplasty of the hip by the ring prosthesis. *The Journal of bone and joint surgery British volume*. 1968 Nov;50(4):720-31. Epub 1968/11/01.
78. Angelini A, Calabro T, Pala E, Trovarelli G, Maraldi M, Ruggieri P. Resection and reconstruction of pelvic bone tumors. *Orthopedics*. 2015 Feb 1;38(2):87-93. Epub 2015/02/11.
79. Hillmann A, Hoffmann C, Gosheger G, Rodl R, Winkelmann W, Ozaki T. Tumors of the pelvis: complications after reconstruction. *Archives of orthopaedic and trauma surgery*. 2003 Sep;123(7):340-4. Epub 2003/07/03.
80. Gradl G, de Witte PB, Evans BT, Hornicek F, Raskin K, Ring D. Surgical site infection in orthopaedic oncology. *The Journal of bone and joint surgery American volume*. 2014 Feb 5;96(3):223-30. Epub 2014/02/07.
81. Naranje S, Lendway L, Mehle S, Gioe TJ. Does operative time affect infection rate in primary total knee arthroplasty? *Clinical orthopaedics and related research*. 2015 Jan;473(1):64-9. Epub 2014/04/18.
82. Racano A, Pazonis T, Farrokhhyar F, Deheshi B, Ghert M. High infection rate outcomes in long-bone tumor surgery with endoprosthetic reconstruction in adults: a systematic review. *Clinical orthopaedics and related research*. 2013 Jun;471(6):2017-27. Epub 2013/02/14.
83. Ghert M, Deheshi B, Holt G, Randall RL, Ferguson P, Wunder J, et al. Prophylactic antibiotic regimens in tumour surgery (PARITY): protocol for a multicentre randomised controlled study. *BMJ Open*. 2012;2(6).
84. Romano CL, Scarponi S, Gallazzi E, Romano D, Drago L. Antibacterial coating of implants in orthopaedics and trauma: a classification proposal in an evolving panorama. *Journal of orthopaedic surgery and research*. 2015;10:157.
85. Gosheger G, Harges J, Ahrens H, Streitburger A, Buerger H, Erren M, et al. Silver-coated megaendoprostheses in a rabbit model--an analysis of the infection rate and toxicological side effects. *Biomaterials*. 2004 Nov;25(24):5547-56. Epub 2004/05/15.
86. Harges J, Ahrens H, Gebert C, Streitburger A, Buerger H, Erren M, et al. Lack of toxicological side-effects in silver-coated megaprostheses in humans. *Biomaterials*. 2007 Jun;28(18):2869-75. Epub 2007/03/21.
87. Wafa H, Grimer RJ, Reddy K, Jeys L, Abudu A, Carter SR, et al. Retrospective evaluation of the incidence of early periprosthetic infection with silver-treated endoprostheses in high-risk patients: case-control study. *The bone & joint journal*. 2015 Feb;97-B(2):252-7. Epub 2015/01/30.
88. Scoccianti G, Frenos F, Beltrami G, Campanacci DA, Capanna R. Levels of silver ions in body fluids and clinical results in silver-coated megaprostheses after tumour, trauma or failed arthroplasty. *Injury*. 2016 Aug 11.
89. Tsuchiya H, Shirai T, Nishida H, Murakami H, Kabata T, Yamamoto N, et al. Innovative antimicrobial coating of titanium implants with iodine. *Journal of orthopaedic science : official journal of the Japanese Orthopaedic Association*. 2012 Sep;17(5):595-604.
90. Shirai T, Tsuchiya H, Nishida H, Yamamoto N, Watanabe K, Nakase J, et al. Antimicrobial megaprostheses supported with iodine. *J Biomater Appl*. 2014 Oct;29(4):617-23.
91. Ogura K, Miyamoto S, Sakuraba M, Chuman H, Fujiwara T, Kawai A. Immediate soft-tissue reconstruction using a rectus abdominis myocutaneous flap following wide resection of malignant bone tumours of the pelvis. *The bone & joint journal*. 2014 Feb;96-b(2):270-3. Epub 2014/02/05.
92. Kroll SS, Schusterman MA, Reece GP, Miller MJ, Robb G, Evans G. Abdominal wall strength, bulging, and hernia after TRAM flap breast reconstruction. *Plastic and reconstructive surgery*. 1995 Sep;96(3):616-9.
93. Nosotti M, Cioffi U, De Simone M, Mendogni P, Palleschi A, Rosso L, et al. Omentoplasty and thoracoplasty for treating postpneumonectomy bronchopleural fistula in a patient previously submitted to aortic prosthesis implantation. *J Cardiothorac Surg*. 2009 Jul 24;4:38.
94. Yaszemski MJ. *Biomaterials in Orthopedics*: CRC Press; 2003.
95. Unni KK, Inwards CY. *Dahlin's bone tumors: general aspects and data on 10,165 cases*: Lippincott Williams & Wilkins; 2010.
96. Fletcher CDM, Unni KK, Mertens F, Organization WH, Cancer IAFRo. *WHO classification of tumours of soft tissue and bone*: IARC press; 2013.
97. Mankin HJ, Doppelt SH, Sullivan TR, Tomford WW. Osteoarticular and intercalary allograft transplantation in the management of malignant tumors of bone. *Cancer*. 1982 Aug 15;50(4):613-30. Epub 1982/08/15.
98. Donati D, Giacomini S, Gozzi E, Mercuri M. Proximal femur reconstruction by an allograft prosthesis composite. *Clinical orthopaedics and related research*. 2002 Jan(394):192-200. Epub 2002/01/25.

99. Farid Y, Lin PP, Lewis VO, Yasko AW. Endoprosthetic and allograft-prosthetic composite reconstruction of the proximal femur for bone neoplasms. *Clinical orthopaedics and related research*. 2006 Jan;442:223-9. Epub 2006/01/06.
100. Zehr RJ, Enneking WF, Scarborough MT. Allograft-prosthesis composite versus megaprosthesis in proximal femoral reconstruction. *Clinical orthopaedics and related research*. 1996 Jan(322):207-23. Epub 1996/01/01.
101. Ortiz-Cruz E, Gebhardt MC, Jennings LC, Springfield DS, Mankin HJ. The results of transplantation of intercalary allografts after resection of tumors. A long-term follow-up study. *The Journal of bone and joint surgery American volume*. 1997 Jan;79(1):97-106. Epub 1997/01/01.
102. Deijkers RL, Bloem RM, Hogendoorn PC, Verlaan JJ, Kroon HM, Taminiau AH. Hemicortical allograft reconstruction after resection of low-grade malignant bone tumours. *The Journal of bone and joint surgery British volume*. 2002 Sep;84(7):1009-14. Epub 2002/10/03.
103. Bickels J, Meller I, Henshaw RM, Malawer MM. Reconstruction of hip stability after proximal and total femur resections. *Clinical orthopaedics and related research*. 2000 Jun(375):218-30.
104. Lloyd DG, Buchanan TS. Strategies of muscular support of varus and valgus isometric loads at the human knee. *Journal of biomechanics*. 2001 Oct;34(10):1257-67. Epub 2001/08/28.
105. Kawai A, Muschler GF, Lane JM, Otis JC, Healey JH. Prosthetic knee replacement after resection of a malignant tumor of the distal part of the femur. Medium to long-term results. *The Journal of bone and joint surgery American volume*. 1998 May;80(5):636-47. Epub 1998/06/04.
106. TLEMSafe. Improving safety and predictability of complex musculoskeletal surgery using a patient-specific navigation system. [October 18, 2016]; Available from: <http://www.tlemsafe.eu/>.
107. Muscolo DL, Ayerza MA, Farfalli G, Aponte-Tinao LA. Proximal tibia osteoarticular allografts in tumor limb salvage surgery. *Clinical orthopaedics and related research*. 2010 May;468(5):1396-404. Epub 2009/12/19.
108. Albergo JJ, Gaston CL, Aponte-Tinao LA, Ayerza MA, Muscolo DL, Farfalli GL, et al. Proximal Tibia Reconstruction After Bone Tumor Resection: Are Survivorship and Outcomes of Endoprosthetic Replacement and Osteoarticular Allograft Similar? *Clinical orthopaedics and related research*. 2016 Apr 21.
109. Grimer RJ, Carter SR, Tillman RM, Sneath RS, Walker PS, Unwin PS, et al. Endoprosthetic replacement of the proximal tibia. *The Journal of bone and joint surgery British volume*. 1999 May;81(3):488-94.
110. Hobusch GM, Funovics PT, Hourscht C, Domayer SE, Puchner SE, Dominkus M, et al. LARS® band and tube for extensor mechanism reconstructions in proximal tibial modular endoprostheses after bone tumors. *The Knee*. 2016 Oct;23(5):905-10.
111. Goshager G, Hillmann A, Lindner N, Rodl R, Hoffmann C, Burger H, et al. Soft tissue reconstruction of megaprotheses using a trevira tube. *Clinical orthopaedics and related research*. 2001 Dec(393):264-71. Epub 2002/01/05.
112. Harrison RJ, Jr, Thacker MM, Pitcher JD, Temple HT, Scully SP. Distal femur replacement is useful in complex total knee arthroplasty revisions. *Clinical orthopaedics and related research*. 2006 May;446:113-20.
113. Frisoni T, Cevolani L, Giorgini A, Dozza B, Donati DM. Factors affecting outcome of massive intercalary bone allografts in the treatment of tumours of the femur. *The Journal of bone and joint surgery British volume*. 2012 Jun;94(6):836-41. Epub 2012/05/26.
114. Hilven PH, Bayliss L, Cosker T, Dijkstra PD, Jutte PC, Lahoda LU, et al. The vascularised fibular graft for limb salvage after bone tumour surgery: a multicentre study. *The bone & joint journal*. 2015 Jun;97-b(6):853-61. Epub 2015/06/03.
115. Ritacco LE, Farfalli GL, Milano FE, Ayerza MA, Muscolo DL, Aponte-Tinao L. Three-dimensional virtual bone bank system workflow for structural bone allograft selection: a technical report. *Sarcoma*. 2013;2013:524395. Epub 2013/05/22.
116. Ritacco LE, Milano FE, Farfalli GL, Ayerza MA, Muscolo DL, Aponte-Tinao LA. Accuracy of 3-D planning and navigation in bone tumor resection. *Orthopedics*. 2013 Jul;36(7):e942-50. Epub 2013/07/05.
117. Spiegelberg BG, Sewell MD, Aston WJ, Blunn GW, Pollock R, Cannon SR, et al. The early results of joint-sparing proximal tibial replacement for primary bone tumours, using extracortical plate fixation. *The Journal of bone and joint surgery British volume*. 2009 Oct;91(10):1373-7.
118. Goshager G, Gebert C, Ahrens H, Streitbuerger A, Winkelmann W, Harges J. Endoprosthetic reconstruction in 250 patients with sarcoma. *Clinical orthopaedics and related research*. 2006 Sep;450:164-71. Epub 2006/05/13.

119. Kinkel S, Lehner B, Kleinhans JA, Jakubowitz E, Ewerbeck V, Heisel C. Medium to long-term results after reconstruction of bone defects at the knee with tumor endoprostheses. *Journal of surgical oncology*. 2010 Feb 1;101(2):166-9. Epub 2009/11/20.
120. Masri BA, Meek RM, Duncan CP. Periprosthetic fractures evaluation and treatment. *Clinical orthopaedics and related research*. 2004 Mar(420):80-95.
121. Foo LS, Harges J, Henrichs M, Ahrens H, Gosheger G, Streitburger A. Surgical difficulties encountered with use of modular endoprosthesis for limb preserving salvage of failed allograft reconstruction after malignant tumor resection. *The Journal of arthroplasty*. 2011 Aug;26(5):744-50. Epub 2010/08/10.
122. Franklin J, Malchau H. Risk factors for periprosthetic femoral fracture. *Injury*. 2007 Jun;38(6):655-60.
123. Aponte-Tinao L, Farfalli GL, Ritacco LE, Ayerza MA, Muscolo DL. Intercalary femur allografts are an acceptable alternative after tumor resection. *Clinical orthopaedics and related research*. 2012 Mar;470(3):728-34. Epub 2011/06/22.
124. Friedrich JB, Moran SL, Bishop AT, Wood CM, Shin AY. Free vascularized fibular graft salvage of complications of long-bone allograft after tumor reconstruction. *The Journal of bone and joint surgery American volume*. 2008 Jan;90(1):93-100.
125. Scarborough MT. Allograft-allograft healing? Salvage of massive allografts after fracture. *Clinical orthopaedics and related research*. 2001 Jan(382):28-33. Epub 2001/01/12.
126. Lee FY, Storer S, Hazan EJ, Gebhardt MC, Mankin HJ. Repair of bone allograft fracture using bone morphogenetic protein-2. *Clinical orthopaedics and related research*. 2002 Apr(397):119-26. Epub 2002/04/16.
127. Bus MP, van de Sande MA, Taminiau AH, Dijkstra PD. Is there still a role for osteoarticular allograft reconstruction in musculoskeletal tumour surgery? A long-term follow-up study of 38 patients and systematic review of the literature. *The bone & joint journal*. 2017 Apr;99-b(4):522-30. Epub 2017/04/06.
128. Obrebsky WT, Pappas N, Attallah-Wasif E, Tornetta P, 3rd, Bhandari M. Level of evidence in orthopaedic journals. *The Journal of bone and joint surgery American volume*. 2005 Dec;87(12):2632-8.
129. Evaniew N, Nuttall J, Farrokhyar F, Bhandari M, Ghert M. What are the levels of evidence on which we base decisions for surgical management of lower extremity bone tumors? *Clinical orthopaedics and related research*. 2014 Jan;472(1):8-15. Epub 2013/10/02.
130. Vandenbroucke JP, von Elm E, Altman DG, Gotzsche PC, Mulrow CD, Pocock SJ, et al. Strengthening the Reporting of Observational Studies in Epidemiology (STROBE): explanation and elaboration. *Epidemiology*. 2007 Nov;18(6):805-35.
131. Zimmerli W, Trampuz A, Ochsner PE. Prosthetic-joint infections. *The New England journal of medicine*. 2004 Oct 14;351(16):1645-54.
132. Enneking WF, Dunham W, Gebhardt MC, Malawar M, Pritchard DJ. A system for the functional evaluation of reconstructive procedures after surgical treatment of tumors of the musculoskeletal system. *Clinical orthopaedics and related research*. 1993 Jan(286):241-6. Epub 1993/01/01.
133. Davis AM, Wright JG, Williams JL, Bombardier C, Griffin A, Bell RS. Development of a measure of physical function for patients with bone and soft tissue sarcoma. Quality of life research : an international journal of quality of life aspects of treatment, care and rehabilitation. 1996 Oct;5(5):508-16. Epub 1996/10/01.
134. Tunn PU, Pomraenke D, Goerling U, Hohenberger P. Functional outcome after endoprosthetic limb-salvage therapy of primary bone tumours—a comparative analysis using the MSTs score, the TESS and the RNL index. *International orthopaedics*. 2008 Oct;32(5):619-25.
135. van Egmond-van Dam JC, Bekkering WP, Bramer JAM, Beishuizen A, Fiocco M, Dijkstra PDS. Functional outcome after surgery in patients with bone sarcoma around the knee; results from a long-term prospective study. *Journal of surgical oncology*. 2017 Jun;115(8):1028-32.
136. Barkun JS, Aronson JK, Feldman LS, Maddern GJ, Strasberg SM, Balliol C, et al. Evaluation and stages of surgical innovations. *Lancet*. 2009 Sep 26;374(9695):1089-96.
137. Nelissen RG, Pijls BG, Karrholm J, Malchau H, Nieuwenhuijse MJ, Valstar ER. RSA and registries: the quest for phased introduction of new implants. *The Journal of bone and joint surgery American volume*. 2011 Dec 21;93 Suppl 3:62-5.
138. Gordon-Taylor G. On malignant disease in the region of the hip-joint. *Journal of the Royal College of Surgeons of Edinburgh*. 1959 Oct;5:1-21. Epub 1959/10/01.



# Chapter 12

## **Summary in Dutch (Nederlandstalige samenvatting)**

## Nederlandstalige Samenvatting

Reconstructies voor tumorresecties in het bekken of de extremiteiten behoren tot de meest uitdagende operaties in de moderne orthopaedie. Doel van dit proefschrift was om de uitkomsten van verschillende reconstructieve technieken te evalueren, en om risicofactoren voor complicaties en minder goede uitkomsten van reconstructies te identificeren.

### Deel I – Behandeling van Tumoren van het Bekken

Het chondrosarcoom is de meest voorkomende tumor van de bekkenbotten bij volwassenen. De behandeling van dit type tumor is bijzonder uitdagend voor de orthopaedisch chirurg, aangezien er geen effectieve adjuvante behandel mogelijkheden zijn, en chondrosarcomen berucht zijn om de hoge kans op een lokaal recidief. **Hoofdstuk 2** bevat een retrospectieve analyse van 162 patiënten die werden behandeld voor een conventioneel (graad 1-3) primair centraal chondrosarcoom van het bekken, in vijf Europese centra. Achtendertig procent van onze patiënten had een lokaal recidief, 30% had metastasen. De tumorgraad, resectiemarges en maximale tumorafmeting bleken onafhankelijke voorspellers van ziekte-specifieke overleving. De meest voorkomende complicatie gedurende behandeling was een diepe infectie (19%), en het risico op een infectie bleek hoger voor patiënten die een reconstructie met een endoprothese hadden ondergaan. Onze studie was de grootste serie tot nu toe waarin specifiek patiënten met een conventioneel primair centraal chondrosarcoom van het bekken werden bestudeerd. Gezien het feit dat het tot op heden niet mogelijk is om preoperatief op betrouwbare wijze onderscheid te maken tussen laag- en hooggradige tumoren, concludeerden wij dat ieder centraal chondrosarcoom van het bekken behandeld dient te worden middels agressieve chirurgische resectie.

Periacetabulaire resecties, en de daaropvolgende reconstructies, zijn één van de meest uitdagende operaties in de oncologische orthopaedie. In **hoofdstuk 3** presenteren wij een retrospectieve evaluatie van de midden- tot langetermijnresultaten van periacetabulaire reconstructies met de ‘pedestal cup’ endoprothese. Van 2003 tot 2009 ondergingen in totaal 19 patiënten een reconstructie met dit implantaat in de twee deelnemende centra. Complicaties traden op bij 15 patiënten (79%). Drie van hen (16%) hadden recidiverende luxaties, en in drie gevallen (16%) trad er aseptische loslating op. Er werd geen mechanisch falen van het implantaat zelf geobserveerd. Infecties kwamen voor



bij negen patiënten (49%). Het implantaat diende bij zes van hen verwijderd te worden om de infectie te behandelen. De overleving van het implantaat op vijf jaar postoperatief was 50% voor alle redenen, en 61% voor niet-oncologische redenen. De gemiddelde MSTS-score op het moment van laatste evaluatie was 49% (13% tot 87%). We concludeerden dat wij dit implantaat niet langer zouden gebruiken en adviseerden terughoudendheid bij het gebruik van dit implantaat na periacetabulaire resecties.

Ondanks de teleurstellende resultaten die wij rapporteerden voor de 'pedestal cup' endoprothese, beschouwden wij het idee achter het ontwerp van het implantaat geschikt voor reconstructies van periacetabulaire defecten. Deze ervaringen werden verwerkt in het ontwerp van de LUMiC prothese. **Hoofdstuk 4** beschrijft de resultaten van een retrospectieve studie in meerdere Europese centra, waarin 47 patiënten werden geïnccludeerd. Het doel van deze studie was om de resultaten van periacetabulaire reconstructie met deze prothese op de korte- tot middellange termijn te analyseren. Wij toonden aan dat het risico op luxatie significant lager was in reconstructies met een 'dual-mobility' cup (HR 0.11; dat wil zeggen een reductie van 89% in het risico op een luxatie in het voordeel van de 'dual-mobility' cup). Aseptische loslating trad op in twee reconstructies met een ongecementeerde steel waarbij de primaire fixatie suboptimaal was; beide werden gereviseerd. Infecties traden op in 28% van de reconstructies. We toonden aan dat de duur van de operatie en de hoeveelheid bloedverlies geassocieerd zijn met het risico op infectie. De cumulatieve incidenties van falen van het implantaat op 2 en 5 jaar waren 2.1% en 17.3% voor mechanische redenen, en 6.4% en 9.2% voor infectie, respectievelijk. De gemiddelde MSTS-score op het moment van laatste analyse was 70% (30% tot 93%). We concludeerden dat de LUMiC bij reconstructies van grote tumordefecten in het bekken op de korte termijn een laag risico op mechanische complicaties en falen vertoont. Daarnaast stelden wij dat 'dual-mobility' cups na iedere interne hemipelvectomy gebruikt dienen te worden om het risico op luxaties te verminderen.

## Deel II – Behandeling van Tumoren van de Extremititeiten

Intercalaire allografts zijn lang de voornaamste reconstructieve techniek geweest voor de reconstructie van grote segmentale (diaphysaire) defecten. **Hoofdstuk 5** beschrijft een retrospectieve evaluatie van alle intercalaire allograftreconstructies die verricht werden in de behandeling van een primaire bottumor in de vier centra voor oncologische orthopaedie in Nederland, tussen 1989 en 2009. De incidentie



van, en risicofactoren voor, falen en complicaties, tijd tot volledige belasting, en optimale fixatie werden geëvalueerd bij 87 reconstructies. Complicaties werden gezien bij 76% van de patiënten. De voornaamste complicaties waren 'nonunion' (40%), fracturen (29%), en infectie (14%). De mediane tijd tot volledige belasting was negen maanden. Vijftien grafts faalden, waarvan twaalf in de eerste vier jaren na operatie. Geen van de reconstructies van de tibia faalden. Locatie van de reconstructie, leeftijd van de patiënt, lengte van de allograft, fixatie met een intramedullaire pen alleen, en niet-overbruggende osteosynthese bleken de belangrijkste risicofactoren voor complicaties. Om het aantal complicaties te verminderen, raadden wij aan om het gebruik van allografts voor reconstructie van grote defecten te heroverwegen, met name bij de oudere patiënt, en om plaatosteosynthese te verrichten.

Het is voorgesteld dat primaire bottumoren adequaat behandeld zouden kunnen worden middels een hemicortical resectie. Potentiële voordelen van een hemicorticale resectie zijn het behoud van aangrenzende gewrichten, botmassa, en corticale continuïteit. In **hoofdstuk 6** hebben wij alle hemicorticale resecties en daaropvolgende allograftreconstructies geëvalueerd in een nationale retrospectieve studie. Er werden in totaal 111 patiënten geanalyseerd, waarbij wij keken naar het optreden van mechanische complicaties, infecties, oncologische uitkomsten, en overleving van de allograft. Drieëndertig procent van de patiënten had een niet-oncologische complicatie, met name fracturen van het gastheerbot (18%). Andere complicaties waren 'nonunion' (7%), infectie (7%), en een fractuur van de allograft zelf (3%). Van de 97 patiënten met een maligne tumor had 15% een residu of recidief tumor, en 6% kreeg metastasen. Het risico op complicaties en fracturen nam toe met de uitgebreidheid van de corticale resectie. Wij concludeerden dat hemicorticale resectie niet aan valt te bevelen voor hooggradige tumoren. Daarentegen kan het superieur zijn aan een segmentresectie bij zorgvuldig geselecteerde tumoren, op voorwaarde dat adequate marges behaald kunnen worden.

Osteoarticulaire allografts werden in het Leids Universitair Medisch Centrum frequent gebruikt voor de reconstructie van articulaire defecten na tumorresectie sinds die oprichting van de Leidse Botbank, in december 1988. Solide bewijs omtrent de langetermijn uitkomsten van dergelijke reconstructies was echter niet voorhanden. In **hoofdstuk 7** presenteerden wij een systematisch literatuuronderzoek naar osteoarticulaire allograftreconstructies, verricht in de behandeling van tumoren van het steun- en bewegingsapparaat. Daarnaast

evalueerden wij onze ervaringen met deze reconstructieve techniek in ons eigen centrum. Er werden 31 studies geïnccludeerd in het literatuuronderzoek. In totaal werden daarin 514 segmentreconstructies geanalyseerd. Met reconstructies van het distale femur als de referentiecategorie, toonden wij aan dat falen van de reconstructies minder vaak optrad in reconstructies van de distale radius (OR 0.3). Fracturen kwamen vaker voor in reconstructies van de proximale tibia (OR 2.2) en juist minder vaak in de distale radius (OR 0.1). In ons retrospectieve onderzoek werden 38 patiënten geïnccludeerd. Met allograft-gerelateerd falen als uitkomstmaat, was de overleving van de allografts op twee, vijf en tien jaar 91%, 54% en 42%. We concludeerden dat osteoarticulaire allografts geassocieerd zijn met een onacceptabel hoog risico op complicaties wanneer zij gebruikt worden voor reconstructies van grote gewrichten, en waarschuwden anderen tegen het routinematig gebruiken van segmentale osteoarticulaire allografts voor reconstructies van grote gewrichten.

In onze studies naar allograftreconstructies werd 'nonunion' (niet vastgroeien van de allograft aan het gastheerbot) als één van de voornaamste complicaties en faalmechanismen geïdentificeerd. In **hoofdstuk 8** presenteerden wij een analyse naar de risicofactoren voor 'nonunion' van allograft-gastheerovertgangen. Daartoe keken wij op twee orthogonale opnamen naar de mate van corticaal contact bij 96 transversale osteotomieën die gefixeerd waren met een plaat. We introduceerden een nieuw classificatiesysteem, waarin we de mate van corticaal contact in vier groepen opdeelden: graad 1 (volledig contact over de volledige lengte van de osteotomie), 2A ( $\geq 50\%$  contact), 2B ( $< 50\%$  contact) en 3 (in het geheel geen corticaal contact). We vonden dat alle graad 1 osteotomieën vastgroeiden. Het risico op 'nonunion' was 7% voor graad 2A, 18% voor graad 2B, en 50% voor graad 3 overgangen. Locatie van de reconstructie, leeftijd van de patiënt ( $> 16$  jaar oud), lokalisatie in het bot, of het gebruik van chemotherapie leek geen significante invloed op het risico op 'nonunion' te hebben. We concludeerden dat, alhoewel toekomstige studies onze bevinden zullen moeten bevestigen, aandacht geschonken dient te worden aan het verkrijgen van stevig contact over de overgang om het risico op 'nonunion' te verminderen of zelfs te doen verdwijnen.

Modulaire endoprothesen hebben allografts in de klinische praktijk grotendeels vervangen als de techniek van keuze voor reconstructie van gewrichten na tumorresectie. In **hoofdstuk 9** rapporteren wij de lange-termijn resultaten van reconstructies van de knie met MUTARS modulaire endoprothesen, vanuit twee Nederlandse centra. In totaal werden 110 opeenvolgende reconstructies, die



minimaal vijf jaar tevoren waren verricht, geëvalueerd. Negenentachtig implantaten (81%) waren reconstructies van het distale femur (78 ongecementeerd [87%], waarvan 42 met een hydroxyapatiet coating [54%]), 21 waren reconstructies van de proximale tibia. Zesentwintig van de reconstructies werden voorafgegaan door een gefaalde andersoortige reconstructie. Complicaties van weke delen en instabiliteit traden op bij 6%. Loslating werd waargenomen bij 28% van de implantaten die gebruikt werden als revisie van een gefaalde voorgaande reconstructie, en bij 12% van de primaire reconstructies (HR 1.87). Ongecementeerde reconstructies van het distale femur met een hydroxyapatiet coating hadden een vijfmaal lager risico op loslating dan die zonder hydroxyapatiet coating (HR 0.21). Structurele complicaties traden op bij 15 reconstructies (14%), infecties bij 14 reconstructies (13%). Met falen voor een mechanische reden als het eindpunt, waren de cumulatieve incidenties van implantaatfalen op 5, 10 en 15 jaar 16.9%, 20.7% en 37.9%, respectievelijk. We concludeerden dat MUTARS modulaire endoprothesen een betrouwbare opties vormen op de lange termijn wanneer zij gebruikt worden voor reconstructie van de knie na tumorresectie, en raadden aan om ongecementeerde implantaten te gebruiken met een hydroxyapatiet coating.





# Appendices

## List of Publications

Intercalary allograft reconstructions following resection of primary bone tumors: a nationwide multicenter study. *The Journal of Bone & Joint Surgery* 2014;96:e26(1-11). **MPA Bus**, PDS Dijkstra, MAJ van de Sande, AHM Taminiau, HWB Schreuder, PC Jutte, ICM van der Geest, GR Schaap, JAM Bramer.

Clinical outcome of pedestal cup endoprosthetic reconstruction after resection of a peri-acetabular tumour. *Bone & Joint Journal* 2014;96-B:1706–12. **MPA Bus**, EJ Boerhout, JAM Bramer, PDS Dijkstra.

Hemicortical resection and inlay allograft reconstruction for primary bone tumors: a retrospective evaluation in the Netherlands and review of literature. *The Journal of Bone & Joint Surgery* 2015;97:738-50. **MPA Bus**, JAM Bramer, GR Schaap, HWB Schreuder, PC Jutte, ICM van der Geest, MAJ van de Sande, PDS Dijkstra.

What are the long-term results of MUTARS® modular endoprostheses for reconstruction of tumor resection of the distal femur and proximal tibia? *Clinical Orthopaedics & Related Research* DOI 10.1007/s11999-015-4644-8. **MPA Bus**, MAJ van de Sande, M Fiocco, GR Schaap, JAM Bramer, PDS Dijkstra.

LUMiC® endoprosthetic reconstruction after periacetabular tumor resection: short-term results. *Clinical Orthopaedics & Related Research* DOI 10.1007/s11999-016-4805-4. **MPA Bus**, A Szafranski, S Sellevold, T Goryn, PC Jutte, JAM Bramer, M Fiocco, A Streitbürger, D Kotrych, MAJ van de Sande, PDS Dijkstra.

Osteoarticular allograft reconstructions in musculoskeletal tumor surgery: is there still a role? A long-term follow-up study of 38 patients and systematic review of the literature. *Bone & Joint Journal* 2017;99-B:522–30. **MPA Bus**, MAJ van de Sande, AHM Taminiau, PDS Dijkstra.

Conventional primary central chondrosarcoma of pelvic bone: prognostic factors and outcome of surgical treatment in 162 patients. *Accepted for publication, The Journal of Bone & Joint Surgery*. **MPA Bus**, DA Campanacci, JI Albergo, A Leithner, MAJ van de Sande, LC Gaston, G Caff, J Mettelsiefen, R Capanna, PU Tunn, LM Jeys, PDS Dijkstra.



Factors affecting nonunion of intercalary allograft-host junctions: a novel classification system for allograft union prognosis. *Submitted*. **MPA Bus**, JI Albergo, MAJ van de Sande, LE Ritacco, LA Aponte-Tinao, PDS Dijkstra.

Knee-sparing reconstruction of the distal femur using 3D-printed endoprostheses: a novel strategy in limb-salvage surgery. *Submitted*. PTJ Sanders, **MPA Bus**, MAJ van de Sande, PDS Dijkstra.

Reliability of classification for post-traumatic ankle osteoarthritis. *Knee Surgery, Sports Traumatology, Arthroscopy* 2016 Apr;24(4):1332-7. FM Claessen, DT Meijer, MP van den Bekerom, BD Gevers Deynoot, WH Mallee, JN Doornberg, CN van Dijk, Ankle Platform Study Collaborative: Science of Variation Group (lid studiegroep: **MPA Bus**)



## Acknowledgements (dankwoord)

Prof dr. P.D.S. Dijkstra, hooggeleerde promotor, beste Sander. Het aantal proefschriften waarin een lofzang is gehouden over jouw bevlogen begeleiding, nimmer aflatend optimisme en innovatieve blik, blijft gestaag toenemen. Nu kan ik beamen wat door voorgaande promovendi op deze plek geschreven is. Ik heb grote waardering voor jouw innerlijke drijfveer, en ben je ontzettend dankbaar voor de kansen die je mij geboden hebt.

Prof. dr. R.G.H.H. Nelissen, hooggeleerde promotor, beste Rob. Ik heb je niet alleen leren kennen als een razendsnelle denker en enthousiast onderzoeker, maar ook als een erg benaderbaar en betrokken afdelingshoofd. Dat is bewonderenswaardig, gezien de veelzijdigheid aan werkzaamheden waar jij je mee bezig houdt. Dank voor de mogelijkheid om onder jouw regie onderzoek te mogen doen.

Dr. J.A.M. Bramer, weledelzeergeleerde copromotor, beste Jos. Bij jou maakte ik kennis met de oncologische orthopaedie. Terugkijkend zie ik wat velen over jou zullen zeggen: je beschikt over het talent om mensen van allerlei pluimages in korte tijd op hun gemak te stellen, door een combinatie van humor, empathisch vermogen, en door de klok immer uit het oog te verliezen. Ik ben blij dat je ook bij de afronding van mijn proefschrift betrokken bent.

Dr. M.A.J. van de Sande, beste Michiel. Ook jou ben ik veel dank verschuldigd: jouw commentaar liet nooit lang op zich wachten en, afgezien van de inhoudelijk zinvolle kritieken, nam jij ook altijd de moeite om tekstueel je superioriteit te tonen. Ik heb waardering voor de wijze waarop je mensen om je heen op uitdagende wijze verder weet te helpen.

Overige leden van de DOTS: door commentaren uit het hele land werden mijn stukken veel beter, dat heb ik erg gewaardeerd.

Dear co-authors: thank you for your willingness to participate in our international studies, I greatly appreciate it.

Collega-onderzoekers, assistenten en staf van de afdeling orthopaedie van het LUMC. Ik heb jullie leren kennen als een open en benaderbare groep. Jullie boden het juiste klimaat om mij te ontwikkelen als onderzoeker. Uiteraard kan ik Team Onco hier niet ongenoemd laten. Wat zou de EMSOS zijn zonder het leger jonge honden uit Leiden?

Amices. Ik waardeer jullie vriendschappen zeer.

Viveurs, in het bijzonder Hûûs-bewoners, jaargenoten. Wij vormden met afstand het meest karaktervolle dispuut en huis van de hoofdstad. Al dat moois, we hadden het op geen enkele andere plaats kunnen ervaren.

BIS'ers! Welke vriendengroep deelt gekkere ervaringen dan wij? Daarbij doel ik uiteraard op het professionele vlak, maar kan ik "wie is de gekste?" niet vergeten. Een prachtige opstap naar een snijdende carrière, maar ook een goede basis voor levenslange vriendschappen, daar ben ik van overtuigd.

Joep en Bram, de keuze voor jullie als paranimf was snel gemaakt. Jullie luisterden altijd met veel interesse naar mijn verhalen, en soms leek het net of de interesse gemeend was. Wat kan mij nu nog gebeuren, met twee advocaten aan mijn zijde?

Lieve papa en mama. Waar ik eerder een aantal mensen bedank voor het bieden van kansen gedurende de afgelopen jaren, moet ik jullie bedanken omdat jullie dat al mijn gehele leven doen. Zonder jullie nimmer aflatende steun, advies, en duwtjes in de goede richting, was dit proefschrift er nooit geweest. Lieve Jacqueline, Sjaakie. Hoe lief en zorgzaam jij al direct na de geboorte voor mij was, weet ik alleen van de verhalen. Van de latere jaren weet ik het wel uit eigen ervaring. Ik had mij geen betere zus kunnen wensen.

Tot slot, lieve Lizz, dan ook mijn dankwoord aan jou. Het duurde even voordat ik je wist te overtuigen, maar ik ben er zeker van dat we daar nooit spijt van zullen krijgen. Ik ben zo ontzettend blij met je.



## Curriculum vitae

Michaël P.A. Bus was born in Naarden, The Netherlands, on the 11<sup>th</sup> of May, 1988. He grew up in Blaricum with his parents and older sister, Jacqueline. After graduating from secondary school (Laar & Berg, Laren NH), he started medical school at the University of Amsterdam. From 2009 onwards, he worked at BISLIFE Foundation (formerly known as Bio Implant Services, BIS) as a chief retrieval technician for post-mortem tissue donation, leading the explantation procedures for bones and tendons, heart valves, and corneas. This provoked his interest in reconstructive surgical procedures with the use of allogeneic tissues. He undertook his first research project on allograft reconstructions in orthopaedic oncology under supervision of dr. J.A.M. Bramer at the Academic Medical Center (Amsterdam).

Later, he started a formal PhD program on reconstructive techniques in musculoskeletal tumor surgery at the Leiden University Medical Center, under supervision of prof. dr. P.D.S. Dijkstra and prof. dr. R.G.H.H. Nelissen. He conducted several clinical studies in close collaboration with internationally renowned centers for orthopaedic oncology. During the years that followed, he was offered the chance to follow additional academic courses, he published various scientific papers in internationally acclaimed peer reviewed journals, and presented his research on numerous international meetings.

After finishing the majority of the work that is being presented in this PhD-thesis, he started his medical internships. He undertook elective internships in orthopaedic surgery at the Beit CURE International Hospital (Blantyre, Malawi) and the Academic Medical Center (Amsterdam), and did a senior internship in orthopaedics at the Haga hospital (The Hague). After completion of his internships, he started working at the Alrijne Hospital (Leiderdorp) as a resident in general surgery. In the future, he will pursue a further career in orthopaedic surgery.

















